

TOPICAL REVIEW

Endoscopic treatment of praecancerous colorectal lesions and early colorectal cancer

Mlkvy P¹, Majek J², Jurgos L³, Makovnik P¹, Durdik S⁴*Institute of Laboratory Medicine, St. Elizabeth University College of Health and Social Work, and St. Elizabeth Cancer Institute, Bratislava, Slovakia. pmlkvy@ousa.sk*

Abstract: Endoscopic mucosal resection or piece meal polypectomy are the methods of choice for the treatment of unifocal visualized lesion. Thermal ablative techniques are indicated for flat adenomas as a adjunct therapy after an imcomplete EMR or piece meal polypectomy. Photodynamic therapy using ALA photosensitisation is effective in the treatment of multifocal lesions and also in combination with EMR or thermal ablative techniques. At present, the “tailored suite” combination of these techniques for each patient, according to the character of the lesions, is considered to be the most effective treatment of precancerous lesions and early colorectal cancer (Tab. 1, Fig. 2, Ref. 16). Full Text (Free, PDF) www.bmj.sk.

Key words: resection, ablation, combination techniques.

Worldwide, colorectal cancer has doubled its incidence within last 30 years. With the incidence 58/100 000 inhabitants it is currently the second most common cancer in Slovakia (1). The approved screening methods, like FOBT, fecal DNA, double contrast barium enema (irrigography), rectosigmoidoscopy, pancolonoscopy or CT colonoscopy are helpful in detection of early colorectal neoplasia or their precancerous lesions. Sporadic adenomatous polyps (either with stalk or broad based) represent more than 90 % of all benign colorectal lesions. Histologically, adenomas are divided into the three categories: more than 50 % are tubulovillous, 35 % tubulovillous and 15 % villous (2). Adenomatous polyps possess a classic malignant potential, known as “Adenoma cancer sequence”. There are numerous retrospective studies analyzing colorectal adenomas. In the “Leeds study”, adenomas were divided according to the type of lesion. Authors have observed the highest malignant potential in polypoid lesions (63 %), followed by flat (34 %) and ulceroid lesions (3 %). In polyps larger than 10 mm, early cancer was observed more often in flat adenomas (24 %) than in polypoid adenomas with stalk (16 %). The highest malignant potential was observed in rare ulceroid lesions (in 5 from only 7 patients, but with the 71 % risk of malignancy) (3).

¹Institute of Laboratory Medicine, St. Elizabeth University College of Health and Social Work and St. Elizabeth Cancer Institute, Bratislava, Slovakia, ²3rd Department of Internal Medicine Faculty of Medicine Comenius University, Bratislava, Slovakia, ³Nacional Cancer Institute, Bratislava, Slovakia, and ⁴Department of Oncological Surgery Faculty of Medicine, Comenius University, Bratislava and St. Elizabeth Cancer Institute, Bratislava, Slovakia

Address for correspondence: P. Mlkvy, MD, PhD, Institute of Laboratory Medicine, St. Elizabeth University College of Health and Social Work and St. Elizabeth Cancer Institute, Heydukova 10, SK-812 50 Bratislava, Slovakia.
Phone: +421.2.59249295

Other polypoid lesions like hamartomas have only minimal malignant potential. Hyperplastic polyps are considered to be benign. On the other hand, the risk for malignancy is extremely high in some genetic diseases, in autosomal Familial Adenomatous Polyposis it is as high as 100 %, in Hereditary Nonpolyposis Colorectal Cancer syndrome (HNPCC) close to 80 %, in Juvenile Polyposis Coli in the range from 20 to 60 % and in the Peutz-Jeghers syndrome it is close to 40 %.

Furthermore, the risk for colorectal cancer carries patients with chronic nonspecific inflammatory bowel diseases (IBD) represented with ulcerative colitis and Crohn’s disease, if lasting several years (or decades). Then we can observe numerous inflammatory pseudopolypoid formations often hiding dysplastic or cancerous foci, which are considered to be at high risk for developing colorectal cancer (4).

Tab. 1. Possibilities of endoscopic therapy for early colorectal tumours.

- A. Thermal methods: 1) Endoscopic polypectomy – en bloc, piece meal
2) Endoscopic resection – ER – lift and cut method
– piece meal
– using endo knife
3) Transanal endoscopic microsurgery (TEM)
– surgical domain
4) Argon plasma coagulation – APC
5) Thermal lasers – Nd YAG, KTP
6) Monopolar (hot biopsy),
Bipolar electrocoagulation
- B. Non thermal methods – Photodynamic therapy (PDT) using sensitizers:
– delta aminolaevulinic acid (5 – ALA)
– Photofrin
– MTHPc (Foscan)
- C. Chemical methods – injection of ethanol (commonly used)
- D. Combination of these techniques (3)

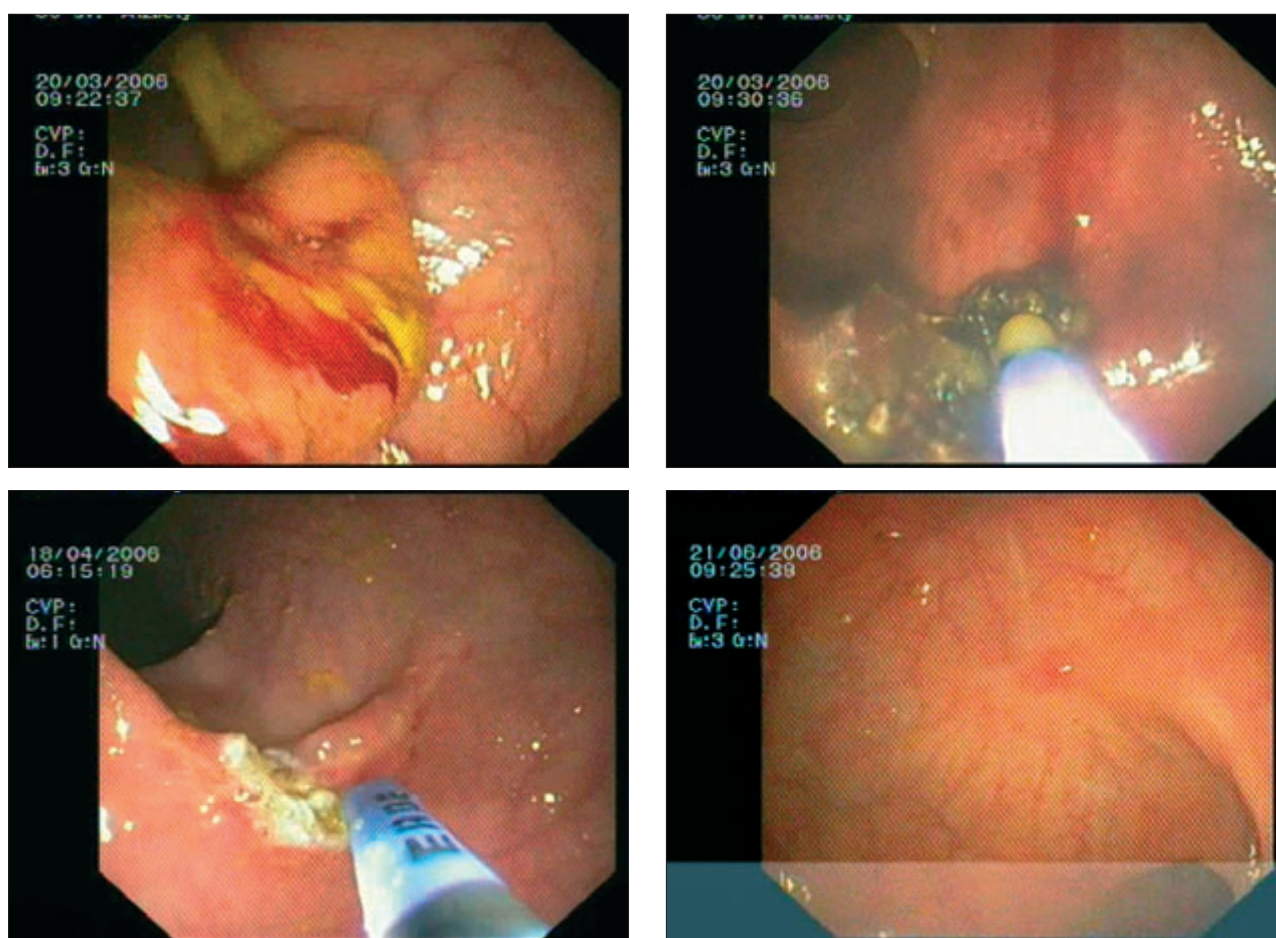


Fig. 1. APC destruction therapy of rectal broad based dysplastic adenoma.

When considering the endoscopic therapy for early colorectal neoplasia we have to weight low risk and high risk indications for this treatment. Colorectal lesions with „low risk criteria“ are limited to mucosa, with no lymphnode involvement, elevated (I) or flat (IIa or IIb) types, with the size up to 20 mm and with differentiated histological grading G1 or G2. In opposite, lesions with “high risk criteria” are lesions with submucosal invasion, ulcerated (IIc or III) types, larger than 30 mm and with low differentiation or dedifferentiation grading (G3, G4) (5).

Submucosal invasion plays the key role in the effectiveness of endoscopy therapy. From endoscopical point of view, dysplastic lesions, tumours Tis (i.e. intramucosal cancers) and cancers in stage T1a (with no muscularis propria involvement) are considered to be safe for endoscopic therapy. When submucosal involvement (type T1b) is present, endoscopic treatment becomes more complicated. The invasivity of proximal third of submucosa is considered to be safe for endoscopic therapy, while submucosal involvement in its middle third has lymphatic-vascular involvement present in 30 %, and when the invasion of distal third of submucosa is present, it is up to 50 %! Alternatively, some authors define the depth of invasion, with the published safe data for endoscopy therapy reaching up to the depth of 1250 μm (6).

Tumor lesions type T2 with the involvement of muscularis propria are not suitable for the endoscopic therapy and are indicated for surgery. Endoscopic therapy, like any invasive modality, brings some risks. Its main complication is posttherapeutic bleeding present in 0.6 to 14.8 %, usually successfully managed endoscopically either with argon plasma coagulation (APC) or by endoclips. Further complication – perforation is described in 0.4 to 4.6 % and could be treated also endoscopically by placing endoclips, but surgical approach is more preferred (2).

Currently, there is a large scale of endoscopic modalities for the treatment of early colorectal cancer or praecancerous lesions. Endoscopic methods could be divided into several groups like thermal, nonthermal, chemical and combined ablative techniques (3) (Tab. 1 and Fig. 1, 2).

Classical endoscopic polypectomy is an endoscopic polypectomy performed either in bloc or in piece meal fashion (e.g cutting the polyp by parts often used in large or broad based polyps) (7).

Endoscopic mucosal resection (EMR) or endoscopic resection (ER) is performed according to the type of the lesion. Lift and cut with praetherapeutic submucosal injection into the lesions prior to therapy (most often saline 0.9 % solution or in combination with other solution) is used quite frequently. The

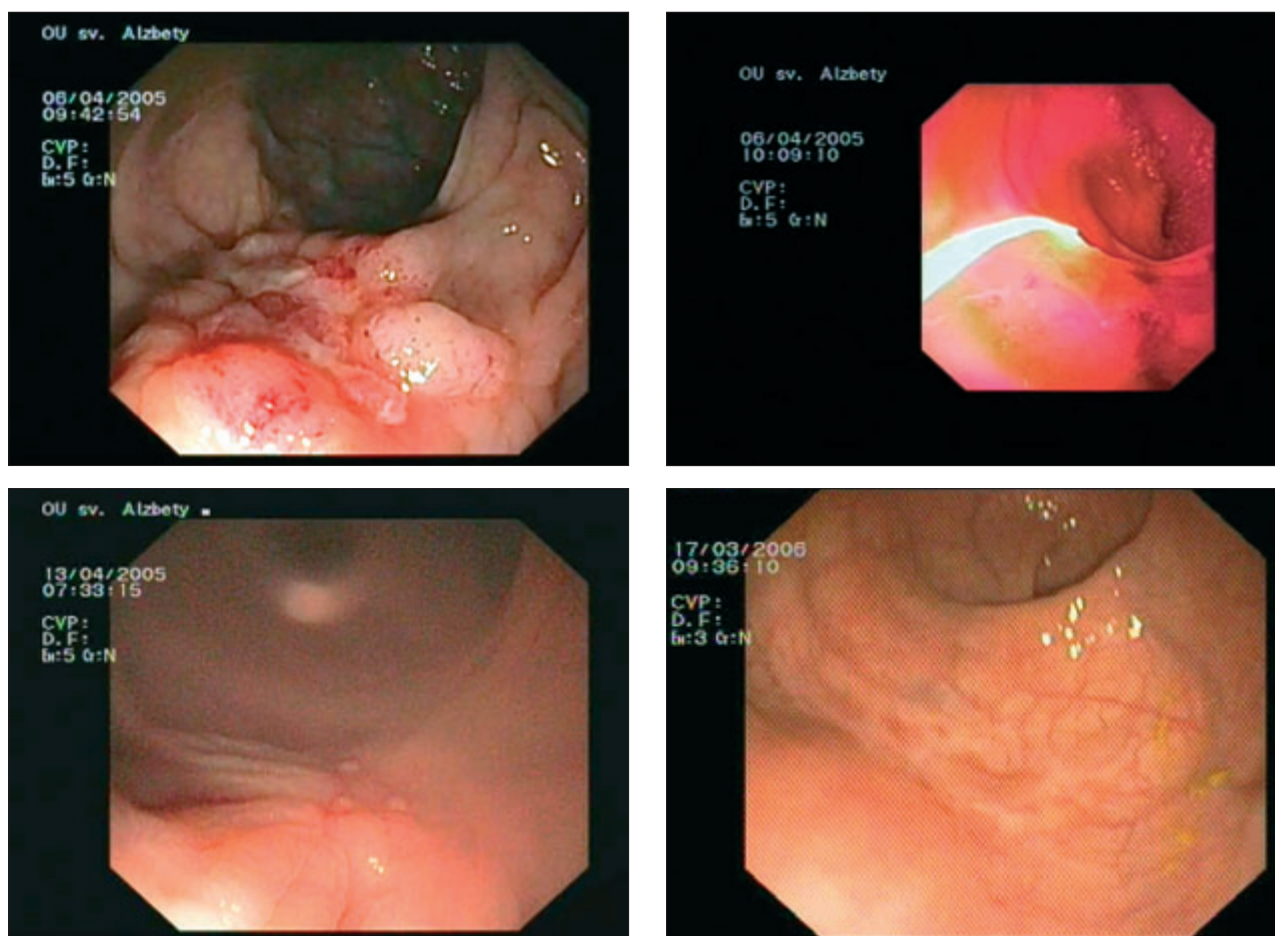


Fig. 2. The state after an incomplete polypectomy of rectal villous adenoma using one session of ALA-PDT.

principle of this technique is a submucosal injection of solutions, which separates the lesion from muscularis propria (8). Commonly used is 0.9 % saline solution, given either alone or in combinations with adrenaline. The disadvantage of the saline solution is its short effect, which is caused by quick dissolution of saline (9). Therefore, other solution like sodium hyaluronate hypertonic saline or hydroxypropylcellulose has been tried (10). The usual dose ranges from 2 up to 30 ml and is given submucosally during one procedure. A contraindication for this EMR treatment is a non appearance of lifting sign of the lesion or already present invasion of the lesion in the deeper part of the colorectal wall. After achieving the lifting sign, the lesion could be removed either with polypectomy snare and forceps (so called lift and cut method), or alternatively, using a band ligation or "triangle knife".

When the EMR technique is preferred, lesion should be up to 20 mm large with limited growth to mucosa and with the size not reaching more than 1/3 of the endoluminal circumference. Of course, all above mentioned low risk criteria should be added as well (8, 9).

Non thermal methods are mainly represented by photodynamic therapy (PDT) using the two photosensitisers, either the deltaaminolaevulinic acid (ALA) or Photofrin. Thermal meth-

ods are either monopolar or bipolar. In the bipolar technology, bipolar electrocoagulation or heat probe coagulation are usually used. Monopolar thermal methods are represented by the hot forceps biopsy and by the non contact argon plasma coagulation. Commonly used thermal methods are nowadays the bipolar coagulation and argon plasma coagulation (7).

The Nd YAG laser therapy is currently not used as often as in the last decade. The acronym Nd YAG represents the structure of crystal parts providing laser beam: neodymium-yttrium-aluminium-garnet. With the help of optic fibre, the laser beam is targeting the lesion with a usual dose of 50 to 80 W. A biological effect observed on the treated tumor tissue is dose dependent. It starts from coagulation, through carbonisation and finally end with vaporisation. When there are small endophytic or flat lesion present in rectal region, we can dare to use higher doses (up to 70–80 W), while in more proximally located lesions with ulceroid shape, located often in sharp angles in haustras of the colorectal wall, a cautious approach with using lower doses is recommended. When carefully indicated, laser treatment is effective in the range of 74–87 %. There is only one or two laser treatment sessions needed (often on outpatient basis). The ideal interval between the sessions is between 7 to 10 days.

Complications of this procedure are following: minor post-therapeutic bleeding (present in 3.5–4.5 %) and rare perforation (in 0.6–1.2 %). Transient fullness of abdomen caused by insufflated gas is the main discomfort of this therapeutic modality. Further disadvantages of laser treatment are a high price of laser equipment and a presence of technician during the procedure (11).

Argon plasma coagulation is a non contact endoscopic method. While using the monopolar wolfram electrode, an argon gas starts to ionize and to form argon plasma beam with an immediate effect on the treated biological tissue (so called argon jet). Dose dependent effects like coagulation, excision or destruction could be observed. Because of its lower depth of penetration (up to 2–3 mm) it is considered to be safer for the treatment of smaller lesions than thermal laser. On the other hand, more sessions (2–4) are usually needed. The main indication for APC are flat adenomas and adjunct therapy after an incomplete polypectomy or existing “lateral spreading” tumor at the border of former lesion (12, 13). The advantage of APC are simple operating modality, safety of treatment and lower price and handling costs compared to Nd YAG laser.

Photodynamic therapy (PDT) is based upon a cytotoxic reaction of atomic oxygen in neoplastic cells, which is created by the light of appropriate wavelength after previous administration of photosensitising drugs either orally or intravenously. Photosensitising drugs represent either porphyrins analogues (mainly hematoporphyrin-Photofrin) or intermediate products of haem metabolism (deltaaminolaevulinic acid – ALA) and also high photosensitive chlorins (represented mostly by meta-tetrahydroxyphenylchlorin mTHPc – Foscan). All of these photosensitisers have their “peak” in the red light spectrum (with the wave lengths of 630 and 650 nm, respectively). After iv administration (Fotofrin and Foscan), the maximal concentration of photosensitising drug in tumorous tissue occurs after 2 and 4 days, respectively. When ALA is administered orally (60 mg/kg of bodyweight dissolved in water or juice), the maximal concentration of this photosensitiser is present already after 5 hours (14). The laser red light is transferred through the biopsy channel of the colonoscope by a specific fiber using at the tip of it different applicators according to the characteristic appearance of the lesions (interstitial, diffuse, balloon...). PDT is a non thermal method using only 100 to 200 mW, while the total dose per treatment is in the range from 450 to 500 J. Photofrin has a deeper penetration effect (reaching up to 5 mm), its main disadvantage is the risk of skin photosensitivity lasting up to one month, a high price (approximately 200 000 Sk/per patient) and no possibility of repeated treatment. ALA – Levulan – has only a superficial effect (up to 2 mm), but its advantages are a low price (only 6000 Sk/per patient), a short time skin photosensitivity lasting no more than 2 days and a possibility of re-treatment if needed. A highly effective mTHPc – Foscan, because of its serious side effects has meanwhile lost its FDA approval and currently is used in palliative indications for head and neck tumors (15).

Endoscopic mucosal resection or piece meal polypectomy are the methods of choice for the treatment of unifocal visualized lesion. Thermal ablative techniques are indicated for flat

adenomas as an adjunct therapy after an incomplete EMR or piece meal polypectomy. Photodynamic therapy using ALA photosensitisation is effective in multifocal lesions and also in combination with EMR or thermal ablative techniques. One day hospitalisation after an endoscopic therapy is sometimes needed. Endoscopic controls in 3 and 6 months intervals, further yearly for the first three years, then following 3 and 5 years. Endorectal ultrasonography or MRI and the levels of oncomarkers (CEA, CA 19-9) are recommended as a part of follow up procedures. At present, a “tailored suite” combination of these techniques for each patient, according to the character of the lesions, is considered to be the most effective in the treatment of precancerous lesions and early colorectal cancer.

References

1. Pleško I, Obšitníková A. Incidencia zhubných nádorov v Slovenskej republike v roku 1999 Národný onkologický register, 2002: 37.
2. Piedbois P, Buyse M. Recent meta-analysis in colorectal cancer. *Curr Opin Oncol* 2000; 12: 362–367.
3. Skibber JM, Minsky PM et al. Cancer of the Colon. 1216–1270. In: *Cancer: Principle and Practice in Oncology*. New York — London, Lippincott, Williams 2000.
4. Tamura I. *Digestive Endoscopy* 2003; 15: 39–43.
5. Deinlein P. *Der Pathologe* 2003; 24 (5): 397–399.
6. Dancygier H, Lightdale C. *Endosonography in gastroenterology*. Stuttgart, Thieme 1998, 248–251.
7. Dítě P, Špičák J et al. *Nové trendy v digestivní endoskopické diagnostice a léčbě*. Praha: Grada Publishing 2000, 283–287.
8. Rembacken BD, Gotoda T, Fuji Z. *Endoscopic mucosal resection*. *Endoscopy* 2003; 33: 709–718.
9. Sakai P, Filho FM et al. An endoscopic technique for resection of small gastrointestinal carcinomas. *Gastroint Endosc* 1996; 44: 65–68.
10. Feltoza AB, Gostout CJ et al. Hydroxypropylmethylcellulose: A better submucosal cushion for endoscopic mucosal resection. *Gastroint endoscopy* 2003; 47: 41–47.
11. Mlkvy P, Makovník P, Májek J et al. Laserová a fotodynamická liečba kolorektálneho karcinómu. Abstrakt III, VDOG, 2002.
12. Farrin G, Grund KE. Technology of argon plasma coagulation with particular regard to endoscopic applications. *Endoscop Surg Allied Technol* 1994; 2 (1): 71–77.
13. Ginsberg GG et al. The argon plasma coagulation: technology status evaluation report. *Gastroint Endoscopy* 2002; 55 (7): 807–810.
14. Bown SG, Lovat JB. The biology of photodynamic therapy in the gastrointestinal tract. *Gastrointest Endosc Clin North Amer* 2000; 20: 533–550.
15. Mlkvy P, Messmann H, Regula J et al. Photodynamic therapy for gastrointestinal tumours using three sensitizers: ALA induced PPI, Photofrin and mTHPc – A Pilot Study. *Neoplasma* 1998; 45 (3): 157–161.
16. Schollmerich JW, Schmigel H. *Leitfaden kolorektales Karzinoms*. Uni med. Bremen—London—Boston, 2000, 147–167.

Received September 7, 2009.

Accepted November 2, 2009.