

CLINICAL STUDY

Radionavigated detection of sentinel nodes in breast carcinoma – first experiences of our department

Duchaj B^{1,2}, Chvalny P³, Vesely J², Makaiova I², Durdik S³, Straka, V³, Palaj, J³, Procka V²
Aksamitova K², Skraskova S², Banki P², Kovacova S², Galbavy S^{1,4}

St. Elisabeth University College of Health and Social Sciences, Bratislava, Slovak Republic and St. Elisabeth Cancer Institute, Bratislava, Slovakia. bduchaj@gmail.com

Abstract: *Introduction:* Biopsy and histological evaluation of sentinel lymphatic node limits the axillary node dissection only in cases of positive histological finding and decreases the occurrence of postoperative complications related to the axillary node dissection.

Methods: We used radiotracer SentiScint, Medi-Radiopharma Ltd, Hungary and preoperatively administered blue dye – Blue Patenté V, Guebert, Aulnay-Sous-Bios, France. 11 (18 %) patients were subdued to deep peritumorous application of radiotracer, 10 (16.4 %) to sub/intradermal application over the lesions and n 40 (65.6 %) patients the application was sub/intradermal and periareolar. The patients underwent an operation protocol of corresponding quadrantectomy, radionavigated blue-dye sentinel node biopsy and axillary dissection.

Results and conclusions: From May 2006 to June 2008, we examined 61 patients with breast carcinoma. They underwent radionavigated and blue-dye sentinel node biopsy. We detected 57 (93.4 %) sentinel nodes with preoperative scintigraphy, of which only 51 (83.6 %) were detected preoperatively and underwent histological evaluation. In six (9.8 %) cases, the “frozen cut” histology of the primary lesion had shown a benign lesion; hence no sentinel node biopsy or axillary dissection was performed. 12 (19.7 %) of 51 histologically evaluated sentinel nodes had metastatic invasion. We retrospectively compared the histological fund in sentinel and axillary nodes in patients with metastatic sentinel nodes. In 6 (16.6 %) cases, the sentinel node was positive of metastatic invasion but axillary nodes were histologically negative, in 6 (16.6 %) cases the sentinel node and axillary nodes were positive for metastatic invasion. We observed falsely negative findings in 3 (8.3 %) patients with negative histological fund in the sentinel node, but positive axillary nodes (*Tab. 3, Fig. 2, Ref. 11*). Full Text (Free, PDF) www.bmj.sk.

Key words: sentinel node, radiotracer, Blue Dye, radionavigated, biopsy.

The metastatic involvement of axillary lymphatic nodes in breast carcinoma is an important predictive impact factor for the oncological patient. The likelihood of metastatic invasion into axillary nodes in breast cancer is 7.6% in carcinoma in situ, 12.8 % for T1a, 23.5 % for T1b, 29.8 % for T1c, 46.7 % for T2 – and in stage T3 92.3 % (1). Therefore, in order to obtain the precise staging of the disease a diagnostic axillary node dissection has to be performed by the surgeon for further histological evaluation of lymphatic nodes.

Biopsy and histological evaluation of sentinel lymphatic node (SLN) limits the axillary node dissection only in patients with a positive histological finding, i.e. excluding those with a negative histological finding in the sentinel lymphatic node (2).

¹St. Elisabeth University College of Health and Social Sciences, Bratislava, Slovak Republic and St. Elisabeth Cancer Institute, Bratislava, Slovakia, ²Department of Nuclear Medicine, St. Elisabeth Cancer Institute, Bratislava, Slovakia, ³Department of Oncological Surgery Faculty of Medicine, Comenius University, Bratislava and St. Elisabeth Cancer Institute, Bratislava, Slovakia, and ⁴Institute of Forensic Medicine, Faculty of Medicine, Comenius University, Bratislava, Slovakia

Address for correspondence: B. Duchaj, St. Elisabeth University College of Health and Social Sciences, Bratislava, Slovakia and St. Elisabeth Cancer Institute, Heydukova 10, SK-812 50 Bratislava, Slovakia.

Phone: +421.2.59249129

Acknowledgement: I would like to thank Ramer Karen for his technical help and advice.

The sentinel lymphatic node is defined as the first lymphatic node that drains the lymphatic fluid from the primary tumor lesion (3). Histological evaluation of SLN during the operation procedure informs the surgeon about the extent and staging of the oncological disease without the necessity to perform the diagnostic axillary node dissection and thus decreases the probability of well-known postoperative complications. These include acute or chronic lymphedema, paresthesia on the inner side of arm and thorax, “postmastectomy pain syndrome”, seroma, etc. (4). In case of negative histological SLN evaluation, it is possible to abandon the axillary node dissection and thus to improve the quality of life of the patient.

Preoperative and perioperative detection of SLN can be achieved with patent blue or colloidal particles labelled with a radioactive element or by combining both techniques.

At our department we use the sentinel node detection technique also in other oncological diseases e.g. in malignant melanoma or mucosal tumors of oral cavity.

Methods

Radiopharmaceuticals

The detection of SLN in nuclear medicine is performed by use of colloidal particles labelled with a radioactive element,

Table 1. Distribution of 61 tumor lesions in breast quadrants.

LLQ – lower lateral quadrant, LMQ – lower medial quadrant, ULQ – upper lateral quadrant, MUQ – medial upper quadrant, bIMLUQ – border line of medial and lateral upper quadrant, bIULLQ – border line of upper and lower lateral quadrant, bIMLLQ – border line of medial and lateral lower quadrant

Tumor localization	LLQ n (%)	LMQ n (%)	ULQn (%)	MUQ n (%)	bIMLUQ n (%)	bIULLQ n (%)	bIMLLQ n (%)	Central leasions
	10 (16,4%)	1 (2%)	26 (42,6%)	3 (4,9%)	9 (14,8%)	8 (13,1%)	3 (4,9%)	1 (2%)

Table 2. Retrospectively compared histological findings in SLN and axillar nodes.

SLN+ / ANH- = metastatic invasion in SLN with negative axillar nodes, SLN+ / ANH+ = metastatic involvement in both SLN and axillar nodes, SLN- / ANH+ = negative SLN but metastatic invasion of axillar nodes, SLN- / ANH- = both SLN and axillar node without metastatic invasion.

SLN histology/ axillar nodes histology (ANH)	SLN+/ANH-	SLN+/ANH+	SLN-/ANH+	SLN-/ANH-
Number	6	6	3	21
Percentage	16,6%	16,6%	8,3%	58,3%

mainly with radioactive technetium ^{99m}Tc . These colloidal particles can be of anorganic origin (^{198}Au – colloid, ^{99m}Tc – antimony trisulfide, ^{99m}Tc – sulfur colloid, ^{99m}Tc – stannous flouride, ^{99m}Tc – rhenium sulfide) or derivates of organic compounds (nano or microcolloid of human serum albumin, HSA) (3, 5, 6).

At our department we use HSA microcolloid, SentiScint, Medi-Radiopharma Ltd., Hungary, with particles 100–600 nm in size. This lyophilised colloidal substance is used with radionuclide ^{99m}Tc (gamma – emitter, with 6 h half life, 140 keV energy).

The size of particle determines the transport speed through the lymphatic system i.e. the larger the particle the slower the lymphatic drainage and vice versa. This same rule applies for lymphatic node capture. Larger particles captured in the first lymphatic node/nodes block the transport in lymphatic nodes of higher level. Figure 1 displays scintigrams acquired in anterior oblique projection after 15 minutes of radiotracer injection: A: ^{99m}Tc -sulfid (17–22 nm), B: ^{99m}Tc –HSA nanocolloid (1–100 nm), C: ^{99m}Tc – HSA microcolloid (100–600 nm) (3). We can see that small colloidal particles are captured also in lymphatic nodes of higher level, whereas large particles are captured mainly in first lymphatic node/nodes.

Therefore, it is necessary to use colloid with particles of appropriate size so that the radiocolloid is captured predominantly in SLN and retained there until the operation procedure.

Mariani et al (3) believe that the best size of colloidal particles should be between 100 to 200 nm. This particle size should fulfil the condition of fast lymphatic drainage and long node capture.

Application technique

The accuracy of SLN detection greatly depends on the application technique and the site of radiotracer injection. The application technique has to reflect the morphology and physio-

Table 3. Number of SLN nodes detected with one or both metioned methods.

RT+/BD+= radiotracer and blue dye in SLN, RT+ / BD-= only radiotracer in SLN , RT-/BD+ = SLN without radiotracer but with blue dye

Radiotracer/Blue dye	RT+/BD+	RT+/BD-	RT-/BD+
Number	35	7	0
Percentage	83,3%	16,7%	0

logy of lymphatic system in the region of injection. At present, two extratumoral approaches of radiotracer application are used:

- Deep peritumoral intraparenchymal approach
- Intra/subdermal approach

The peritumoral application is performed by administering the radiotracer deep into the tissue of the breast in the healthy periphery of the primary lesion.

The intra/subdermal application is based on injecting the radiotracer into/under the skin of the breast. This technique reflects the fact of mutual embryologic origin of the skin and breast gland.

Equipment

The scintigraphic detection of SLN is performed by means of dual head scintillation camera Siemens Signatures Series (Siemens) or SOPHA DST (GE) with low-energy high-resolution (LEHR) collimator with an energy window for ^{99m}Tc (140 keV). Perioperative SLN detection is performed with a narrow collimated gammaprobe TECPROBE Stratec 2000.

Timing of operational procedure, blue dye and the radio-navigated SLN detection technique

We mainly follow the one-day (34 (65.5 %) cases) or two-day protocol (27/44.5 % cases) and therefore the surgical radio-navigated SLN biopsy should be scheduled leaving enough time to visualize the SLN with the method of lymphoscintigraphy in order to allow the preoperative SLN identification on the scintigraphic scans. The optimal time for radiotracer accumulation in SLN for radiocolloid with a particle size of 100–600 nm lies in the interval of 2–5 hours. This period should be taken in consideration when preparing the operational schedule. Our surgical department and the department of nuclear medicine are in the same building. This fact allows us to perform the lymphoscinti-

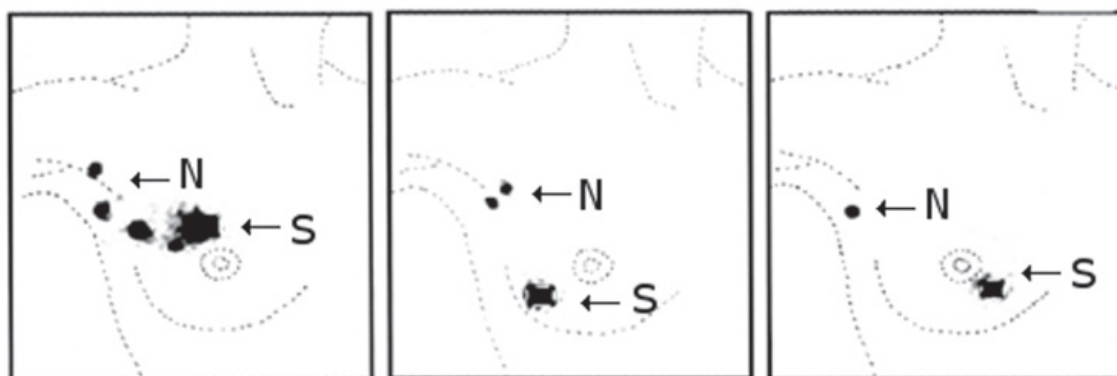


Fig. 1. S – site of injection, N – lymphatic nodes. Scintigraphic scans acquired in the anterior oblique projection after 15 minutes of radiotracer injection: A: ^{99m}Tc -sulfid (17–22 nm), B: ^{99m}Tc – HSA nanocolloid (1–100 nm), C: ^{99m}Tc – HSA microcolloid (100–600 nm). We can see that smaller colloidal particles captured also in higher-level lymphatic nodes, in comparison to larger size particles which are captured mainly in first lymphatic node/nodes (3).

graphy without any problems. The radiocolloid is administered at about 7:00–7:30 a.m. at the department of nuclear medicine and the operation takes place the same day at about 11:00–11:30 a.m.

During lymphoscintigraphy, the patient is placed under the gammadetector of the scintillation camera. He/she takes a supine position with the corresponding upper extremity placed under the head. During the first 45 minutes, sequential acquisition takes place (one frame per thirty seconds) and is followed by static acquisition (5–10 minutes) that is repeated during a period of 45–60 minutes until the sentinel node is identified.

Blue dye is administered by the surgeon 5–10 minutes before the operation begins (5 ml of diluted blue dye – Blue Patenté V, Guebert, Aulnay-Sous-Bios, France in concentration of 1ml of blue dye in 4ml of saline solution) The administration is followed by gentle massage of the region.

The perioperative radionavigated detection of SLN depends on the correct use of the perioperative gammaprobe. The gammaprobe itself is a narrow collimated gammadetector with a very small field of view. Therefore it requires a slow motion over the scanned area maintaining a right-angle to the surface and it should be as near to it as possible (7). Incorrect manipulation prolongs the tissue preparation and thus increases the perioperative stress in the patient.

Results

From May 2006 to June 2008, we examined 61 patients with breast carcinoma. All were women at an average age of 55.9 years, range of 32–78 years and median of 54. All patients were staged T1–2N0M0, of these 16 (26.2 %) had non-palpable lesions, 45 (73.7 %) had palpable lesions of size ranging from 1–2.5 cm. Patients with positive ultrasonographic finding of axillary lymphadenopathy were not chosen for radionavigated SLN biopsy.

Patients were indicated for SLN biopsy by the oncological surgeon in case of positive or suspicious cytology or core-cut biopsy. The primary tumor lesion was predominantly localized

in the left breast in 39 (63.9 %) cases while the right breast was involved in 22 (36.1 %) cases. The detailed distribution of the localization of primary tumor lesions is in Table 1. The sentinel node was detected by scintigraphy in 57 (93.4 %) cases; in 4 (6.6 %) patients we did not detect SLN by means of scintigraphy or with the help of gammaprobe.

Definitive perioperative detection and histological evaluation of SLN was performed only in 51 (83.6 %) cases because in 6 (9.8 %) patients, the histological evaluation of the “frozen cut” showed that the primary lesion was benign and in the latter cases there was no need to perform SLN detection or axillary dissection.

Owing to the implementation of this method at our department (May 2006–June 2008) in 36 (70.7 %) cases (Group A), we followed the protocol as follows: Visualization of SLN with scintigraphy at the department of nuclear medicine, quadrantectomy/lumpectomy, SLN biopsy and dissection of axillary lymph nodes. In 17 (33.3 %) patients (Group B), after the resection of primary lesion and SLN biopsy, the “frozen cut” of SLN was histologically evaluated. According to the positive histological finding 4 (19 %) patients were subjected to axillary node dissection, in the other 17 (81 %) patients, the axillary node dissection was abandoned due to negative histological finding in the “frozen cut”.

In group A (36 patients), we retrospectively compared the definitive histology of SLN and axillary lymph nodes. In 12 (19.7 %) cases, SLN was positive for metastatic invasion. More details are shown in Table 2.

The outlined column in Table 2 shows the percentage of falsely negative findings in 3 (8.3 %) cases.

In 42 (82.4 %) cases (both A and B groups) we used the combined technique, i.e. blue dye with radiotracer. The results are in Table 3.

Table 3 shows that in 35 (83.3 %) patients, SLN was radioactive and “blue” and only in 7 (16.7 %), SLN was only radioactive despite the use of blue dye. In the remaining 9 (17.7 %) cases, the blue dye was not administered and SLN detection was performed with gammaprobe only.




Fig. 2. Scintigraphic visualization of the sentinel node in a patient with non-palpable right-breast tumor lesion.

Discussion

Radionavigated SLN biopsy is considered the method of choice in early stage of breast carcinoma and malignant melanoma. Furthermore it can be used in other oncological diseases, such as tumors of head and neck, or carcinoma of the uterine neck or large intestine. It is important to mention that in spite of appropriately radical surgery, it brings real benefit to the patient in form of decreased postoperative complications related to radical and extensive regional lymphatic node dissection and thus improves the life quality after radical surgical operations.

The importance and benefit of visualization of SLN with the method of lymphoscintigraphy is also discussed because many departments perform only peroperative radionavigated SLN biopsy after radiotracer injection without acquiring the scintigraphic scans (8). The critics of lymphoscintigraphy outline the fact that it does not have a significant impact on the peroperative SLN gammaprobe detection. Furthermore, it is endorsed that negative lymphoscintigraphy does not necessarily mean that SLN is not going to be detected by the gammaprobe. This fact decreases the importance of lymphoscintigraphy in many departments (8). Gatek et al (9) are inclined to perform the preoperative lymphoscintigraphy, which helps the surgeon to localise SLN prior to surgery. We always perform lymphoscintigraphy in order to improve the surgeon's orientation during SLN biopsy as shown in Figure 2.

The main concern in sentinel node biopsy is the falsely negative finding i.e. (9) the histological finding in SLN is negative but the axillary nodes are invaded by the primary disease. This may lead to under-staging of the disease and furthermore to endangering the patient. For the optimal outcome of the procedure, it is important to consider the site and technique of the application and the use of blue dye with radiocolloid.

At present there are two main application techniques used, namely the deep peritumoral administration into the parenchyma, and superficial sub/intradermal application of radiocolloid. It is important to mention that the peritumoral technique is being slowly replaced by the sub/intradermal method (10). The accu-

racy of peritumoral application depends on the exact localisation of the primary lesion in the breast, which may be difficult in multicentric or non-palpable lesions. The radiocolloid has to be applied deep into the healthy tissue but near enough to the periphery of the tumor. The volume of radiocolloid has to be high (up to 4 ml) in 4–6 individual injection sites (3). Therefore, in many cases, the application of radiocolloid has to be done with the help of ultrasonography. The advocates of this technique outline the higher rate of intramammary lymphatic nodes visualization, which might be missed when using the sub/intradermal method because these may already be invaded by the primary disease.

The advocates of the second method point to the fact of mutual embryologic origin of the lymphatic system of the breast gland and the skin covering it (3, 6, 10, 11). The advantage of this method lies in the relative “simplicity” of application. In most cases only one injection is needed, a smaller volume of radiocolloid is administered (max 2 ml) (3, 10) and SLN is localized sooner than by the first method (10). The radiotracer can be injected sub/intradermal in the skin over the tumor or sub/intradermal periareolar into the corresponding quadrant. However, there is a disadvantage in the use of the former injection site (skin over the tumor) due to the “shine-through” effect, which can cover the SLN with emitted radiation and thereby makes the scintigraphic and perioperative identification difficult. This applies mainly for lesions located in upper quadrants. The periareolar injection site is preferable because the site of the radiotracer depot is more distant from the anticipated place of SLN detection (10).

In many cases, it is very difficult to distinguish between the subdermal and intradermal application. In general the intradermal application can be distinguished from subdermal application by the typically characteristic “skin wheel”. Thus, we can summarize that the sub/intradermal method is highly practical, requires minimal training, smaller volume of radiotracer, the visualization of SLN is faster and the node has more impulses (10).

In our group of patients, the first 11 (18 %) were subdued to peritumorous application of radiotracer, but because of the above-mentioned “disadvantages” all other patients had the radiotracer injected sub/intradermally; in 10 (16.4 %) cases the radiotracer was applied into the skin over the primary lesion and in the remaining 40 (65.5 %) into the periareolar area. We had better results using the periareolar method of scintigraphic identification when compared to perioperative gammaprobe detection.

Another important auxiliary method for radionavigated SLN biopsy is the use of blue dye (9, 10, 11). Blue dye is administered by the surgeon peritumorously and subdermally in the operational theatre 5–10 minutes before the operation procedure. Subsequently the blue dye is quickly transported via lymphatic drainage in lymphatic nodes, but because the blue dye is a low molecular compound it is captured also in nodes of higher levels and thus hinders the exact SLN identification. Sensitivity for the blue dye SLN visualization lies in range of 70–80 %; on the other hand the sensitivity for the identification of SLN by radiotracer method is in range of 80–90 % (11). The use of ra-

diotracer has some drawbacks for the surgeon. As opposed to blue dye, radioactivity cannot be seen by the human eye, and the manipulation with gammaprobe requires precision, patience and experience. An incorrect use of the gammaprobe leads to higher tissue preparation, prolongation of the operational procedure and thus stresses both the patient and the surgeon.

When combining both methods their advantages sum up. Lymphatic nodes are blue, thus distinguishable from the surrounding tissue and the gammaprobe identifies the correct radioactive SLN. It is stated that the combination of both methods increases the sensitivity up to 98% (10).

We did not compare both methods individually, but the operational procedure was more comfortable for the surgeon in case of combined method and the identification and SLN biopsy took less time than in cases with radiotracer only. The surgeon localized the SLN by following the “blue color” of the lymphatic vessels to the blue nodes and then with the help of the gammaprobe identified the SLN. In 7 (16.7 %) cases (group of combined method), the SLN was only radioactive, i.e. without “blue color” and in 9 (21.4 %) cases with radiotracer only, the SLN was identified only by gammaprobe with longer preparation and identification times.

Based on our course of experience, we can summarize that the periareolar sub/intradermal application method might be the most favorable considering the difficulty of the technique and scintigraphic and peroperative detection of SLN. With the use of the combined method (blue dye + radiotracer), the operation procedure of SLN biopsy takes less time, the tissue preparation is lower and the sensitivity of SLN identification is higher. This helps to reduce the falsely negative cases.

For the patients in early stage of breast carcinoma, the sentinel node biopsy has unquestionable advantages in decreasing the well-known postoperational complications owing to avoiding the diagnostic axillary node dissection in case of negative histological evaluation of SLN. We have to bear in mind that as with any multidisciplinary approaches, the best results are achieved only in case of good cooperation of the department of nuclear medicine and the department of surgery, and by strictly following the guidelines for radionavigated SLN biopsy.

Reference

1. **Bass SS, Dauway E, Mahatme A et al.** Lymphatic mapping with sentinel lymph node biopsy in patients with breast cancers <1 centimeter (T1A-T1B). *Amer Surg* 1999; 65: 857—861.
2. **Naik AM, Fey J, Gemignani M et al.** The risk of axillary relapse after sentinel lymph node biopsy for breast cancer is comparable with that of axillary lymph node dissection: a follow-up study of 4008 procedures. *Ann Surg* 2004; 462—468, discussion 468—471.
3. **Mariani G, Moresco L, Viale G et al.** Radioguided sentinel lymph node biopsy in breast cancer surgery. *J Nucl Med* 2001; 42: 1198—1215.
4. **Cervinka V, Stastny K, Siller J et al.** Sentinelová uzlina v praxi. *Onkologia* 2006; 1: 259—264.
5. **Chinol M, Paganelli G.** Current status of commercial colloid preparations for sentinel lymph node detection. *Eur J Nucl Med* 1999; 26: 560.
6. **Mirzaei S, Rodrigues M, Hoffmann B et al.** Sentinel lymph node detection with large human serum albumin colloid particles in breast cancer. *Eur J Nucl Med Mol Imaging* 2003; 30: 874—878.
7. **Kováčová S, Makaiová I, Knotek J et al.** Technická analýza a možnosti využitia detektor Tecprobe 2000 Stratex pre peroperačnú detekciu ¹³¹I, ¹¹¹In, ^{99m}Tc. *Lékar a technika* 1996; 27: 82—86.
8. **McMasters KM, Wong SL, Tuttle TM et al.** Preoperative lymphoscintigraphy for breast cancer does not improve the ability to identify axillary sentinel lymph nodes. *Ann Surg* 2000; 231: 724—731.
9. **Gatek J, Hnatek L, Dudsek B et al.** Sentinel lymph node biopsy in the breast carcinoma in clinical practice. *Rozhl Chir* 2008; 87: 180—185.
10. **Rodier JF, Velten M, Wilt M et al.** Prospective multicentric randomized study comparing periareolar and peritumoral injection of radiotracer and blue dye for the detection of sentinel lymph node in breast sparing procedures: FRANSENODE trial. *J Clin Oncol* 2007; 25: 3664—3669.
11. **Cserni G, Rajtar M, Boross G, Sinko M, Svebis M, Baltas B.** Comparison of vital dye-guided lymphatic mapping and dye gamma probe-guided sentinel node biopsy in breast cancer. *World J Surg* 2002; 26: 592—597.

Received September 20, 2009.

Accepted November 2, 2009.