

CASE REPORT

A two eterochronous primary gynaecological malignancies of different origin

Myriokefalitaki E, Iavazzo C, Vorgias G, Akrivos T

Department of Gynecology, Metaxa Memorial Cancer Hospital, Peiraeus, Greece.
christosiavazzo@hotmail.com

Abstract: *Aim:* The objective of our study is to present a rare case of two eterochronous primary gynaecological malignancies.

Case: A 65-year-old para-2, white obese female, presented in our department 4 years ago, due to a single event of vaginal spotting. Curettage revealed an endometrial cancer. A total abdominal hysterectomy and bilateral salpingo-oophorectomy was performed. Histology showed an endometrioid adenocarcinoma of endometrium stage Ib, moderately differentiated. No additional therapy was given. Twenty seven months later, a pathologic Papanicolaou smear came out on her routine follow-up. Although, recurrence on vaginal cuff was possible, the biopsies of anterior vaginal wall showed a poorly differentiated squamous cell carcinoma of the vagina. An exploratory laparotomy was performed, but tumor resection was not possible. The patient was classified as stage II vaginal carcinoma and underwent complete radiotherapy and chemotherapy.

Conclusion: This case indicates that female genital carcinomas of different histological origins may occur with minimal time-interval, even in the absence of known predisposing factors like previous chemo-radiotherapy, HPV infection or diethylstilbestrol exposure. The role of close follow up of hysterectomised patients should also be mentioned (*Fig. 1, Ref. 15*). Full Text (Free, PDF) www.bmj.sk.

Key words: Endometrium, vagina, malignancy, eterochronous

Endometrioid adenocarcinoma is the most common type of endometrial cancer (1). Post-menopausal, obese women are the typical patients (1). After surgery with/without additional therapy, survival rates are high (1). The most usual recurrence of the disease is presented as adenocarcinoma on vaginal cuff (2). We report a rare case of a second primary squamous carcinoma of the vagina in a patient with a history of endometrioid endometrial cancer, instead of the expected recurrence of the first disease.

Case

A 65-year-old, para-2, white, obese, female presented 4 years ago in our department due to a single event of vaginal spotting. The Papanicolaou smear showed a very high grade of maturation of cervical epithelium, non compatible to her age. She was under medication for hypertension and hypothyroidism, with no other significant medical history. Transvaginal ultrasonography showed the uterus bigger than normal and the endometrial thickness was found to be 9 mm. Heterogeneity and cystic lesions were other endometrial findings. Curettage revealed an endometrial cancer. Chest X-ray and computed tomography (CT) were negative. Abdominal CT confirmed uterus enlargement and endometrial heterogeneity. Intrapelvic lymph nodes were less than 10 mm size. Liver, kidneys and pancreas were normal. The se-

rum levels of tumor markers such as Ca 125 and Tag 72 were within normal ranges: 5.7 U/ml and 1 U/ml, respectively. A total abdominal hysterectomy and bilateral salpingo-oophorectomy was performed. Post operative recovery was optimal. Final histology showed an endometrioid adenocarcinoma of endometrium moderately differentiated with papillary architecture and superficial myometrium invasion. Peritoneal lavage was negative. By FIGO classification, it was staged as Ib and no additional therapy was given.

The patient was under close follow up. Twenty seven months later and after an uneventful period, a pathologic Papanicolaou smear occurred. Recurrence of endometrial cancer on vaginal cuff was the first thought in the differential diagnosis. Chest X-ray and CT were negative. Abdominal CT revealed an enlargement of vaginal cuff and anterior vaginal wall (*Fig. 1a, b*). Cystoscopy verified the existence of a mass pushing the posterior bladder wall without signs of invasion of its mucosa. Colonoscopy was negative of infiltration. Biopsies taken from the anterior vaginal wall showed a grade I squamous cell carcinoma of the vagina. An exploratory laparotomy was performed in order to extract the mass. Intraoperatively, after adhesiolysis, the tumor was revealed and closer exam showed that it was strongly fixed to the bladder. Resection was not possible without sacrificing the bladder, mainly by performing anterior exenteration. More biopsies were taken. Histology concluded to a squamous tumor poorly differentiated with positive PAS and CK5 and negative CK1-3 and CK5-6 reaction. After recovery, the patient underwent complete radiotherapy and chemotherapy due to vaginal

Department of Gynecology, Metaxa Memorial Cancer Hospital, Peiraeus, Greece

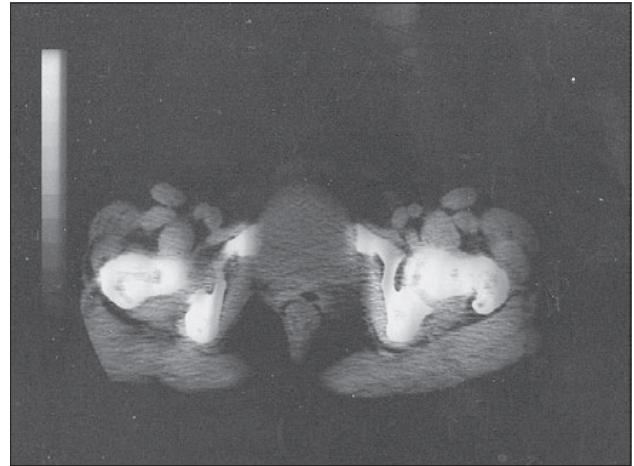
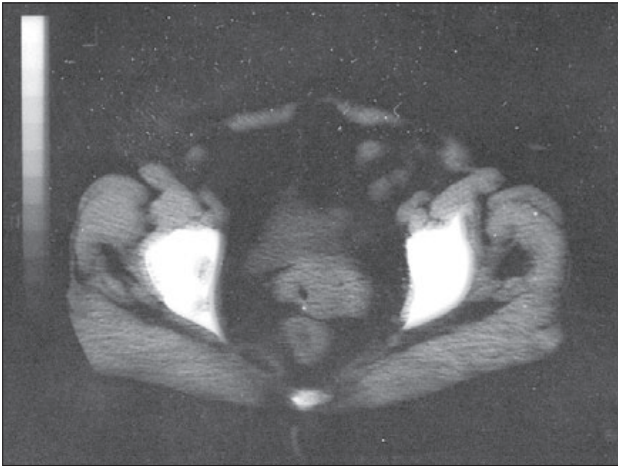


Fig. 1 a, b. Abdominal CT revealed an enlargement of vaginal cuff and anterior vaginal wall.

cancer stage II. One year later, the patient is free of disease facing problems of dysuria and constipation.

Discussion

Endometrial cancer comprises about 4 % of all cancers in women globally and occurs predominantly after the menopause (3). Family history of endometrial cancer and long lasting anovulation are associated with an increased risk of endometrial carcinoma (3), whereas high parity and late age at the last birth is considered to give long-lasting protection (4). The role of obesity as a risk factor in both premenopausal and postmenopausal women is also firmly established whereas there is limited evidence that physical activity has a protective effect. Use of combined oral contraceptives confers a long-lasting protection against endometrial cancer, particularly among long-term users (5). Estrogen only hormone replacement therapy is also an important risk factor (6). Moreover, there is a substantive evidence that smoking is protective (7). The continuing increase of obesity and decrease of fertility however forewarns that endometrial cancer will become a more important public health problem (8).

Many subsequent neoplasms can be expected after women are diagnosed with endometrial carcinoma because of their favourable survival rate and high frequency. The most common subsequent neoplasms recorded are synchronous or metachronous ovarian carcinomas and carcinomas of the small intestine, followed by renal cell carcinoma, bladder carcinoma, squamous cell skin carcinoma, connective tissue malignancies, and leukemia (9). Increased risk of connective tissue tumours and leukemia may signal a response to treatment, and an increased risk of squamous cell skin carcinoma may signal a depressed immune function (10).

The increased occurrence of second primary malignancies after women are diagnosed with an initial primary malignancy may result from: 1) intensive medical surveillance after the first diagnosis, 2) therapy-induced exposure to X-rays and antineoplastic agents, and 3) shared environmental and hereditary factors between the first and second primary malignancies (11).

Vaginal cancer is the rarest of all female genital malignancies. More than 90 % of the cases are epithelial carcinomas, from which the 25 % involves in situ lesions. Squamous carcinomas are more common as the age of the patient progresses. In the contrary, adenocarcinomas are rare but more frequently observed in younger patients (12).

Patients undergoing radiotherapy for advanced cervical or endometrial cancer bear a considerable risk of developing vaginal malignant lesions. So, radiotherapy has been considered to have a role in the pathogenesis of vaginal dysplasia. It has been shown that vaginal preneoplastic changes in women post-hysterectomy who had received radiotherapy for cervical, endometrial, and vaginal cancer represent a HPV-related nosologic entity (13).

In our case, it is strange enough that an eterochronous squamous cell vaginal carcinoma occurs in absence of family history of malignancies or other predisposition factors such as multiple primary malignancies as chemotherapy, radiotherapy, smoking, exposure to diethylstilbestrol or HPV infection (14) in a patient with a history of an endometrioid endometrial cancer.

The role of the close follow-up in our patient with Papanicolaou smears and C/T scanning regardless her age was very significant as shown in order to achieve the diagnosis of such an eterochronous tumor. However, we should consider and clarify in details if such a tumor would be a recurrence or a second primary malignancy. Such a diagnosis would give us the opportunity to offer the best treatment choice in each case (15). Explorative laparotomy is proposed to achieve total excision of the tumor with free margins, however, when this is not possible, complete radiotherapy and chemotherapy is the suggested treatment.

References

1. Di Cristofano A, Ellenson LH. Endometrial carcinoma. *Annu Rev Pathol* 2007; 2: 57–85.
2. Chu CS, Randall TC, Bandera CA, Rubin SC. Vaginal cuff recurrence of endometrial cancer treated by laparoscopic-assisted vaginal hysterectomy. *Gynecol Oncol* 2003; 88 (1): 62–65.

3. **Schindler AE.** Progestogen deficiency and endometrial cancer risk. *Maturitas*, 2009 Feb 19.
4. **Amant F, Moerman P, Neven P, Timmerman D, van Limbergen E, Vergote I.** Endometrial cancer. *Lancet* 2005; 366 (9484): 491–505.
5. **Huber JC, Bentz EK, Ott J, Tempfer CB.** Non-contraceptive benefits of oral contraceptives. *Expert Opin Pharmacother* 2008; 9 (13): 2317–2325.
6. **Yeh IT.** Postmenopausal hormone replacement therapy: endometrial and breast effects. *Adv Anat Pathol* 2007; 14 (1): 17–24.
7. **Tinelli A, Vergara D, Martignago R, Leo G, Malvasi A, Tinelli R.** Hormonal carcinogenesis and sociobiological development factors in endometrial cancer: a clinical review. *Acta Obstet Gynecol Scand* 2008; 87 (11): 1101–1113.
8. **Kwon JS, Lu KH.** Cost-effectiveness analysis of endometrial cancer prevention strategies for obese women. *Obstet Gynecol* 2008; 112 (1): 56–63.
9. **Delin JB, Miller DS, Coleman RL.** Other primary malignancies in patients with uterine corpus malignancy. *Amer J Obstet Gynecol* 2004; 190 (5): 1429–1431.
10. **Hemminki K, Aaltonen L, Li X.** Subsequent primary malignancies after endometrial carcinoma and ovarian carcinoma. *Cancer* 2003; 97 (10): 2432–2439.
11. **Bergfeldt K, Einhorn S, Rosendahl I, Hall P.** Increased risk of second primary malignancies in patients with gynaecological cancer. A Swedish record-linkage study. *Acta Oncol* 1995; 34 (6): 771–777.
12. **Creasman WT, Phillips JL, Menck HR.** The National Cancer Data Base report on cancer of the vagina. *Cancer* 1998; 83 (5): 1033–1040.
13. **Barzon L, Pizzighella S, Corti L, Mengoli C, Palu G.** Vaginal dysplastic lesions in women with hysterectomy and receiving radiotherapy are linked to high-risk human papillomavirus. *J Med Virol* 2002; 67 (3): 401–405.
14. **Hatch EE, Herbst AL, Hoover RN, Noller KL, Adam E, Kaufman RH, Palmer JR, Titus-Ernstoff L, Hyer M, Hartge P, Robboy SJ.** Incidence of squamous neoplasia of the cervix and vagina in women exposed prenatally to diethylstilbestrol (United States). *Cancer Causes Control* 2001; 12 (9): 837–845.
15. **Frank SJ, Jhingran A, Levenback C, Eifel PJ.** Definitive radiation therapy for squamous cell carcinoma of the vagina. *Int J Radiat Oncol Biol Phys* 2005; 62 (1): 138–147.

Received April 15, 2009.
Accepted August 18, 2009.