

CASE REPORT

Torsion of wandering spleen

Dirican A¹, Burak I¹, Ara C¹, Unal B¹, Ozgor D¹, Meydanli MM²

Inonu University Faculty of Medicine, Department of General Surgery, Department of General Surgery, Malatya, Turkey. adirican@inonu.edu.tr

Abstract: Wandering spleen is characterized by ectopic localization of spleen owing to the lack or weakening of the major splenic ligaments. In present study, two cases with torsion of wandering spleen were reported. The first case was a 30-year-old female who was admitted to emergency department with acute abdominal pain and vomiting. Abdominal Ultrasonography and computed tomography showed a round solid hypodense mass that was located in the left hypochondriac region of abdomen. At laparotomy, the patient was found to have torsion of a wandering spleen with complete infarction and pancreatic tail infarction. Splenectomy and distal pancreatectomy were performed. The second patient was a 19-year-old female. She was admitted to emergency department with abdominal pain. Axial computed tomography (CT) showed pelvic mass that indicated a possibility of a wandering spleen. The wandering spleen was removed with its long pedicle because of infarction. Torsion of wandering spleen must be considered in differential diagnosis of acute abdomen when a palpable painful abdominal mass is present on physical examination, and the spleen is absent in its normal anatomical location on radiological examination (Fig. 4, Ref. 8). Full Text (Free, PDF) www.bmj.sk.
Key words: wandering spleen, pancreatic tail infarction, pelvic mass.

Wandering spleen is characterized by a congenital deficiency or acquired laxity of splenic suspensor ligaments. It is a rare clinical entity that accounts for less than 0.25 % of all indications for splenectomy (1). The true incidence is unknown. To the best of our knowledge all cases reported in literature have been sporadic. Many complications have been reported regarding the wandering spleen, the most common being torsion (1–3). It is predisposed to torsion because of its long pedicle and high mobility. Torsion around its pedicle, which includes the vascular supply of spleen, may lead to infarction of spleen and result in acute abdomen (3). The diagnosis of wandering spleen is usually based on imaging.

We report two cases of wandering spleen in females. One of them was presented to emergency department with acute abdomen due to torsion of wandering spleen and pancreatic tail infarction. The other patient was presented to emergency department with mild abdominal pain and pelvic mass due to torsion of wandering spleen. The diagnosis and surgical treatment of wandering spleen were discussed.

Case report 1

A 30-year-old deaf-mute female was admitted to emergency department with a four-day history of abdominal distention and

¹Inonu University Faculty of Medicine, Department of General Surgery, and ²Inonu University Faculties of Medicine, Department of Obstetrics and Gynecology, Malatya, Turkey

Address for correspondence: Abuzer Dirican, MD, Inonu University, Turgut Ozal Medical Center, Dept of General Surgery, Postal code: 44069, Malatya, Turkey.
Phone/Fax: +90.422.3410660

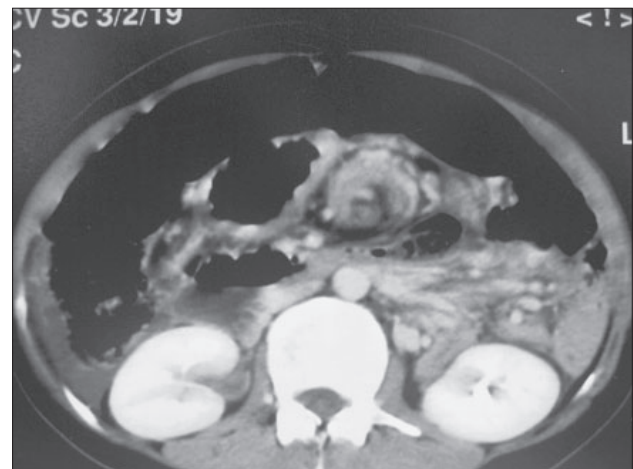


Fig. 1. Abdominal CT showing the spleen that is not in its normal location.

pain. There was no discharge of flatulence and defecation during that time. A large hard mobile painful mass extending from umbilicus to pelvis was palpated on physical examination. Severe guarding and tenderness were present in this region of abdomen. She had a temperature of 37.8 °C. Abnormal laboratory data included Hb: 8.6, WBC: 36300/ml, Amylase: 463 U/L and LDH: 950 U/L. Abdominal sonography (USG) demonstrated a 20x13x7 cm hypoechoic mass extending from umbilicus to pelvis and diffuse intraperitoneal fluid. Spleen was absent in its original place, i.e. in left upper quadrant on abdominal computed tomography (CT). In addition, hypodense infarcted areas were seen within the intraabdominal mass in the abdominal CT (Fig. 2).

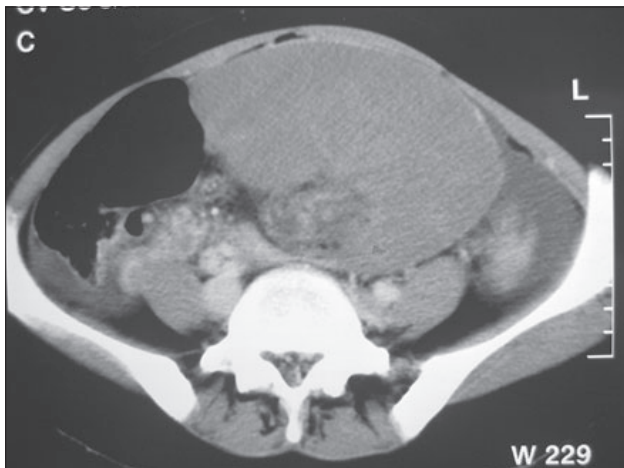


Fig. 2. Contrast enhanced CT scan of the abdomen shows a mass of 20x13x7 cm in diameter with smooth contour and hypodense infarcted areas within it.

An emergency laparotomy was planned with a presumptive diagnosis of acute abdomen due to torsion of wandering spleen and pancreatitis. At laparotomy, approximately 1000 cc of sero-hemorrhagic fluid was aspirated from peritoneal cavity. An ischemic wandering spleen on a long twisted pedicle was found in the left upper quadrant extending to the left lower quadrant of the peritoneal cavity (Fig. 3). There was also necrosis in the tail of pancreas due to the torsion of splenic pedicle. The wandering spleen and distal pancreas were removed. Patient's cecum and left colon were very mobile. Pathological examination revealed an enlarged spleen (20x13x10 cm in diameter) with hemorrhage and necrotic pancreatic tissue. Post-operative recovery was uneventful and the patient was discharged on seventh postoperative day.

Case report 2

A 19-year-old female presented with complaints of intermittent abdominal pain. A large mobile lump located in pelvis was palpated on physical examination. Mild guarding and tenderness were present in this region of the abdomen. Abnormal laboratory data included WBC of 23,300/ml and LDH of 761 U/L. USG demonstrated a 10x13x7 cm mass located into pelvis. Axial CT showed a spleen-like mass in the pelvis. A laparotomy was planned with a presumptive diagnosis of wandering spleen or intraabdominal mass. At laparotomy, a wandering spleen with a long twisted vascular pedicle was found in the pelvis. The wandering spleen was removed with its long pedicle (Fig. 4). Post-operative recovery was uneventful and the patient was discharged on third postoperative day.

Discussion

Wandering spleen is also known as *splenoptosis*, *ectopic spleen*, *free-floating spleen*, *pelvic spleen* or *aberrant spleen*. In this condition, spleen is present in a non-anatomical position, and has a long pedicle. The spleen is anchored in its normal po-

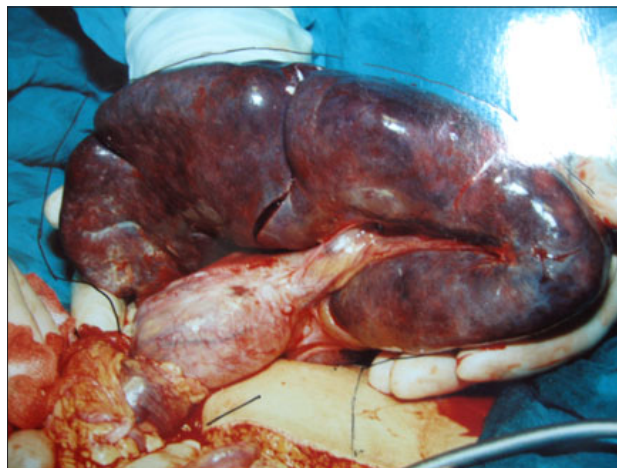

Fig. 3. Wandering spleen arising from the tail of pancreas and infarcted areas on the surface of spleen due to torsion.

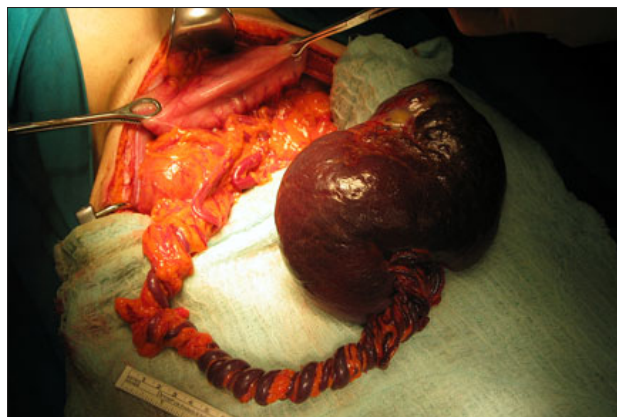


Fig. 4. Torsion of wandering spleen.

sition by several ligaments. In wandering spleen, gastrosplenic, splenorenal and other suspensor ligaments of spleen are absent congenitally or have laxity subsequent to pregnancy, hormones or injuries. Therefore the wandering spleen is found most commonly in women of reproductive age (4). It may also occur in children, who constitute one third of all cases (3). Incomplete fusion of the dorsal mesogastrium to the posterior abdominal wall during the second month of embryonic development results in an unusually long splenic pedicle.

The torsion usually occurs clockwise and is precipitated by body and adjacent organs movement and subsequent changes in intraabdominal pressure (5). The probability of torsion is high if the diameter of spleen is big and the vascular pedicle is long. With torsion of spleen venous return impairs, congestion and capsular stretching occur. This may lead to venous thrombosis. Arterial supply of spleen is compromised with edema and congestion. This leads to infarction, fibrosis, and necrosis of spleen (3). Complications of acute splenic torsion are gangrene, abscess formation, differential necrosis of pancreatic tail and bleeding gastric varicose veins (3, 6). Pancreatic tail infarction may be

due to the stretch in splenic pedicle after torsion and congestion of wandering spleen as in our first case. There is one possible explanation for this situation. When splenic pedicle is short, and spleen is heavy, the possibility of pancreatic tail infarction may be high. In our second patient, the splenic pedicle was very long and pancreatic tail infarction was not observed.

The symptoms of wandering spleen differ from an asymptomatic intraabdominal mass to acute abdominal signs secondary to torsion of the spleen. Patients may have intermittent abdominal pain resulting from intermittent torsion and detorsion. Acute torsion of wandering spleen is a rare cause of acute abdomen. Acute appendicitis, ovarian torsion, diverticulitis, nonspecific peritonitis may be considered in differential diagnosis of wandering spleen with torsion. Some patients with wandering spleen have only chronic symptoms due to compression of the intraabdominal mass.

Clinical diagnosis of wandering spleen may be difficult. Splenomegaly is generally present because of the twisting of splenic arteries and veins or due to the formation of blood clot (infarction) in the spleen. Acute torsion can cause severe abdominal pain but laboratory tests may be insufficient. Findings of hypersplenism or functional asplenia may be present (7). Pancytopenia is occasionally caused by hypersplenism. A high preoperative serum amylase level may give the clue to pancreatic tail infarction as in our first patient.

Imaging has a very important role in the diagnosis of wandering spleen. USG, nuclear scintigraphy, enhanced CT scanning and magnetic resonance imaging may be helpful in the diagnosis. USG and CT of the abdomen are the most useful diagnostic methods. USG and CT show the absence of spleen in its normal position, and a comma-shaped structure located somewhere else in the abdomen or pelvis (2). The critical point in diagnosing the wandering spleen is the demonstration of mobility of the mass with different positions of patient during the radiologic examination. Doppler US and angiography are helpful in determining the blood flow in the splenic parenchyma and hilus. Nuclear scintigraphy may be helpful but there was no time to perform it in acute torsion condition.

The only possible treatment of wandering spleen is surgery because conservative treatment is associated with increased complication rate (2). Surgical treatment is either splenectomy or splenopexy. Splenopexy is preferred for a viable wandering spleen to prevent any future complications especially in children (8). Laparoscopic mesh splenopexy is possible in cases of viable wandering spleen (7). In suspicion of an acute torsion of

wandering spleen, an emergency operation should be performed. Ischemic alterations may be seen in adjacent organs and tissues like pancreas. Therefore, these organs must be observed during surgical treatment. Surgical treatment of wandering spleen with infarction is splenectomy with open or laparoscopic approach. Other indications for resection of wandering spleen are splenic vessel thrombosis, secondary hypersplenism, any suspicion of malignancy and functional asplenia (8). Laparoscopic surgery should be considered especially in young patients from the cosmetic point view. In our cases open approach was preferred because of technical insufficiency under emergency condition.

If there is a painful intraabdominal mass in young female patient with severe abdominal pain on physical examination without underlying predisposing factors such as trauma, hepatic or hematological disorders, the torsion of wandering spleen should be kept in mind as a possible cause of acute abdomen. Absence of spleen in its normal location and abdominal mass in CT may give the clue to wandering spleen. Pancreatic tail should be observed in patients with torsion of wandering spleen because of the possibility of infarction. An increased awareness of this condition, along with a timely use of medical imaging, may help in reducing the incidence of wandering spleen infarction and infarction in the pancreatic tail.

References

1. Misawa T, Yoshida K, Shiba H, Kobayashi S, Yanaga K. Wandering spleen with chronic torsion. *Amer J Surg* 2008; 195: 504—505.
2. Singla V, Galwa RP, Khandelwal N, Pornachandra KS, Dutta U, Kochhar R. Wandering spleen presenting as bleeding gastric varices. *Amer J Emerg Med* 2008; 26: 637.e1—637.e4.
3. Ely AB, Segquier E, Lotan G, Strauss S, Gayer G. *J Pediatr Surg* 2008; 43: E23—E25.
4. Cohen MS, Soper MJ, Underwood RA, Quasebath M, Brunt LM. Laparoscopic splenopexy for wandering (pelvic) spleen. *Surg Laprosc Endosc* 1998; 8: 286—290.
5. Desai DC, Hebra A, Davidoff AM, Schnaufer L. Wandering spleen: a challenging diagnosis. *South Med J* 1997; 90: 439—443.
6. Buehner M, Baker MS. The wandering spleen. *Surg Gynecol Obstet* 1992; 175: 373—387.
7. Palanivelu C, Rangarajan M, Senthilkumar R, Parthasarathi R, Kavalat AJ. Laparoscopic mesh splenopexy (sandwich technique) for wandering spleen. *JLS* 2007; 11: 246—251.
8. Tan HH, Ooi LLPJ, Tan D, Tan CK. Recurrent abdominal pain in a woman with a wandering spleen. *Singapore Med J* 2007; 48: 122—124.

Received November 25, 2008.

Accepted August 18, 2009.