

## CLINICAL STUDY

# Surgical treatment of pulmonary metastases in germ-cell testicular cancer patients – long-term results

Schnorrer M<sup>1</sup>, Ondrus D<sup>2</sup>, Vichova B<sup>1</sup>, Oravsky M<sup>1</sup>, Bak V<sup>1</sup>

3rd Department of Surgery, Comenius University Medical School, Hospital Milosrdni bratia, Bratislava, Slovakia. [Milan.schnorrer@milosrdni.sk](mailto:Milan.schnorrer@milosrdni.sk)

**Abstract:** *Objectives:* The aim of this prospective clinical study is to evaluate our 20-year experience with surgical treatment of pulmonary metastases in germ-cell testicular cancer and discuss the optimal therapeutic approach.

*Background:* Authors presents 63 patients who were surgically treated in the period from 1988 to 2008 for pulmonary metastases in germ cell testicular cancer. All patients were allocated for surgical treatment after undergoing cisplatin-based combination chemotherapy.

*Methods:* In a group of 63 patients, 57 thoracotomias and 27 sternotomias were performed. In pulmonary procedures small atypical resections prevailed – 84 %. Postoperative mortality was 1.2 %. Decision for follow-up treatment was made on basis of histological investigation of metastases. In some cases when viable tumor tissue was found (16 % patients), further chemotherapy was administered. The rest of patients were monitored intensively.

*Results:* In a long-term follow-up, remission was achieved in almost 60 % of patients.

*Conclusion:* We suggest that lung metastasectomy as the secondary treatment in generalized germ cell testicular cancer should be fully warranted (*Fig. 3, Ref. 16*). Full Text (Free, PDF) [www.bmj.sk](http://www.bmj.sk).

Key words: testicular cancer, pulmonary metastasis, post-chemotherapy surgery.

Lung metastasectomy as treatment of choice in pulmonary metastases has been discussed for a long time. Nowadays, lung metastasectomy, 81 years after the first publication concerning surgical removing of solitary pulmonary metastasis performed by Jiří Diviš (1), and the multidisciplinary approach to oncology patients with pulmonary metastases has been generally accepted. The reason for increasing number of lung metastasectomy is the progress in anesthesiology techniques and perioperative care that leads to substantial risk decrease in thoracotomy or sternotomy. Another factor enhancing the surgical treatment of pulmonary metastases is the “conservative surgical approach”, i.e. minimal lung intervention with few complications. Regarding surgical treatment of pulmonary metastases, there are two large groups of patients. In the first group primarily treated by lung metastasectomy only, no other treatment has been available so far. In the second group the primary effective chemotherapy is used, thus the surgical treatment of pulmonary metastases is secondary. This group of patients involves also generalized germ-cell tumors of the testicle. Nowadays, the clinical stage IV of the disease with pulmonary metastases occurs in 5.3 % of patients (2).

<sup>1</sup>3rd Department of Surgery, Comenius University Medical School, Hospital Milosrdni bratia, Bratislava, Slovakia, and <sup>2</sup>1st Department of Oncology, Comenius University Medical School, St. Elisabeth Cancer Institute, Bratislava, Slovakia

**Address for correspondence:** M. Schnorrer, MD, PhD, Dept of Surgery, Comenius University Medical School, Hospital Milosrdni bratia, Nam. SNP 10, SK-814 65 Bratislava, Slovakia.  
Phone: +421.2.57887 401

The aim of this prospective clinical study is to evaluate our 20-year experience with surgical treatment of pulmonary metastases in germ-cell testicular cancer and discuss the optimal therapeutic approach.

## Patients and methods

In the period of 1988–2008, 63 patients were surgically treated for residual pulmonary metastases of germ-cell tumors of the testicle. Patients were allocated for surgical treatment after cisplatin-based combination chemotherapy in case of positive pulmonary finding and normal levels of tumor markers. Patients were classified into clinical stage IV according to CT verification of pulmonary metastases. In case of positive CT findings in the retroperitoneum, lymph node dissection preceded lung metastasectomy. This approach is determined by normal levels of tumor markers. In the first years of the study we performed bilateral s. c. sequential thoracotomy within the interval of 3–4 weeks between thoracotomies. Since 1991 bilateral pulmonary metastasectomy, using sternotomy with exploration of both pleural cavities at the same time was performed. All patients were followed up regularly. Survival rate of patients was evaluated according to Kaplan-Meier method.

## Results

The mean age of patients at the time of surgical removing of primary tumor was 30.8 years, median 30.3 (15.1–52). In the

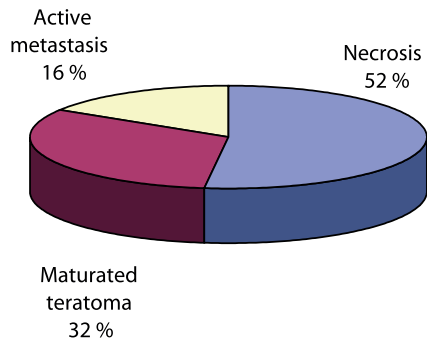


Fig. 1. Distribution of histological examinations.

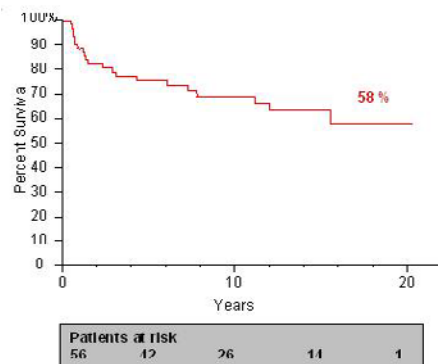


Fig. 2. A long-term survival rate of the patients with a primary testicular tumor following the lung metastasectomy (Kaplan-Meier).

time of lung metastasectomy the mean age of the patients was 31.9 years, median 31.5 (15.5–52.21). The time interval between surgical removing of the primary tumor of the testis and lung metastasectomy was 1.1 year, median 0.5 (0–7.93).

Overall 55 thoracotomies and 24 sternotomies in 63 patients were performed. 7 (11 %) of patients underwent bilateral sequential thoracotomy, 9 patients underwent repeated thoracotomy due to recurrent metastases.

In case of primary resection of pulmonary metastases small procedures dominated – atypical partial resections were performed in 53 patients (84 %). In remaining 10 patients (16 %), 8 lobectomies, one bi-lobectomy and one total pneumonectomy were performed. On average 2.8 metastases, median 2 (1–14) were removed during one surgical procedure.

In surgically removed tissue in 20 patients (32 %) mature teratoma was found, in 33 (52 %) patients necrosis or fibrosis of the tissue was found, and in 10 patients (16 %) viable tumorous tissue together with necrotic foci were found, respectively (Fig. 1).

Nine patients underwent repeated metastasectomy due to recurrent metastases. The time interval between first metastasectomy and repeated surgery was on average 3.4 years, median 1.57 (0.43–8.89). Four patients underwent atypical pulmonary resection and 5 patients underwent lobectomy.

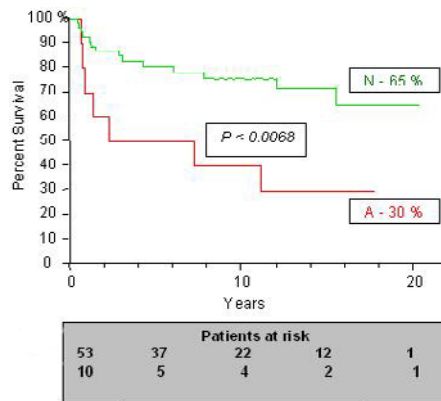


Fig. 3. A long-term survival rate according to histological type of metastase (Kaplan-Meier). N – necrosis fibrosis of tissue, A – variable tumorous tissue.

The mean duration of follow-up of the whole cohort was 8.88 years, median 7.85 (0.52–20.44). Out of 63 patients, 42 (67 %) survived (Fig. 2). One patient (1.2 %) died due to respiratory insufficiency shortly after pneumonectomy. Regarding his post-mortem findings of preoperatively not diagnosed extrapulmonary metastases in the brain, pancreas, suprarenal gland and liver, this patient was not correctly assessed for surgical treatment. Survival rate concerning the histological findings is illustrated in Figure 3. At present 30 % patients with finding of viable tumor tissue survived, in case of mature teratoma, necrosis and fibrosis of tissue 39 out of 53 patients survived. 6 patients out of 9 survived after repeated metastasectomy with average follow up of 12.4 years, median 14.1 (2.9–20.4).

### Discussion and conclusion

Primary chemotherapy is the standard therapeutic method in disseminated tumors of the testis. Efficacy of anticancer chemotherapy is high, thus complete remission is achieved in 60–80 % of patients (3, 4, 5). Surgical treatment plays a significant role in multidisciplinary approach to patients with pulmonary metastases. Decision making in the treatment of pulmonary metastases requires histological investigation. It is impossible to determine reliably the nature of the lung focus neither preoperatively (RTG, USG, CT), nor macroscopically during the surgery. In case of pulmonary resection it is vital to remove all suspected focal tissue, because of the possibility of parallel occurrence of viable tumor tissue, together with fibrosis, necrosis or mature teratoma. Patients with histological findings of fibrosis, necrosis or mature teratoma are being intensively monitored. Active malignant tissue was found in 16 % of residual foci in the whole cohort. Similar percentage of viable tumor tissue from 10 to 20 % is reported in the literature (6, 7, 8). All these patients were subsequently treated by chemotherapy. Prognosis of long-term survival of these patients is significantly worse. 30 % of patients of our cohort survived more than 15 years, Caginy (7) reports 5 year-survival rate of 51 %. Further important reason for surgical

treatment of pulmonary metastases is reduction of tumor masses s.c. debulking, which can improve survival of the patient in this stage of dissemination. In patients with germinative tumors of the testis, debulking is generally warranted due to availability of highly effective chemotherapy. In multivariate analysis prognostic factors that most negatively influence long-term survival are findings of viable tumor tissue and incomplete resection of metastases (7).

Present level of evidence-based medicine confirms the low risk of thoracotomy, because in metastasectomy mostly s.c. „economy“ small resections are being performed, i.e. bordering or wedge-shaped resections, which accounted for 84 % of procedures in our cohort. Lobectomies were rarely performed. Post-operative mortality should not exceed 1–2 % in hospitals experienced in surgery of pulmonary metastases (9, 10, 11, 12, 13). There was only one case of early death reported in our cohort after pneumonectomy (mortality 1.5 %). The patient was surgically treated in the first years of our study, when CT was not a routine investigation method, and the autopsy revealed incorrect indication for surgery.

Efficacy of anticancer chemotherapy in germinative tumors of the testis is continuously improving and it brings an important progress. In our cohort almost 60 % remission rate was achieved in long-term follow-up in patients with pulmonary metastases. Similar results were achieved by other authors (8, 14, 15, 16) and thus we consider lung metastasectomy as the treatment of choice in patients with generalized germ-cell testicular cancer.

## References

1. **Divis G.** Ein Beitrag zur operativen Behandlung der Lungengeschwulste. *Acta Chir Scan* 1927; 62; 329–341.
2. **Ondrusova M, Plesko I, Safari-Diba Ch, Obsitinkova A, Stefanakova D, Ondrus D.** Comprehensive analysis of incidence and mortality tumors in the Slovak Republik (online) Bratislava. National Cancer Registry of the Slovak Republik; NHIC; 2007.
3. **Ondrus D, Hornak M, Matoska H, Kausitz J, Belan V, Carsky S.** Chemotherapy of testicular cancer: 10-year experience. *Neoplasma* 1993; 40; 247–253.
4. **Ondrus D, Hornak M, Matoska J.** Neo-adjuvant chemotherapy with delayed orchiectomy in patients with advanced germ cell testicular cancer. *Neoplasma* 1993; 40; 189–192.

5. **Carver BS, Sheinfeld J.** Germ cell tumors of the Testis. *Ann Surg Oncol* 2005; 12; 871–880.
6. **Hartmann JT, Schnoll HJ, Kuczyk AM, Candelaria M, Bokemeyer C.** Postchemotherapy resection of residual masses from metastatic non-seminomatous testicular germ cell tumors. *Ann Oncol* 1997; 8; 531–538.
7. **Cagini L, Nicholson AG, Horwich A, Goldstraw P, Pastorino U.** Thoracic metastasectomy for germ-cell tumors: Long-term survival and prognosis factors. *Ann Oncol* 1998; 9; 1185–1191.
8. **Lui D, Abolhoda A, Burt ME, Martini N, Bains M, Downey RJ, Rusch AW, Bsol GJ, Ginsberg R.** Pulmonary metastasectomy for testicular germ cell tumors: a 28 year experience. *Ann Thorac Surg* 1998; 66; 1709–1714.
9. **Poncelet AJ, Lurquin A, Weynand B, Humblet Y, Noirhomme P.** Prognostic factors for long-term survival in patients with thoracic metastatic disease: a 10-year experience. *Eur J Cardiothorac Surg* 2007; 31; 173–180.
10. **Stier A, Heidecke CD.** Die chirurgische Therapie der Lungenmetastasen — Indikationen, Technik und Ergebnisse. *Radiologe* 2004; 44; 715–718.
11. **Schnorrer M, Ondrus D, Carsky S, Hornak M, Belan V, Kausitz J, Matoska J.** Management of germ cell testicular cancer with pulmonary metastases. *Neoplasma* 1996; 43; 47–50.
12. **Dienemann H, Hof H, Debus J, Drings P.** Lungenmetastasen. *Oncologie* 2004; 10; 458–473.
13. **Eckersberger E, Moritz E, Wolner E.** Results an prognostic factors after results of pulmonary metastases. *Eur J Cardiothorac Surg* 1988; 2; 433–437.
14. **Kenneth A, Kesler MD, Jamison L, Wilson MS, Jason A, Cosgrove MS et al.** Surgical salvage therapy for malignant intrathoracic metastases from nonseminomatous germ cell cancer of testicular origin: Analysis of a single-institution experience. *J Thorac Cardiovasc Surg* 2005; 130; 408–415.
15. **Kesler KA, Wilson JL, Cosgrove A, Brooks A, Messiha A, Fineberg NS, Einhorn LH, Brown JW.** Surgical salvage therapy for malignant intrathoracic metastases from nonseminomatous germ cell cancer of testicular origin: Analysis of single-institution experience. *J Thorac Cardiovasc Surg* 2005; 130; 408–415.
16. **Carsky S, Ondrus D, Schnorrer M, Majek M.** Germ cell testicular tumours with lung metastases: chemotherapy and surgical treatment. *Int Urol Nephrol* 1992; 24; 305–311.

Received April 8, 2009.

Accepted June 26, 2009.