

CLINICAL STUDY

Cochlear implantation in malformed inner ear

Kabatova Z¹, Profant M¹, Simkova L², Groma M³, Nechojdomova D¹University ORL Dept, Medical School of Comenius University, Bratislava, Slovakia. profant@fnorl.sk

Abstract: *Objectives:* Authors evaluate diagnosis, surgery and results in the implantees with malformed inner ear. *Methods:* Four children with the inner ear malformations were included in this series (one child with common cavity, two children with narrow internal auditory meatus and one child with lateral semicircular canal aplasia). CT and MRI were used for the imaging of inner ear malformations. Different types of implants (Medel Combi 40+, Nucleus Freedom) with different types of electrodes were used. The average time of being the cochlear implant user in the time of evaluation was 3 years.

Results: Pure tone audiometry (PTA), Category of Auditory Performances (CAP), Evaluation of spontaneous speech and Evaluation of speech understanding were used to evaluate of the CI outcome.

Conclusions: Malformation of inner ear with the developed cochlear nerve nowadays is the indication for CI. Counselling with parents must be open and detailed to inform them on realistic expectations and different ways of deaf child education (Tab. 4, Fig. 4, Ref. 13). Full Text (Free, PDF) www.bmj.sk.

Key words: inner ear malformation, deafness, cochlear implantation, rehabilitation, results.

Due to the functional results cochlear implantation (CI) nowadays is a method of choice in the management of congenital or acquired deafness. There are many factors that may influence the outcome of CI. One of the most influential factors is the anatomical integrity of the inner ear. Differentiation of bony labyrinth, shape of the internal acoustic meatus (IAM), size and position of the 8th nerve are the information to be evaluate by imaging in each CI candidate. In the majority of CI candidates the deafness is caused by the malfunction of the organ of Corti in anatomically differentiated inner ear with preserved ganglion cells and nerve fibers. In these patients good results can be expected if implanted in the appropriate age.

In children with malformed inner ear the preoperative situation is different. Only the shape of malformed inner ear is to our disposal, there is no information on the number of hair cells, ganglion cells or nerve fibers. The number of patients with inner ear malformations is limited and all the centers should bring information on these patients to reach global experience for recommendations and counseling parents of patients with malformed inner ear.

In this paper we present our experience with cochlear implantation in patients with malformed inner ear.

Material and methods

In the period 1994–2007 187 patients have been implanted in our department. There were 123 children (111 children with

¹University ORL Dept, Medical School of Comenius University, Bratislava, Slovakia, ²Faculty Hospital, Logopedic Dept., Bratislava, Slovakia, and ³Faculty Hospital, Dept. of Otorhinolaryngology, Bratislava, Slovakia

Address for correspondence: M. Profant, MD, PhD, University ORL Dept, Antolska 11, SK-851 07 Bratislava 5, Slovakia.
Phone: +421.2.63531541

prelingual deafness, 5 children with perilingual deafness and 5 children with postlingual deafness). In 4 children with congenital deafness malformation of the inner ear was found (3.6 %):

Bilateral common cavity in one child (0.9 %) (Fig. 1), narrow internal auditory meatus in two children (1.8 %) (Fig. 2), bilateral aplasia of lateral semicircular canal (LSC) (0.9 %) (Fig. 3).

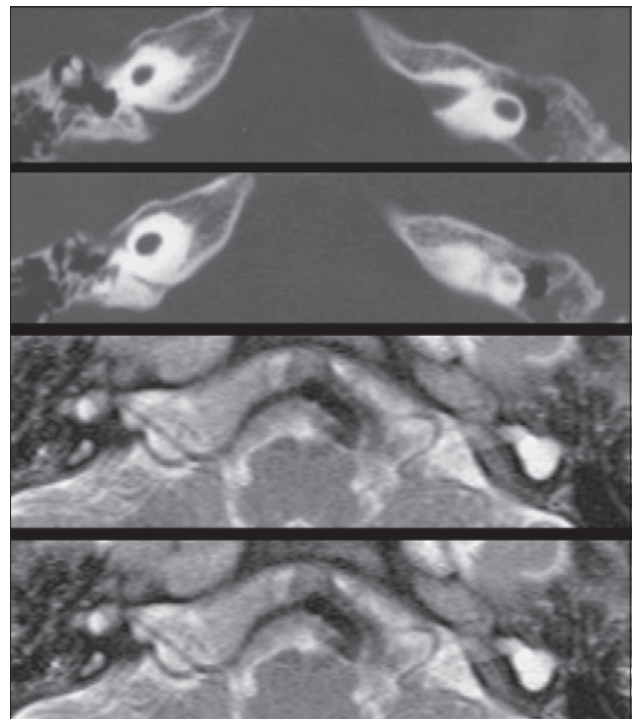


Fig. 1. CT and MRI scans of common cavity.

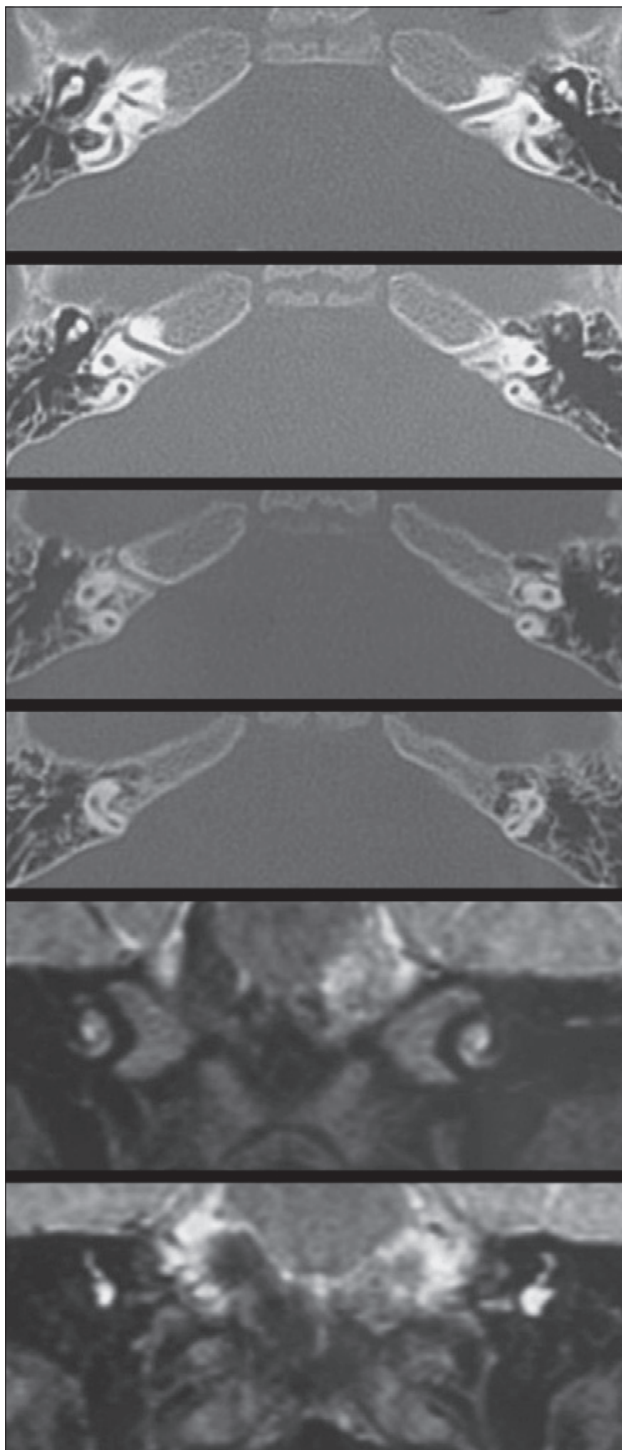


Fig. 2. CT and MRI of narrow internal auditory meatus and 7th, 8th cranial nerves.

The youngest child was 2,2 years old at the time of implantation, the oldest 4 years at the time of implantation. Three children were implanted with Nucleus Freedom standard electrode device, the child with common cavity was implanted with Medel C40+S device with short electrode array. All children were op-

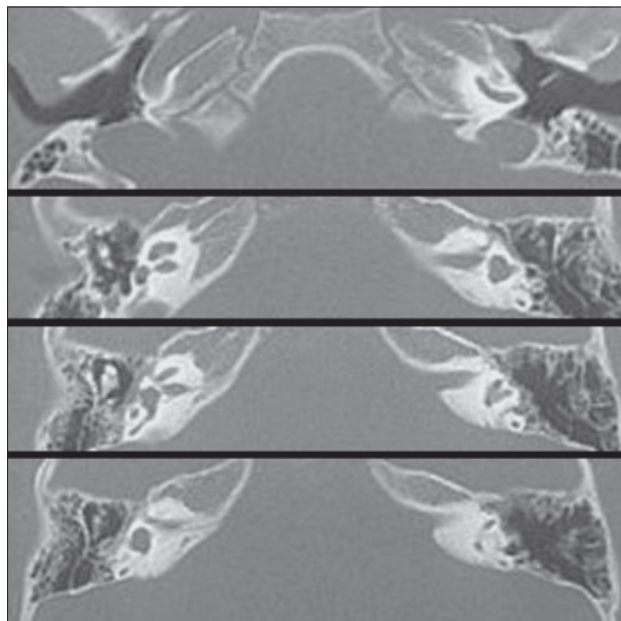


Fig. 3. CT scan of bilateral LSC (Lateral Semicircular Canal) aplasia.

erated by one surgeon with standard approach via mastoidectomy, posterior tympanotomy and cochleostomy (Tab. 1).

Following tests have been done to evaluate the functional outcome of cochlear implantation:

- PTA in free field (warble tone) with CI
- Speech audiometry in free field
- Category of auditory performances (CAP)
- Evaluation of spontaneous speech production
- Evaluation of implantee's speech understanding

Results

Hearing tests

Before CI there was some residual hearing for warble tone in low frequencies in a child with lateral semicircular canal aplasia (normal radiologic image of cochlea). In all other children there was no hearing before implantation.

After CI in all children reaction to sound was detected. Child with common cavity has no perception in low frequencies while the PTA in middle and high frequencies can be detected at 20–25 dB. In all other children the PTA threshold in all frequencies is better than 50–60 dB. Free field PTA tests with warble tone are shown in Figure 4.

In speech audiometry tests (pediatric speech audiometry) no child can repeat a single word without lip-reading.

In evaluation of auditory performances (CAP) all children show perception of environmental sounds. Child with lateral canal aplasia 6 months after CI reacts to the speech sounds and 2 children with narrow internal acoustic meatus 3 years after CI can repeat some single words without lip-reading (Tab. 2).

Speech evaluation

There are significant differences in spontaneous communi-

Tab. 1. Structure of patients and inner ear malformations.

	Number of children	Gender	Reason of deafness	Age at time of CI (years)	Device	Implant user in time of evaluation (years)
Common Cavity	1	F	Unknown	2.5	Medel C40+S	2
Narrow acoustic meatus	2	F	Unknown	2.2 3.3	Nucleus Freedom CI24RE (CA)	3 6
Lateral semicircular canal aplasia	1	M	Unknown	4	Nucleus Freedom CI24RE (CA)	0.5

Tab. 2. Category of Auditory Performances (CAP) in children with inner ear malformation.

Category of Auditory Performances	Malformations and results
0 No environmental sound detection	0
1 Detection of environmental sounds	1 Child with common cavity
2 Reaction to speech sound	1 Child with lateral canal aplasia
3 Identification of environmental sounds	0
4 Differentiation of sound speech without lip-reading	2 Children with narrow IAM
5 Understanding of everyday sentences without lip-reading	0
6 Understanding of speech without lip-reading	0
7 Telephoning	0

Tab. 3. Spontaneous speech evaluation in children with inner ear malformations.

Evaluation of spontaneous speech	Malformations
0 No speech	0
1 Meaning vocalization	1 Child with common cavity
2 Using several simple words	1 Child with lateral canal aplasia
3 One-word sentences	0
4 Two-words sentences	1 Children with narrow IAM
5 Three-words sentences (subject-predicate-object)	1 Children with narrow IAM
6 Multiwords sentences with solecism	0
7 Multiwords sentences and simple compound sentences with sporadic solecism	0
8 Full spontaneous communication	0

Tab. 4. Evaluation of speech understandability in children after CI in malformed inner ear.

Understandability of speech	Malformation
0 Impossible to evaluate speech, vocabulary is missing	0
1 Non understandable speech	1 Child with common cavity 1 Child with lateral canal aplasia
2 Partially understandable speech, speaker must complete information also nonverbally	2 Children with narrow IAM
3 Understandable speech if the listener knows the context	0
4 Understandable speech if the listener is experienced in communication with deaf	0
5 Speech understandable to majority of listeners	0
6 Speech understandable to all listeners	0

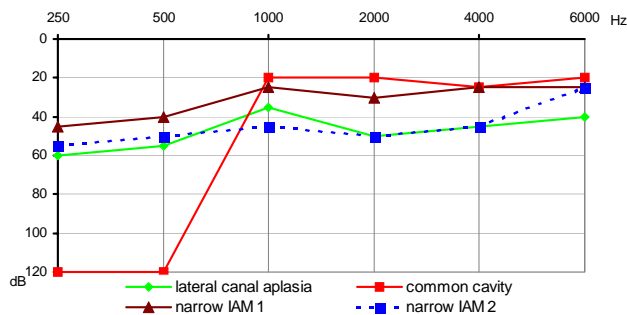


Fig. 4. Free field PTA (Pure Tone Audiometry) in children with inner ear malformation after CI.

cation among the children of this group from meaning vocalization (child with common cavity) to creating simple 3-words sentences (children with narrow IAM) (Tab. 3).

The understandability of speech in 2 children with narrow IAM with active vocabulary creating also simple sentences is very limited for standard listener; this kind of speech is understandable for those who are experienced with communication with deaf people (parents, relatives, teachers of deaf). The speech of other children from our series is not understandable (Tab. 4).

In all children after the first fitting there was a progress in sound detection.

Surgical results

In a child with lateral semicircular canal aplasia and children with narrow IAM the electrode array was implanted by standard approach via mastoidectomy, posterior tympanotomy and cochleostomy with full insertion. In one of these children the stapedial reflex was missing (with normal impedances).

In a child with common cavity the incus and bony bridge and finally posterior ear canal bony wall were removed temporarily to improve access to the cochleostomy site. There was deep drilling 4–5 mm to open the common cavity followed by perilymphatic gusher. Two mm were missing to the full insertion of the short version of electrode array. At the end of the procedure posterior canal wall was fixed to its original position and cochleostomy was packed with fat. Because of the liquorrhea the revision surgery was done 9 days after the surgery to pack completely middle ear cavity with fascia, muscle tissue and fibrin glue. There was no liquorrhea after revision surgery.

Discussion

Inner ear malformation is one of the reasons of congenital deafness. Jansen found inner ear malformation in about 20 % of children with congenital deafness (1). This seems to be too high incidence. In the series of deaf children in our center we found inner ear malformation in about 5 % of our deaf children. Wu et al found 38 % of malformation in the series of 160 deaf children (2). Loundon et al found 6.9 % inner ear malformation in the series of 260 implanted children (3).

The high resolution CT gives a perfect image of bony inner ear structures. Experienced otologist and radiologist can make diagnosis of inner ear malformation very easily. MRI imaging is regularly done in all patients with inner ear malformation (some centers do MRI imaging in all CI candidates). Especially in cases with narrow IAM information on presence and size of the acoustic nerve is of utmost importance.

Recently information on differentiation among the stages of hypoplasia – aplasia of the cochlear nerve appeared in literature (4, 5, 6). For children with cochlear nerve aplasia brainstem implantation is the option (7).

Special category of inner ear malformation is lateral semicircular canal aplasia. Johnson et al found in 15 patients (2 with unilateral aplasia) all kinds of hearing loss from the conductive to the sensorineural deafness (8).

Cochlear malformation is a predisposition for meningitis development either spontaneous or after cochlear implantation. Spontaneous communication of inner ear liquids with CSF and communication of perilymphatic space with middle ear cavity through cochleostomy are clear etiopathogenetic factors. Immunization against meningitis is generally recommended before cochlear implantation, especially in children with inner ear malformation.

Cochlear implantation in malformed inner ear requires experienced CI surgeon who knows all available techniques to insert electrode array into the malformed inner ear. The position of the facial nerve should be identified on the CT scan. Since there might be a higher incidence of facial canal abnormalities the facial nerve monitoring is recommended (9). Mylanus et al found aberrant facial nerve in 17 % of children with inner ear malformation (10). There was no anatomical variation of the facial canal in our series, there was no facial nerve impairment after CI in our patients.

All kinds of electrodes (standard, short, split electrode) should be available when the CI in malformed inner ear is planned. Electrodes with preformed shape are not suitable for malformed inner ear. Fishman et al recommend fluoroscopically assisted insertion for accurate placement of electrodes in the malformed cochlea (11).

After CI in all our children with inner ear malformation the reaction to sound stimulation was recorded. Nevertheless no child reaches results similar to average results of implantees with normal bony inner ear. The worst result was found in a child with common cavity (evaluated 2 years after CI). This child can detect the environmental sounds while average children of the same age can understand everyday sentences without lip-reading. Better improvement in speech perception then in speech production can be expected in this child in the future.

The best results can be expected in a boy with lateral semicircular canal aplasia. Now he is using the implant for several months only, he adequately reacts to sounds, to the speech stimuli and he starts to repeat single words.

Two children with narrow IAM use their implants for 3 and 6 years. They do not reach the level as other implanted children of the same age. While children without malformation under-

stand the speech without lip-reading, speak in complex sentences children with narrow IAM speak in 1–2 words sentences, they can repeat only single words without lip-reading and their speech is similar to the speech of deaf children without CI.

Arnoldner et al referred on 6 children with moderate malformations (incomplete partition, hypoplasia, and unexpected gusher during surgery) with good results similar to children with normal bony cochlea (12). Despite this fact they recommend thorough counseling. Luntz et al present doubtful results in children with common cavity while in children with incomplete partition they reach good results comparable to children with normal bony cochlea (identification of sound, scoring in open sets) (13).

Conclusion

Malformation of the inner ear with present cochlear nerve is not a contraindication to cochlear implantation nowadays. On the other hand parents of children with malformed inner ear should be clearly informed that even if implanted in the ideal age (1–3 y) the results will not reach the level of the deaf children of similar age with normal bony inner ear. For CI candidate selection in case of malformed inner ear each center should keep following principles:

- 1) To realize CT and MRI in all cases
- 2) Absence of cochlear nerve (confirmed by MRI) is contraindication to cochlear implantation
- 3) Counseling with parents must be open with all information on results, complications as well as on other possibilities to educate the deaf child.
- 4) Child should be immunized against meningitis before cochlear implantation
- 5) Surgery must be done by experienced surgeon who has all kinds of electrodes to his/her disposal
- 6) Implanted child with inner ear malformation requires more attention in the postoperative period with intensive rehabilitation

References

1. Jansen S. Malformation of the inner ear in deaf children. *Acta Radiol* 1969; 286: S1–97.
2. Wu CC, Chen YS, Chen PJ, Hsu CJ. Common clinical features of children with enlarged vestibular aqueduct and Mondini dysplasia. *Laryngoscope* 2005; 115 (1): 132–137.
3. Loundon N, Rouillon I, Munier N, Marlin S, Roger G, Garabedian EN. Cochlear Implantation in Children with Internal Ear Malformations. *Otol Neurotol* 2005; 26: 668–673.
4. Casselman JW, Offeciers FE, Govaerts PJ et al. Aplasia and hypoplasia of the vestibulocochlear nerve: diagnosis with MR imaging. *Radiology* 1997; 202: 773–781.
5. Govaerts PJ, Casselman J, Daemers K, De Beukelaer C, Yperman M, De Ceulaer G. Cochlear implants in aplasia and hypoplasia of the cochleovestibular nerve. *Otol Neurotol* 2003; 24: 887–891.
6. Zanetti D, Guida M, Barezani MG, Campovecchi C, Nassif N, Pinelli L, Giordano L, Oliosio G. Favorable Outcome of Cochlear Implant in VIIIth Nerve Deficiency. *Otol Neurotol* 2006; 27: 815–823.
7. Colletti V, Carner M, Fiorino F et al. Hearing restoration with auditory brainstem implant in three children with cochlear nerve aplasia. *Otol Neurotol* 2002; 23: 682–693.
8. Johnson J, Lalwani AK. Sensorineural and conductive hearing loss associated with lateral semicircular canal malformation. *Laryngoscope* 2000; 110: 1673–1679.
9. Graham JM, Phelps PD, Michaelis L. Congenital malformations of the ear and cochlear implantation in children: review and temporal bone report of common cavity. *J Paryngol Otol* 2000;25 (Suppl): 1–14.
10. Mylanus EA, Rottveel LJ, Leeuw RL. Congenital malformation of the inner ear and pediatric cochlear implantation. *Otol Neurotol* 2004; 25 (3): 308–317.
11. Fishman AJ, Roland JT Jr, Alexiades G, Mierzwinski J, Cohen NL. Fluoroscopically Assisted Cochlear Implantation. *Otol Neurotol* 2003; 24: 882–886.
12. Arnoldner C, Baumgartner WD, Gstoettner W, Egelierler B, Czerny C, Steiner E, Hamzavi J. Audiological performance after cochlear implantation in children with inner ear malformations. *Int J Pediat Otorhinolaryngol* 2004; 68: 457–467.
13. Luntz M, Balkany T, Hodges AV, Telischi FF. Cochlear implants in children with congenital inner ear malformations. *Arch Otolaryngol Head Neck Surg* 1997; 123: 974–977.

Received March 31, 2009.

Accepted June 26, 2009.