

CASE REPORT

Paediatric forearm fractures: functional outcome of conservative treatment

Nazari Ahmad Tarmuzi¹, Shalimar Abdullah¹, Zulkiflee Osman², Srijit Das³

Department of Orthopaedics, Faculty of Medicine, Universiti Kebangsaan Malaysia (UKM), Jalan Yaakob Latiff, Cheras, Kuala Lumpur, Malaysia. kelapa44@yahoo.com

Abstract: *Background:* Forearm fractures are common in the paediatric age group. Closed reduction and casting are the primary means of treatment in over 90 % of these fractures. Resultant deformities are usually a product of indirect trauma involving angular loading combined with rotational deformity and fragment displacement.

Materials and methods: Retrospectively, 48 patients aged between 4 to 12 years with forearm fractures, were treated conservatively with closed reduction and a cast during a 2-year period. Functional outcomes were measured in terms of pronation and supination.

Results: All fractures united before the final visit. Most forearm bone fractures were complete fractures at the mid shaft. Eighty-six percent of the patients had excellent functional outcomes and none had poor outcomes. There were significantly reduced angles of deformities before and after treatment ($p < 0.05$). Radiographically, in the frontal plane, 57.1 % of radius and 73.9 % of ulnar fractures achieved perfect reduction (i.e. a degree of deformity of less than 5°). However, in the lateral plane, there were fewer perfect reductions for the radius and ulna, at 14.6 % and 54.3 %, respectively. All except for one patient were satisfied with the outcomes. The level of fracture did not influence the outcomes.

Conclusion: Conservative treatment is still an acceptable form of treatment especially for stable forearm fractures in children achieving excellent outcomes (*Tab. 1, Fig. 7, Ref. 20*). Full Text (Free, PDF) www.bmj.sk. Key words: paediatric, forearm, radius, ulna, anatomy, fractures, conservative, reduction, treatment.

Forearm fractures are common paediatric injuries accounting for 45 % of all fractures and for 62 % of all upper limb fractures (1). The majority (81 %) occur in children who are more than 5 years old, with a peak incidence of distal forearm fractures occurring in girls at 10 to 12 years of age and boys at 12 to 14 years (1). The most common causes of forearm fractures include a fall in or near home, followed by sport-related injuries (2).

Approximately 75 % to 84 % of forearm fractures occur in the distal third with another 15 % to 18 % in the middle third, while 1 % to 7 % of cases occur in the proximal third (3). A small percentage are bilateral, and as many as 13 % have an associated supracondylar fracture (4). Just over 50 % of these fractures are greenstick fractures (2). Injuries to the distal growth plate of the radius bone occur in 14 % to 18 % of forearm fractures (2, 3). In an earlier study of 500 consecutive fractures in the paediatric age group, the site of a forearm fracture was likely to be more proximal with advancing skeletal age and physal

fractures occurring more often in early adolescence as compared to the younger age group (5).

Rotation of the forearm is the movement most frequently lost following these fractures (6). Residual rotational losses of greater than 20° have been found in 60 % of patients who were treated for forearm fractures (7). However, subjective results are usually excellent, and any decreased range of movement is often detectable only by special goniometric testing (8).

Mild limitation in rotation is not noticeable to the patient because the shoulder adequately compensates for any loss of forearm pronation or supination e.g. A loss in pronation is compensated with the shoulder abducting and internally rotating whilst a loss in supination has the shoulder going into the adduction and external rotation. Therefore, even with stringent criteria, 85 % of patients with displaced fractures achieve satisfactory results from closed reduction of the forearm (7).

Similarly, Zions et al (2005) found a satisfactory functional outcome in those treated with closed method despite residual angulations (8). The average loss of supination was 4° (range 0°–20°) and the average loss of pronation was 6.8° (range 0°–40°). Bayonet apposition, location of the fracture and age of the patient did not appear to influence the forearm rotation. An earlier study had reported poor functional prognosis for their 581 forearm fractures with palmar and ulnar diaphyseal deformities of the radius treated conservatively (9). The degree of deformity of a fracture for both angulation and malrotation may affect the functional outcome in a child and various range of acceptability has been cited.

¹Department of Orthopaedics, Faculty of Medicine, Universiti Kebangsaan Malaysia (UKM), Jalan Yaakob Latiff, Cheras, Kuala Lumpur, ²Department of Orthopaedics, Hospital Kuala Lumpur, Jalan Pahang, Kuala Lumpur, Malaysia, and ³Department of Anatomy, Faculty of Medicine, Universiti Kebangsaan Malaysia, Jalan Raja Muda Abd Aziz, Kuala Lumpur, Malaysia

Address for correspondence: Shalimar Abdullah, MD, Dept of Orthopaedics, Faculty of Medicine, Universiti Kebangsaan Malaysia, Jalan Yaakob Latiff, Bandar Tun Razak, Cheras, 56000 Kuala Lumpur, Malaysia. Phone: +6012.2240915, Fax: +603.91738609

Research studies have mentioned that angulations of 10° did not affect the motion whilst an angular deformity of more than 20 have been shown to limit the forearm rotation by 30° (10). An earlier study had accepted angulations up to 15° and malrotations up to 45° in children younger than 8 years (11). Since distal fractures had better prognosis than proximal fractures, they were treated conservatively for angulations up to 15° and malrotations up to 30° even though the displacement was complete. For proximal fractures, those with angulations up to 10° and malrotations of 30° even with complete displacement still had a satisfactory result. A local study of early forearm fracture remodeling in children recommend an acceptance of 10–20-degree angulations in midshaft fractures, and 20–30-degree angulations in metaphyseal fractures (12).

The present study was aimed at investigation whether any conservative treatment produces good functional outcomes with regard to the degree of deformity and fracture patterns as seen at a local clinical setting. Additionally, the study explored the outline of the demographic data of diaphyseal forearm fractures occurring in children.

Materials and methods

The present study was a retrospective study concerned with the functional outcomes of conservative treatment in paediatric diaphyseal forearm fractures. This study was carried out at the Pediatric Orthopedic Unit, Orthopedics and Traumatology Institute, Hospital Kuala Lumpur (HKL) between January 2004 and December 2006. The minimum follow-up period to study the outcome was 6 months after the injury.

The inclusion criteria included all complete and incomplete diaphyseal forearm fractures of either single or both forearm bones in children between 4 to 12 years of age, closed fractures treated with closed methods and forearm fractures without any associated ipsilateral humeral bone fractures.

The diaphyseal forearm fracture is defined as a fracture occurring within the central three fifths (3/5) of the forearm in order to eliminate elbow fractures and fractures at the junction of the distal end and metaphyseal area. The latter have been shown to have a favourable prognosis. The acceptable angulations in this study (after reviewing the pre-existent literature data in agreement with the authors) were defined as 25° or less and less than 1 cm bayonet apposition with corrected rotational deformity. Forearm radiographs included anteroposterior and lateral views of the whole length of both radius and ulnar bones including the elbow and wrist joints. Radiographs were taken at least twice in the first 3 weeks.

The exclusion criteria were open fractures of the forearm, fractures occurring outside the diaphyseal area, fractures associated with ipsilateral humeral fractures, pathological fractures, Monteggia or Galeazzi fractures and patient with only partial radiographic views of the radius and ulna bones.

The functional outcome was assessed during the final treatment with the range of motion of the forearm measured in terms of pronation and supination. The forearm rotation was measured

Tab. 1. Table showing patterns of bone fracture.

Fractures	Site of fracture		Radius	Ulna
Radius only	6	Proximal	17 %	17 %
Ulna only	2	Midshaft	69 %	66 %
Both radius and ulna	40	Distal	14 %	17 %
Total	48		100 %	100 %

by testing the patient’s grip with a pen while supinating and pronating the forearm. The arch of supination and pronation were objectively measured using a goniometer. The patients were asked whether they had had any subjective symptoms or limitation in function. The alignment of both bones were measured on radiograph taken at the final visit. Angulation was defined as the maximal angulation of each bone present either on the AP or lateral view. Union was defined as an absence of tenderness at the fracture site and radiographs showing callus formation across all four cortices.

Outcome measurement

The final outcome measurement was based on the criteria used by Price et al 1990 (13).

Excellent – no complaint with strenuous physical activity and/or loss of ≤10° forearm rotation

Good – mild complaints with strenuous physical activity and/or loss of 11°–30° loss of forearm rotation

Fair — mild subjective complaints during daily activities and/or a 31°–90° loss of forearm rotation

Poor – all other results

Data analysis and interpretation of results are performed using the SPSS software version 15. The Students t-test and chi-square were used to analyze the numerical results.

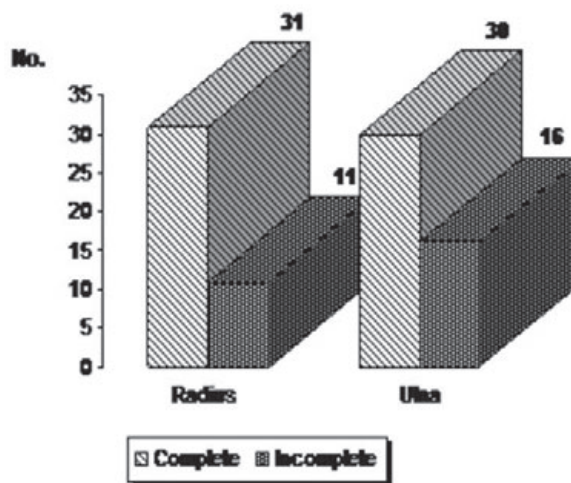


Fig. 1. Figure showing the completeness of bone fracture.

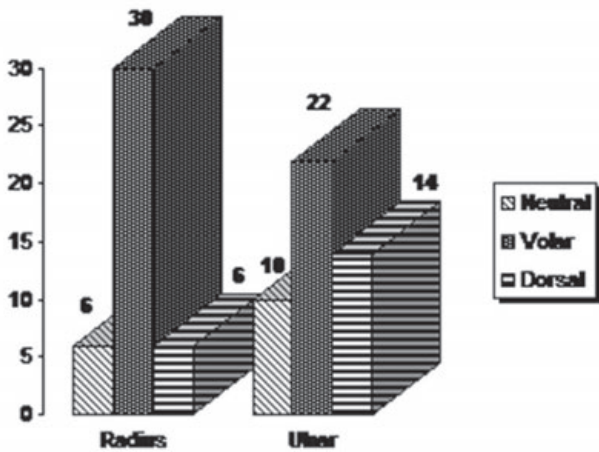


Fig. 2. Figure showing deformity of the bones in the lateral plane after treatment. On final assessment of the radiographs, there were more ulnar and radius bones with volar deformity as compared to neutral or dorsal angulation.

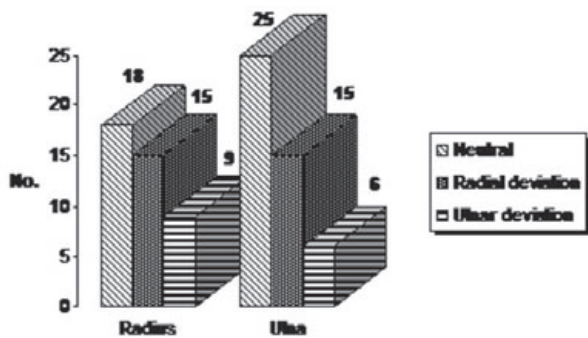


Fig. 3. Figure depicting bone deformities in the frontal plane after treatment. There were more ulnar and radius bones achieving neutral alignment as compared to the radial and ulnar deviations.

Results

A total of 68 patients were included in the study population. However, 20 patients declined to return for assessment as they claimed their fractures had healed well without any functional deficit. Thus, only 48 patients were available for the final assessment.

The mean age was 8 years and 5 months. A total of 38 patients were boys (79.2%) and 10 were girls (20.8%). The mechanism of injury was a fall from less than 1 metre height, representing 95.8% (n=46), one child was involved in a motor vehicle accident and the other had her forearm caught in a closing door).

Malays constituted the largest race involved in the study population (n=39 or 81%), with Indians accounting for 17% (n=8) and only one Chinese (2%). Forty patients sustained forearm fractures of both bones and 8 patients had single-bone fractures (6 patients had isolated radius fractures and other 2 had

isolated ulna fractures). For radius fractures, the commonest site was the mid shaft of the radius (n=29 or 69.0%), followed with proximal third (n=7 or 16.7%) and distal third (n=6 or 14.3%). The commonest site for ulnar fractures was also at the mid shaft (n=30 or 65.2%), equally followed by proximal third and distal third areas (both equal n=8 or 17.4%) (Tab. 1).

A total of 31 radius fractures were complete (73.8%) and 11 incomplete (26.2%). For ulnar fractures, 30 were complete (65.2%) and 16 incomplete (34.8%) (Fig. 1). All patients were treated with closed manual reduction under sedation (intravenous Pethidine and intravenous Midazolam) administered according to their weight) and a full-length cast above elbow were applied. They were treated on an outpatient basis. None of these patients had re-manipulation after the initial treatment. The mean duration of casting was 4.6 weeks (range 3 to 7 weeks)

Radiographic interpretation

On final assessment of radiograph, in reviewing the radiograph in lateral plane after treatment, both radius (n=22 or 52.4%) and ulna (n=30 or 65.2%) had volar deformity compared to neutral or dorsal angulations. In the frontal plane, 42.8% of radius fractures (n=18) had achieved neutral position post treat-

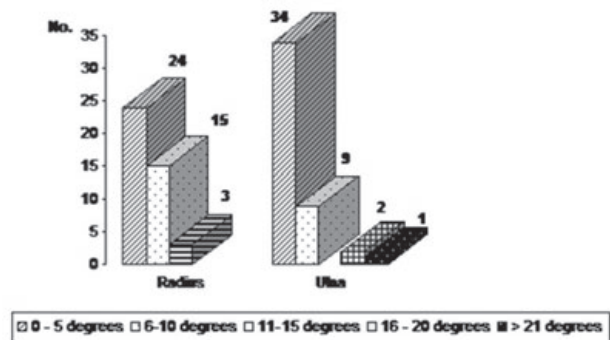


Fig. 4. Degree of deformity in the frontal plane for each bone.

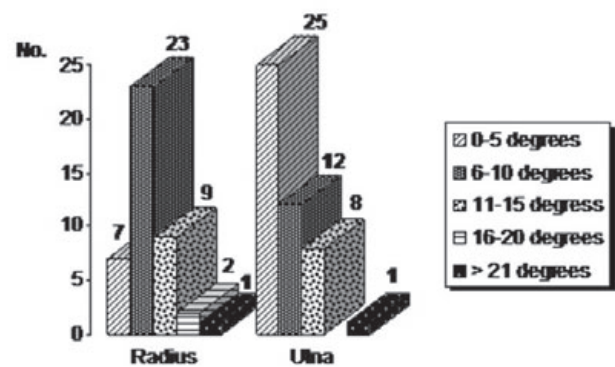


Fig. 5. Figure showing a degree of deformity in the lateral plane for each bone.

ment as compared to radial deviation that was present in 35.7 % of cases (n=15) and ulnar deviation in 21.5 % of cases (n=9). For the ulnar bone, 54.3 % (n=25) had achieved neutral position as compared to radial deviation that was present in 32.6 % of cases (n=15) and ulnar deviation in 13.1 % of cases (n=6) after treatment (Figs 2 and 3).

Most of the radius bones (57.1 % or n=24) achieved perfect frontal alignment in the frontal plane, 35.7 % (n=15) became deformed in range from 6° to 10°, and 7.2 % (n=3) became deformed in range from 11° to 15°. No radius was deformed in more than 16°. For the ulnar bone, 73.9 % (n=34) achieved perfect alignment, whilst 19.6 % (n=9) became deformed in range of 6°–10°. Two ulnar bones became deformed in range of 16°–20° and the deformity of one ulnar bone was more than 20° (Fig. 4).

On the lateral plane, 23 radius fractures (54.8 %) had an angulation deformity in range of 6°–10°, and 9 (21.4 %) angulated in range of 11°–15°. Only 7 radius bones had perfect alignment. Two radius bones had an angulation in range of 16°–20° and 1 had a deformity more than 20°. For the ulna, most patients achieved perfect alignment in the lateral plane i.e. in 54.3 % (n=25), 12 had an angulation in range of 6°–10°, and 8 had an angulation in range of 11°–15°. However, one ulna had a deformity of more than 20° (Fig. 5).

All fractures were treated with closed manual reduction under sedation at the Emergency Department. No re-manipulation of fracture was done, and non-union was not observed in this

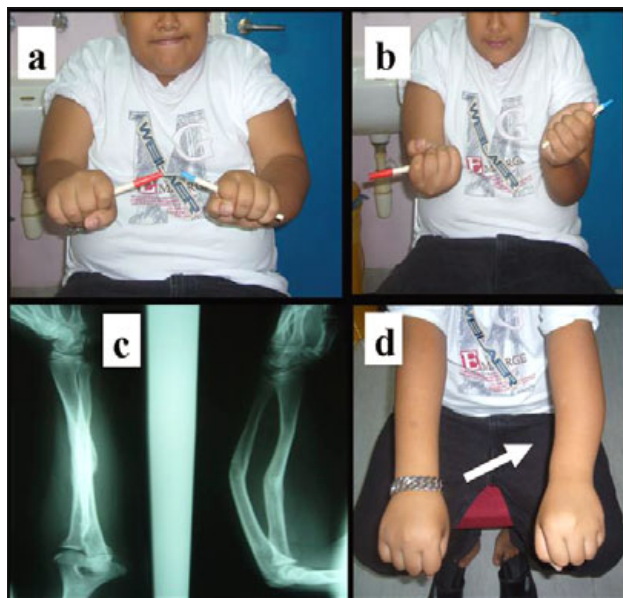


Fig. 6. Photograph of a 10-year old boy with a left forearm fracture with significant reduction of supination of 50° (a, b). The most affected bone was the ulna with 25° of radial angulation and 5° of dorsal angulation. The radius had 15° of radial angulation and 18° of dorsal angulation (c). There was an obvious deformity in the left forearm (arrow in d). He had a dominant right hand. Although we categorized him as fair outcome, he was very concerned with the deformity and requested corrective osteotomy.

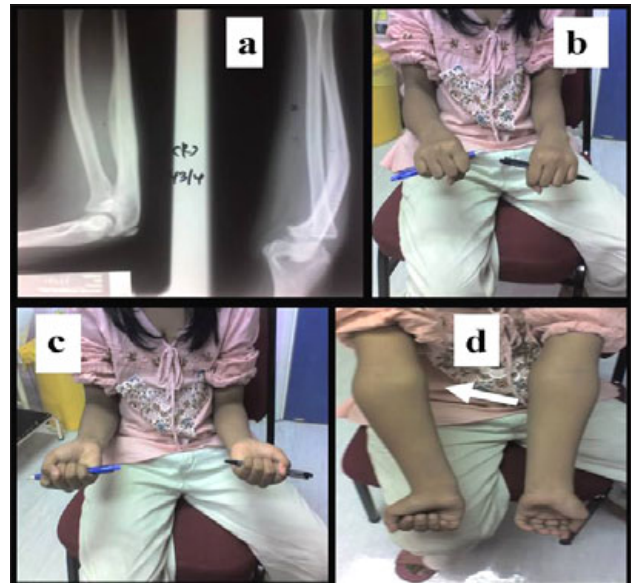


Fig. 7. A 10-year old girl completely fractured the proximal third of her right ulna (a). She presented with 24° of dorsal angulation with a full range of supination and pronation of the forearm (excellent category) (b, c). Although, we offered corrective osteotomy for cosmetic reason (arrow in d) she declined, as she was satisfied with her functional outcome.

study. The mean union rate of fractures treated conservatively in this series was 4.6 weeks.

Functional outcome

Evaluation of the movement range at the final follow-up showed full range of movement in both elbow and wrist joints in all patients compared with the unaffected extremity. Forearm rotation was equal to the unaffected side in 40 of 48 patients (83 %). Eight patients had some limitation of movement (4 patients had limitation in pronation; 3 patients had limitation in supination and 1 patient had a decrease in both).

According to the grading criteria, there were 40 excellent results (85 %), 6 good results (12 %), 1 fair result (3 %) and no poor results. Of six patients with good outcome, 3 had limited pronation, 2 had limited supination and 1 had both pronation and supination limited.

We compared two 10-year-old children, both with deformed ulnar bones at 25°. Both had cosmetic deformity but functionally, one had a fair outcome and the other had an excellent outcome (Figs 6 and 7).

Additionally, one patient had a radial deformity at a radial angulation with limited supination of 60°. She fractured her forearm at the age of 11 years with a complete midshaft fracture of the radius and an incomplete midshaft fracture of the ipsilateral ulna. In the sagittal plane, she had 10° of dorsal angulation for both radius and ulna and 14° radial angulation of the ulna. However, she was satisfied with the function of her forearm, and we categorized it as a good outcome.

Bayonet apposition, location of fracture and patient's age did not influence the forearm rotation that was achieved. No non-

unions, synostoses or cast-related complications were observed in this study.

Discussion

Children frequently sustain diaphyseal forearm fractures. Closed reduction and casting has been the primary means of treatment for over 90 % of these fractures. Completely displaced fractures of the diaphysis of the radius and ulna in children younger than 8 or 9 years of age can usually be successfully treated by closed methods because of the rapid healing time and predictable remodeling that is seen in this age group (8).

Conservatively treated diaphyseal forearm fractures are reported to have a rate of angular deformities ranging from 10–60 % (14, 15). Angular deformities of the radius and ulna are associated with impairment of forearm rotation in 10–50 % of all patients. It has been reported that 14.8 % of patients treated conservatively had an unsatisfactory outcome with impairment of forearm rotation and/or cosmetic deficits. In our study, we found no impairment in terms of rotation although two patients had cosmetic deformities.

A 10–20° angulation in midshaft fractures, and a 20–30° angulation in metaphyseal fractures for early remodeling potential is an accepted fact (12). In this study, we chose an age range between 4 to 12 years because we believed that the bone has the ability to heal and remodel with an acceptable functional outcome after conservative treatment of the forearm fracture.

Clinical studies of forearm malunion suggest that angulation alone is a poor predictor of forearm motion. Factors other than angulation may contribute to loss of forearm motion, such as undetected malrotation and contracture of the interosseous membrane (6, 16). Most activities of daily living could be accomplished with 100- of forearm rotation equally divided between pronation and supination (17). It was reported that only 2 of 17 patients with a persistent malunion (defined as angulation of 20°) noted a functional or cosmetic problem (18).

In an earlier study, it was reported that although 9 of 51 children with proximal forearm malunion lost 15° or more of forearm motion, only 2 patients were aware of this deficit (19). An earlier study reviewed 53 forearm fractures in children treated by closed means followed for an average of 3 years (7). The same study had noted that 28 patients had limitation of supination, pronation, or both, but this did not interfere with their activities as it was compensated at the glenohumeral joint. In our study, even a degree of deformity up to 20° did not impair the daily activities of our patients.

Cadaveric studies reported that deformities measuring more than 20° were unacceptable (6). These deformities caused a considerable impairment of 30° loss of forearm rotation compared to the control group. Most authors report angular deformities between 10° and 20° to have relevant effects. An angular deformity >20° has been shown to limit the forearm rotation by 30-, whereas 10- of angulation had a negligible effect on motion (10).

Our clinical outcomes were categorized as 40 patients with excellent results (85 %), 6 with good results (12 %), 1 with fair

results (3 %) and no patients with poor results in accordance with earlier grading by Price et al (13). The fair result was a patient with both, radius and ulna deformities in the same plane with the ulna bone angulated >20°.

It has been emphasized that the radius plays a decisive role in forearm function (18). This indicates that palmar and torsional deformities of the radius are more frequently associated with poor functional outcome, especially regarding pronation. These results were confirmed by an earlier study providing evidence that a poor outcome is significantly associated with palmar angular deformities of the radial shaft (20). In our study, we showed that residual volar deformities of the radius had a higher chance of producing a limitation in pronation (5 out of 8 of our patients suffered a loss of forearm rotation although statistically untested).

Deformities directed towards the same plane did not necessarily limit the forearm rotation, and deformities in the frontal plane of both bones being angulated in one direction did not lead to any limitation (6, 7). In our study, 7 patients out of 8 with loss of forearm rotation had a limited pronation and supination with combined deformity directed in the same plane. However, they were still considered to have a good functional outcome with no alteration in daily activities.

Complete bayonet apposition did not influence the functional outcome as described in an earlier study (8). We agree on this statement as one of our patients with 5 mm bayonet apposition in the radius had a dorsally and radially angulated ulna with forearm limitation but this had no effect on his functional outcome.

Conclusion

Good clinical results can be achieved in the treatment of displaced both-bone fractures of the diaphysis in older children and adolescents using closed reduction and cast immobilization. In children older than 10 years, an angulation of 20° or more should not be accepted in order to have good functional outcome and cosmetically acceptable appearance. For children younger than 10 years, an angulation up to 20° can be accepted and treated conservatively. Overall, conservative treatment is still an acceptable standard method for stable forearm fractures in children and we have achieved excellent outcomes.

References

1. Bailey DA, Wedge JH, McCulloch RG, Martin AD, Bernhardtson SC. Epidemiology of fractures of the distal end of the radius in children as associated with growth. *J Bone Joint Surg Amer* 1989; 71: 1225–1231.
2. Worlock P, Stower M. Fracture patterns in Nottingham children. *J Pediatr Orthop* 1986; 6: 656–660.
3. Gandhi RK, Wilson P, Mason Brown JJ, Macleod W. Spontaneous correction of deformity following fractures of the forearm in children. *Brit J Surg* 1962; 50: 5–10.
4. Stanitski CL, Micheli LJ. Simultaneous ipsilateral fractures of the arm and forearm in children. *Clin Orthop Rel Res* 1980; 153: 218–222.
5. Tredwell, S, Van Peteghem K, Clough M. Patterns of forearm fractures in children. *J Pediatr Orthop* 1984; 4: 604–608.

6. **Matthews LS, Kaufer H, Garver, DF, Sonstegard DA.** The effect on supination-pronation of angular malalignment of fractures of both bones of the forearm. *J Bone Joint Surg Amer* 1982; 64: 14–17.
7. **Daruwalla JS.** A study of radioulnar movements following fractures of the forearm in children. *Clin Orthop Relat Res* 1979; 139: 114–120.
8. **Zionts LE, Zalavras CG, Gerhardt MB.** Closed treatment of displaced diaphyseal both-bone forearm fractures in older children and adolescents. *J Pediatr Orthop* 2005; 25: 507–512.
9. **Weinberg AM, Kasten P, Castellini C, Jablonski M, Hofmann U, Reilmann.** Which Axial Deviation Results in Limitations of Pro- and Supination Following Diaphyseal Lower Arm Fracture in Childhood. *Eur J Trauma* 2001; 6: 309–316.
10. **Flynn JM, Waters PM.** Single-bone fixation of both-bone forearm fractures. *J Pediatr Orthop* 1996; 16: 655–659.
11. **Price C.** Fractures of the shaft radius and ulna. Part II. In: Rockwood CA, Beaty JH (Eds). *Fractures in children*. Vol. 3. Philadelphia: Lippincott Raven, 1996; 515–548.
12. **Qairul et al.** Forearm fractures in children. Master dissertation prepared for the Master in Orthopaedics, Faculty of Medicine, Universiti Kebangsaan Malaysia (UKM). 2001.
13. **Price CT, Scott DS, Kurzner M, Flynn JC.** Malunited forearm fractures in children. *J Pediatr Orthop* 1990; 10: 705–712.
14. **Schmittenebecher PP, Dietz HG, Uhl S.** Late results of forearm fractures in childhood. *Unfallchirurg* 1991; 94: 186–190.
15. **Van der Reis WL, Otsuka NY, Moroz P, Mah J.** Intramedullary nailing versus plate fixation for unstable forearm fractures in children. *J Pediatr Orthop* 1998; 18: 9–13.
16. **Tarr RR, Garfinkel AI, Sarmiento A.** The effects of angular and rotational deformities of both bones of the forearm. An in vitro study. *J Bone Joint Surg Amer* 1984; 66: 65–70.
17. **Morrey BF, Askew LJ, An K, Chao EY.** A biomechanical study of normal functional elbow motion. *J Bone Joint Surg Amer* 1981; 63: 872–877.
18. **Fuller D, McCollough C.** Malunited fractures of the forearm in children. *J Bone Joint Surg Brit* 1982; 64: 364–367.
19. **Holdsworth B, Sloan J.** Proximal forearm fractures in children: residual disability. *Injury* 1982; 14: 174–179.
20. **Davis DR, Green DP.** Forearm fractures in children: pitfalls and complications. *Clin Orthop Relat Res* 1976; 120: 172–183.

Received January 16, 2009.

Accepted May 28, 2009.