

EXPERIMENTAL STUDY

The healing role of erythropoietin in the obstructive vs nonobstructive left colonic anastomosis

Faruquzzaman¹, Saroj Kumar Mazumder²

Chittagong Medical College Hospital Chittagong, Bangladesh.

Abstract: We aimed to evaluate possible effects of erythropoietin on the healing of anastomosis in both obstructive and non-obstructive states. It was an experimental study on guinea pigs. Although erythropoietin had positive effects on pressure in the group IV when compared to the group II, it had no effect in the group III. Despite an increased tissue hydroxyproline levels in the group IV, erythropoietin failed to show any effects in the group III. Erythropoietin had positive effects on neovascularization, fibroblast proliferation and storage of collagen in the group IV. We failed to find any direct and evident effects of erythropoietin on the healing of left colonic anastomosis. On the other hand, erythropoietin might prevent negative effects of obstruction on healing (Tab. 2, Fig. 4, Ref. 33). Full Text (Free, PDF) www.bmj.sk.

Key words: erythropoietin, obstructive left colonic anastomosis, nonobstructive left colonic anastomosis.

Anastomotic leakage is an important problem following a primary resection of the left colon and it is even more prominent when obstruction is present (1). A dehiscence of intestinal anastomosis remains a major complication after gastrointestinal tract surgery. The resulting anastomotic dehiscence and leakage may lead to high rates of morbidity and mortality. The risk of anastomotic leakage is high in the large intestine surgery in contrast with the small intestine surgery (2, 3). Various factors including the surgical technique, patient's nutritional state, localization (left colon or right colon) and the type of operation, patient's age, presence of obstruction and whether the operation was elective or emergency, affecting the success of anastomotic healing have been studied (2, 3, 4).

Normal wound healing and tissue repair are controlled by a series of regulatory peptides which are released in the response to specific stimuli and interact in a refined and coordinated manner. These peptides or growth factors have both local and systemic affect on cells (5, 6). One of the growth factors that are thought to have a positive effect on the wound healing process is erythropoietin, a haematopoietic growth factor (7–11). In an experimental study that evaluated the effect of erythropoietin (EPO) on the left colonic anastomotic healing, the administration of EPO appeared to have beneficial positive effects on the healing rate and breaking strength of large intestine anastomoses in guinea pigs (10, 11). There is no study dealing with the effects on healing after the obstructive states.

Our aim was to evaluate possible effects of EPO on the healing of experimental left colonic anastomosis in both obstructive and non-obstructive states.

Methods

Type of study: Experimental study on guinea pigs.

Place of study: Pharmacology laboratory, Pathology laboratory of Chittagong Medical College and helpful support of general surgery wards of Chittagong Medical College Hospital, Bangladesh.

Period of study: 28.10.07 to 11.12.08.

Sample size: 40 guinea pigs.

Type of sampling: Convenient type of purposive sampling.

Experimental animals: The Study was approved by the Laboratory animal ethics committee of the Chittagong Medical College Hospital, Bangladesh.

All the guinea pigs were obtained from the same breeding centre and were placed in a temperature-controlled environment (Pharmacology Dept. of Chittagong Medical College, Bangladesh). The guinea pigs were fed with standard diet before the operation. No preoperative preparation or fasting period was done. The guinea pigs were operated under general anaesthesia using an intramuscular injection of 35 mg/kg (50 mg/ml flagon) ketamin hydrochloride and 2 mg/kg xylasin.

Surgical procedure: Forty male guinea pigs weighing 200–250 g were divided in the four groups of ten animals, three experimental groups and one control group. Through a 3 cm midline laparotomy, the left colon was found and mobilised and two cm long segmental colonic resection and primary anastomosis was performed just two cm proximal to the peritoneal reflection in the group I and III.

Chittagong Medical College Hospital Chittagong, Bangladesh

Address for correspondence: Faruquzzaman, Dr, C/O: Md.Moazzem Hossain (Engineer), House No. 7, Islambag Road (Paulpara), Railygate, Daulatpur (Postal code 9202), Khulna Bangladesh.

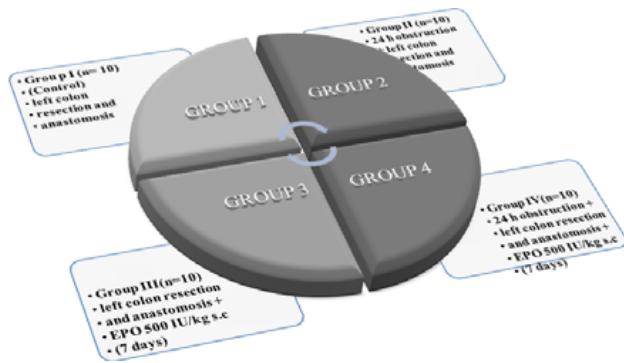


Fig. 1. Study design.

The left colon was completely ligated two cm above the peritoneal reflection using a 5/0 polypropylene in the group II and IV. 24 hours later, animals were re-operated and two

cm long segmental colonic resection and primary anastomosis was performed.

All anastomosis were performed using interrupted 6/0 polypropylene sutures, (Prolene, Ethicon) in a single layer, end to end and extramucosal manner. The abdomen was closed with interrupted 3/0 silk sutures. Animals in the group III and IV were given 500 IU/kg/day of recombinant erythropoietin subcutaneously for seven days following the operation.

Guinea pigs in the group I and II were given an isotonic sodium chloride injection subcutaneously for seven days following the operation. Study design is shown in the Figure 1.

Guinea pigs were allowed to have free access to water during the first postoperative 12 h period and were fed regularly with standard chow afterwards. No antibiotics were given.

Bursting pressure measurement: Seven days after the surgery, all guinea pigs underwent re-laparotomy under the general anaesthesia for the determination of the *in vivo* bursting pressure (BP) prior to the death (by cardiac puncture) without an interruption of the normal mesenteric blood supply or adhesions to the anastomosis using the modification of the technique described by Jiborn et al (12, 13). Anastomotic bursting pressure (ABP) was measured by passing a catheter per *anum* up to the area of anastomosis.

The lumen of the colon was cleaned of fecal content by gentle wash-out with saline. Without a disturbance of the adhesions, the bowel (2 cm above and below the anastomosis) was tied with a 0 silk ligature. The distal catheter was connected via a pressure transducer to recorder. The bowel was infused with a continuous flow of physiological saline (1.5 ml/min). The pressure in the bowel was monitored during injection and the bursting pressure (mmHg) was taken as the maximum pressure achieved during the injection phase. After the killing, the anastomotic site was resected and divided vertically into two parts. One was used for the hydroxyproline measurement and the other placed in the 10 % formaline for histopathological examination.

Tissue hydroxyproline measurement: Quantification of collagen in the enteric anastomosis is synonymous with quantification of hydroxyproline, an amino acid unique to collagen pro-

Tab. 1. Histological Grading Scale*.

0	No evidence
1+	Occasional evidence
2+	Light scattering
3+	Abundant evidence
4+	Confluent cells or fibers

* modified from (15).

teins in most tissues. Stored tissues were cleared from anastomotic material. Approximately 50 mg of tissue was taken from each sample and colorimetric assay method was used for the determination of hydroxyproline (14). The principle of the method was a hydrolysis of the tissue specimen with the 6N hydrochloric acid resulting in the formation of free amino acids from proteins. The results were calculated as micrograms (μg) of hydroxyproline per milligram (mg) of wet tissue weight.

Histological evaluation: After being stained with haematoxylin and eosin, colonic tissues and anastomosis were examined under the light microscopy and were graded in a blind fashion, using a modified 0 to 4 numerical scale by Ehrlich and Hunt (Tab. 1) (15, 16). The evaluated parameters were inflammatory cell infiltration, fibroblast ingrowths, neovascularization and collagen deposition. Each parameter was assessed individually using the numerical scale.

The following parameters were assessed individually: inflammatory cell infiltration, blood vessel and fibroblast in growth, and collagen deposition.

Data processing and analysis

Using a computer based statistical package, a statistical analysis was done. Data was analyzed with the SPSS computer package program. The survey data was usually analyzed using a descriptive statistic, such as the mean, SD, percentage, co-efficient of variation, etc. All parameters were expressed as the mean + standard error of the mean (SEM).

Report was produced by a computer based program Microsoft Word, Power point, Adobe and other accessories. P value less than 0.05 was considered significant.

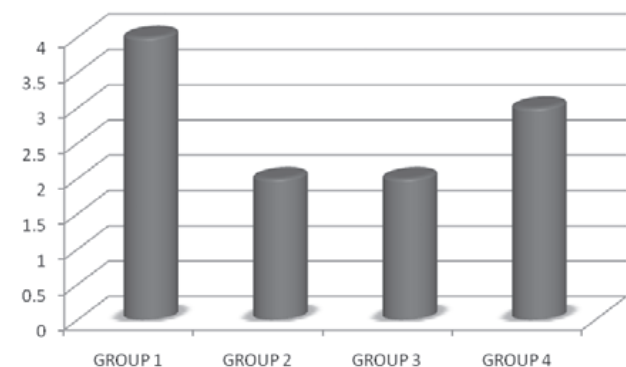


Fig. 2. Number of no survivals.

Tab. 2. Mean (SEM) values of the parameters in all groups.

Groups	1	2	3	4
No. of no survivors	4	2	2	3
Bursting pressure (mmHg)	202	172.6	206.3	199.1
Hydroxyproline level (µg/mg)	1.72	1.60	2.12	2.47
Inflammation	2.6 (0.5)	4 (0)	3.5 (0.7)	3.8 (0.4)
Neovascularization	2 (0)	1.6 (0.5)	3.8 (0.4)	2.6 (0.5)
Fibroblast in growth	4 (0)	1.8 (0.8)	4 (0)	3.8 (0.4)
Collagen deposition	2 (0)	1.8 (0.4)	2.6 (0.5)	2.6 (0.5)

Results

During this experimental study, 11 guinea pigs died and were replaced. There was no spontaneous anastomotic dehiscence, intraabdominal abscesses, or other infection. All data is shown in the Figure 2 and Table 2.

The comparison of bursting pressures

Bursting pressures differed significantly between the groups ($p < 0.05$). When the bursting pressures of the control group and the others were compared, the highest value was observed in the group III (resection+anastomosis+EPO) and the lowest value was observed in the group II (obstruction+resection+anastomosis).

When we compared the results of the groups, where the same surgical intervention was performed (groups I–III, III–IV), but EPO was given in one and the other not, there was no statistical difference between the groups I and III ($p > 0.05$) but a statistically significant difference was found between the groups II and IV ($p = 0.03$). EPO showed a positive sign of an increase bursting pressure after the obstruction. The mean bursting pressures by the groups are shown in the Figure 3, as well as in the Table 2.

The comparison of tissue Hydroxyproline levels

In the groups where EPO was given (Groups III–IV), the tissue HPO levels were higher than in the groups where EPO was not given EPO (Groups I–II) ($p = 0.002$). The lowest HPO

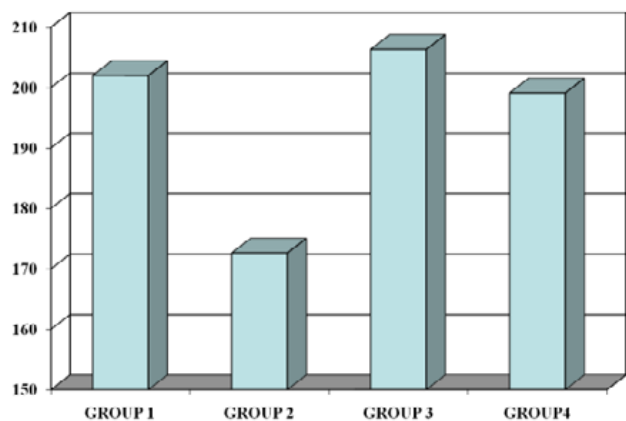


Fig. 3. Bursting pressure (mmHg).

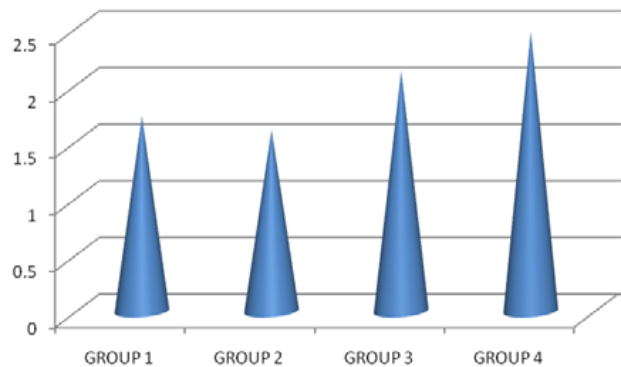


Fig. 4. Hydroxyproline level (µg/mg).

levels were measured in the Group II, which was an obstruction-resection group. The highest HPO levels were measured in the Group IV where EPO was given after the obstruction-resection. In the case, where obstruction was performed, EPO increased tissue HPO levels more significantly. Although the HPO levels were higher in the groups where EPO was given (Group III), when compared to the control group, there was no significant difference between these groups ($p > 0.05$). The mean tissue Hydroxyproline levels of the groups are shown in Table 2 and Figure 4.

Histological findings (Tab. 2)

In all the groups compared to the control group, inflammatory cell infiltration was more intense and the differences between the groups were statistically significant ($p = 0.001$). In the Groups II, III, and IV there was not a significant difference in the inflammatory cell infiltration ($p > 0.05$). There was a significant difference in the neovascularization between the groups where EPO was or was not given. In the resection + anastomosis group, where EPO was given (Group III), an intense neovascularization was observed compared to the all other groups and this difference was significant ($p = 0.001$). Furthermore, in the obstruction+resection+anastomosis group where EPO was given (Group IV), neovascularization was more intense compared to the Group II where EPO was not given and this was significant ($p = 0.001$). In the Groups I, III and IV, fibroblast proliferation was observed equally and was statistically insignificant ($p > 0.05$).

In the Group II, where obstruction+anastomosis was performed, fibroblast proliferation was lower than in the other groups and the difference was statistically significant ($p = 0.003$). It has also been observed that the obstruction had a negative effect on tissue fibroblast proliferation and this effect disappeared after EPO injections.

In spite of this, EPO did not have a significant effect on anastomosis, which was performed without obstruction, regarding fibroblast proliferation. Although the storage of collagen was equal and higher in the groups where EPO was given (Group III and Group IV), when compared to the control group, there was not a significant difference ($p > 0.05$). In contrast, when the Group III and Group IV were compared with the Group II, which had the lowest storage of collagen, the difference was significant ($p = 0.02$).

In this case, it was observed that a decreased storage of collagen after resection increased positively with the administration of EPO and this was significant in the obstruction group (Tab. 2).

Discussion and conclusions

The insufficiency of intestinal anastomosis remains the most important cause of morbidity and mortality after the gastrointestinal tract surgery. Despite an increased risk of leakage after an emergency procedure at all sites of intestine, the occurrence of anastomotic leakage appears more frequently during colonic operations with a high morbidity and mortality.

Various factors have been shown to effect the healing of anastomosis (2, 3, 4). One of the growth factors thought to have a positive effect on the wound healing process is erythropoietin, a haematopoietic growth factor. Erythropoietin (EPO) is a glycoprotein with a true hormonal structure, which is located in the alpha-globulin fraction of the plasma and has a molecular weight of 46,000 kilodaltons. Like the growth hormone (GH), it is also a member of the hematopoietic super family, which consists of GH, EPO, granulocyte and macrophage colony-stimulating factor, interleukin 3 (IL-3), IL-4, IL-6, IL-7. All of them have similarities in their receptor structure (17, 18). It is likely that the cross-reactivity between certain growth factors exist. EPO is produced mainly in kidneys and to a lesser extent in the liver (19). Circulating EPO binds to EPO receptors on the surface of erythroid progenitors resulting in the replication and maturation to functional erythrocytes (20). In studies, its receptors have also been found in kidneys, liver, brain, the intestines, bone marrow and cardiomyocytes (6–10, 21, 22). It also shows an anabolic effect on wound healing by affecting other growth factor receptors, thus increasing fibroblast proliferation, collagen deposition, endothelial cell proliferation (angiogenesis) and the manufacture of extracellular matrixes. It has also a trophic effect on the gastrointestinal growth and development and increases cell turnover and cell migration (9). Recombinant EPO has been also used in patients awaiting an elective surgery to increase their packed red blood cell volume (23).

In the experimental study, which was done by Fatouros and examined the effect of EPO on colonic anastomose healing, it has been established that among the rats which were given EPO for 15 days preoperatively and 7 days postoperatively, the breaking strength of primary left colonic anastomosis increased by 37 % (10, 11). In the histological examination of the anastomotic area, a smaller number of inflammatory cells have been observed in the EPO group, when compared to the control group. Despite this, more fibroblast reaction and angiogenesis was observed in the EPO group when compared to the control group.

In order to study the effect of EPO on wound healing in the resection and anastomosis after a colonic obstruction, a new group was added and EPO administration was applied for 7 days, postoperatively. The healing of anastomosis was evaluated using a mechanical bursting pressure measurement, tissue hydroxyproline level, and collagen storage score during histological examination.

Although tissue hydroxyproline and the bursting pressure levels in the Group III were both higher than the control group, an

insignificant difference was found in groups without obstruction. Using these results we might say that EPO could have positive beneficial effects after the primary left colonic anastomosis, however, in comparison to Fatouros' study, this improvement was not significant.

The results of the histological evaluation showed that the histological inflammation scores of the groups where EPO was given was significantly higher compared to the control group and there was no difference between the Group I and III (EPO was administered in the Group III but not in the Group I) in terms of fibroblast proliferation scores. In addition, the high level of neovascularization score in the groups where EPO was given supported the previous findings that EPO increased neovascularization. The speed of neoangiogenesis in the EPO group could suggest the presence of EPO receptors in the endothelial cells. These receptors have previously been found in humans like in the guinea pigs (22). The collagen score of the Group III (where erythropoietin was given) was higher than the Group I with no statistical significance. A similar magnitude of increase was also seen in the hydroxyproline level and the breaking strength of the anastomosis, which led us to the conclusion that although erythropoietin definitely has positive effects on the anastomosis of the left colon, these effects are not significant.

The difference between our study and the previous study might be attributed to the timing and the dosage of EPO because they used it for a longer period (10, 11). It has been stated in most of the published studies that in the healing of the primary anastomosis performed due to the left colonic obstruction, more problems occurred and morbidity and mortality increased clinically when compared to the right colon. It has also been stated that the reasons for this difference, besides the operations, which have been performed in emergency and without preparing the patient adequately after obstruction, include various causes like the faecal load of the unprepared colon, which is the most important (24, 25). It has been shown that an intraoperative colonic lavage and a decompression have a positive effect on the anastomotic healing via decreasing faecal load in the surgical treatment of the left colonic lesion with obstruction (26). Therefore, in the groups with the left colonic obstruction, the faecal particles at the anastomosis area were cleaned by rubbing in the present study. A preoperative bowel preparation and another decompression were not performed and the rats were not left hungry for the re-operation on the next day. In that respect, one might say that an increased intraluminal faecal load due to obstruction would have a negative effect on the anastomotic healing.

However, in the group where EPO was not given (Group II), anastomotic bursting pressure and tissue hydroxyproline levels were found to be significantly lower compared to the control group. Also, neovascularisation, fibroblast proliferation and collagen storage scores were also found the lowest in the Group II during histology. Whereas in the Group IV (obstruction + resection + anastomosis + EPO) the results were completely different: the average bursting pressure and tissue hydroxyproline levels were significantly higher than in the Group II and these results were similar in the non-obstructed Group I and III. The benefi-

cial effects of EPO administration on the anastomotic healing in the obstruction group was also seen in the histological findings. In the Group IV, the average neovascularization score was higher than in the Group II. However, the fibroblast proliferation parameter in the Group IV, which was similar to the control group ($p > 0.05$), was significantly better than in the Group II ($p < 0.05$). The mean collagen storage score in the Group IV was higher than in the Group II and the control group. In the obstruction group, EPO administration was found to be beneficial.

The question that should be asked is why and how erythropoietin has a positive effect on colonic anastomosis with obstruction but not on colonic anastomosis without obstruction. In this study; the Group II had the worst anastomotic healing. In this group, neovascularization, fibroblast proliferation and collagen synthesis were all found to be significantly lower but inflammation was significantly higher than in the others. In the both obstruction + anastomosis groups, the inflammation rate was similar, but neovascularization, fibroblast proliferation and collagen storage level were significantly better. The inflammation period is the initial phase of the healing process. The most important factors, which prolong the inflammation period, are the presence of foreign body and bacterial inoculation in the wound. When there is an infection, the completion of the healing process is impossible.

Bacterial overload and increased faecal content in the proximal part of the obstructed colon, local contamination during resection and anastomosis might all be responsible for the higher rates of inflammation and complications (24–30).

These observations indicate that the positive effects of EPO on the growth factor in wound healing must be seen in higher inflammation rates. Thrombocytes, lymphocytes and macrophages are the cells that take place in the inflammatory cascade. As we know, these cells release a lot of growth factors that are polypeptides and have mitogenic, chemotactic and cell movement stimulant functions. They attack target cell receptors. It is also known that they activate their functions by cross reactions at the receptor level (31–33). EPO receptors have been found in rats and human endothelial cells (23). It is believed that EPO interacts with endothelial cell receptors and stimulate healing process by increasing neovascularization.

The significantly increased neovascularization scores in the groups, which have been given EPO, support the previous findings (10, 11). Neovascularisation alone does not explain the positive effects of EPO on the anastomotic healing in the resection + anastomosis group after a colonic obstruction.

In conclusion, we failed to find any direct and evident effect of erythropoietin on the healing of the left colonic anastomosis in the presented study. On the other hand, it was found that erythropoietin might prevent negative effects of obstruction on the healing by increasing bursting pressure and tissue hydroxyproline levels.

Comparison with other studies

Though this study's subject should be an important issue of presenting surgical management, a large scale of basic research

has yet not been done. An experimental study on rats was done by Munevver Moran, M Mahir Ozmen and A Polat Duzgun by the year 2006 and 2007, which was published on 15th May, 2007 in World Journal of Emergency surgery, which could not give an exact solution or positive outcome. Although, in many points of view, our findings are dissimilar with that publication, but the net outcomes are very similar to their paper.

Limitations of this study

In our study, we did not find any positive, fruitful role of erythropoietin in such a satisfactory relation that we anticipated before the trial. We used 40 guinea pigs in the study and it seems that the sample size was not adequate. Munevver Moran, M Mahir Ozmen and A. Polat Duzgun also used 40 rats for their laboratory study and had both similar and dissimilar results compared to our study. So, perhaps there may be a variation among the species to such concern.

Indeed, we really need more practical and basic clinical studies to depict the image in full scale to combat such a crucial threat in the surgical management.

References

1. Munevver Moran, M Mahir Ozmen, A Polat Duzgun et al. World journal of emergency surgery; the effect of erythropoietin on healing of obstructive vs. nonobstructive left colonic anastomosis: an experimental study; 15 May 2007; 2: 13.
2. Hesp WL, Lubbers EJ, de Boer HH, Hendriks T. Anastomotic insufficiency in small bowel surgery: incidence and treatment. *Langenbecks Arch Chir* 1986; 368: 105–111.
3. Schrock TR, Deveney CV, Dunphy JE. Factor contributing to leakage of colonic anastomoses. *Ann Surg* 1973; 177: 513–518.
4. Ravo B. Colorectal anastomotic healing and intracolonic bypass procedures. *Surg Clin North Amer* 1998; 68: 1267–1294.
5. McGrath MH. Peptide growth factors and wound healing. *Clin Plast Surg* 1990; 17: 421–432.
6. Herndon DN, Nguyen TT, Gilpin DA. Growth factors. local and systemic. *Arch Surg* 1993; 128: 1227–1233.
7. Wald MR, Borda ES, Sterin-Borda L. Mitogenic effect of erythropoietin on neonatal rat cardiomyocytes: signal transduction pathways. *J Cell Physiol* 1996; 167: 461–468.
8. Juul SE, Joyce AE, Zhao Y, Ledbetter DJ. Why is erythropoietin present in human milk? Studies of erythropoietin receptors on enterocytes of human and rat neonates. *Pediatr Res* 1999; 46: 263–268.
9. Juul SE, Ledbetter DJ, Joyce AE, Dame C, Christensen RD, Zhao Y, DeMarco V. Erythropoietin acts as a trophic factor in neonatal rat intestine. *Gut* 2001; 49: 182–189.
10. Fatouros MS, Vekinis G, Bourantas KL, Mylonakis EP, Scopeliotou AS, Malamou-Mitsis VD, Kappas AM. Influence of growth factors erythropoietin and granulocyte macrophage colony stimulating factor on mechanical strength and healing of colonic anastomoses in rats. *Eur J Surg* 1999; 165: 986–992.
11. Fatouros MS, Dalekos GN, Mylonakis E, Vekinis G, Kappas AM. Alterations in body weight, breaking strength, and wound healing in

wistar rats treated pre-and postoperatively with erythropoietin or granulocyte macrophage-colony stimulating factor: Evidence of a previously unknown anabolic effect of erythropoietin? *J Lab Clin Med* 1999; 133: 253—259.

12. Jiborn H, Ahonen J, Zederfeldt B. Healing of experimental colonic anastomoses. Bursting strength of the colon after left colon resection and anastomosis. *Amer J Surg* 1978; 136: 587—594.

13. Phillips JD, Kim CS, Fonkalsrud EW, Zeng H, Dindar H. Effects of chronic corticosteroids and vitamin A on the healing of intestinal anastomoses. *Amer J Surg* 1992; 163: 71—77.

14. Woessner JF Jr. The determination of hydroxyproline in tissue and protein samples containing small proportions of this imino acid. *Arch Biochem Biophys* 1961; 93: 440—447.

15. Hunt TK, Mueller RV. Wound healing. In *Current surgical diagnosis and treatment* 10th edition. Edited by: Way LW. New Jersey. Appleton and Lange; 1994: 80—93.

16. Ehrlich HP, Tarver H, Hunt TK. Effects of vitamin A and glucocorticoids upon inflammation and collagen synthesis. *Ann Surg* 1973; 177: 222—227.

17. Bazan JF. Haemopoietic receptors and helical cytokines. *Immunol Today* 1990; 11: 350—354.

18. Tabbara IA. Erythropoietin. Biology and clinical applications. *Arc Intern Med* 1993; 153: 298—304.

19. Jacobson LO, Goldwasser E, Fried W, Plzak L. Role of the kidney in erythropoiesis. *Nature* 1957; 179: 633—634.

20. D'Andrea AD, Koo JW. Structure and function of the erythropoietin receptor in stable erythropoietin-dependent transfectants. *Contrib Nephrol* 1991; 88: 48—56.

21. De Anagnostou A, Liu Z, Steiner M, Chin K, Lee ES, Kessimian N, Noguchi CT. Erythropoietin receptor mRNA expression in human endothelial cells. *Proc Natl Acad Sci USA* 1994; 91: 3974—3978.

22. Dame C, Fahrenstich H, Freitag P, Hofmann D, Abdul-Nour T, Bartmann P, Fandrey J. Erythropoietin mRNA expression in human fetal and neonatal tissue. *Blood* 1998; 92: 3218—3225.

23. Goodnough LT, Rudnick S, Price TH, Ballas SK, Collins ML, Crowley JP, Kosmin M, Kruskall MS, Lenes BA, Menitove JE et al. Increased preoperative collection of autologous blood with recombinant human erythropoietin therapy. *N Engl J Med* 1989; 26 (321): 1163—1168.

24. Törnqvist A, Blomquist P, Jiborn H, Zederfeldt B. Anastomotic healing after resection of left colon stenosis: effect on collagen metabolism and anastomotic strength. An experimental study in rats. *Dis Colon Rectum* 1990; 33: 217—221.

25. Törnqvist A, Forsgren A, Jiborn H, Zederfeldt B. Bacterial load and inflammatory reaction in the bowel wall after colonic obstruction. An experimental study in rats. *Eur J Surg* 1991; 157: 539—542.

26. Smith SRG, Connolly JC, Gilmore OJA. The effect of faecal loading on colonic anastomotic healing. *Br J Surg* 1983; 70: 49—50.

27. Naraynsingh V, Rampaul R, Maharaj D, Kuruvilla T, Ramcharan K, Pouchet B. Prospective study of primary anastomosis without colonic lavage for patients with an obstructed left colon. *Brit J Surg* 1999; 86: 1341—1343.

28. Saadia R, Schien M. The place of intraoperative antegrade colonic irrigation in emergency left-sided colonic surgery. *Dis Colon Rectum* 1989; 32: 78—81.

29. Jonsson K, Jiborn H, Zederfeldt B. Healing of anastomoses after obstruction of small intestine. *Surg Gynec Obstet* 1988; 167: 324—330.

30. Nyhus ML. Intestinal obstruction. In *Shackelford's Surgery of the Alimentary tract* Volume 5. 3rd edition. Chapter 23 Edited by: Zuidema GD. Philadelphia: WB Saunders; 1991: 372—413.

31. Frank J. Thornton and Adrian Barbul. Healing in the Gastrointestinal Tract. *Surg Clin North Amer* 1997; 77 (3): 549—573.

32. Bruce A. Mast: Healing in other tissues. *Surg Clin North Am* 1997; 77 (3): 529—547.

33. Olsson I, Gullberg U, Lantz M, Richter J. The receptors for regulatory molecules of hematopoiesis. *Euro J Haematol* 1992; 48: 1—9.

Received January 4, 2009.

Accepted May 28, 2009.