

CASE REPORT

Absence of infrarenal inferior vena cava is not a congenital abnormality

Banu Alicioglu¹, Mustafa Kaplan², Turan Ege³Trakya University Medical Faculty Radiology Department, Edirne, Turkey. banualicioglu@trakya.edu.tr

Abstract: The absence of inferior vena cava (IVC) is one among infrequent subtypes of IVC abnormalities that are rarely seen in general population. The absence of IVC involves either that of entire IVC or that of infrarenal segment. These two entities are relatively similar but their etiopathogeneses are still controversial. The absence of the entire IVC is thought to be a result of an embryologic disorder, whereas perinatal thrombosis is hypothesized to lead to the development of absent infrarenal IVC, thus the latter is a developmental disorder and the former occurs due to embryologic disorder. We report an adult man with renal-infrarenal absence of IVC, as well as missing common iliac veins. He clinically presented with extensive varicose collateral circulation on the thoracoabdominal wall, right varicocele and severe varices on lower limbs. Calcifications of adrenal glands indicate a hematologic disorder during perinatal period. The etiopathogenesis of this unusual abnormality is emphasized in this case report (Fig. 5, Ref. 10). Full Text (Free, PDF) www.bmj.sk.

Key words: vena cava, inferior, abnormality, urogenital

Since the advent of widespread usage of cross-sectional imaging, congenital anomalies of IVC and its tributaries have become more frequently recognized as an incidental finding in asymptomatic patients. The absence of the infrarenal IVC is the most severe and unfrequent abnormality of congenital anomalies of IVC. Clinically, the patients manifest with lower-extremity varicose veins, stasis dermatitis, idiopathic and recurrent deep venous thrombosis since adolescence. Retroperitoneal hemorrhage as a result of ruptured collateral vessels or mass effect of the paraspinal collateral circulation are the other reported clinical presentations. Venous drainage of lower extremities and abdomen is supplied by anterior abdominal veins, ascending lumbar veins and paravertebral venous plexus vessels. From there, the flow proceeds to the hemiazygous vein and through the left superior intercostal vein to the left innominate vein.

We report a unique case referred with right varicocele beside extensive varices on lower limbs, abdominal and thoracic wall and paraspinal collaterals. The presence of calcifications in adrenal glands makes us suggest that IVC hypoplasia has developed as a consequence of perinatal thrombosis or hemorrhage.

Case report

A 33-year-old man, referred to urology clinic because of pain and swelling in right testicle. Physical examination revealed grade

III of varicocele; multiple large varicose dilatations in lower limbs, anterior and lateral wall of the thorax as well as on the abdomen were relevant (Fig. 1). He claimed that he had suffered from these varices since his childhood and was treated for recur-

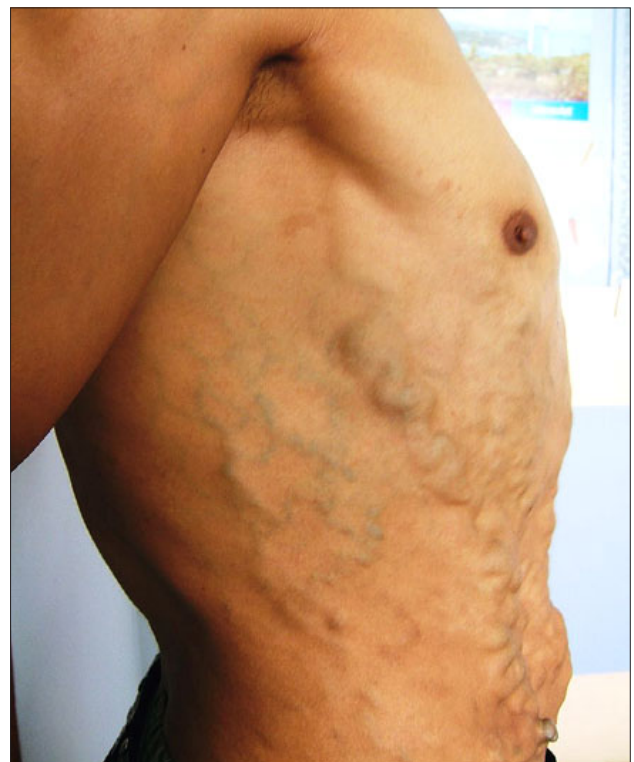


Fig. 1. Extensive varicose dilatations of thoracodorsal collaterals is seen.

¹Trakya University Medical Faculty Radiology Department, Edirne, Turkey, ²Trakya University Medical Faculty Urology Department, Edirne, Turkey, and ³Trakya University Medical Faculty Cardiovascular Surgery Department, Edirne, Turkey

Address for correspondence: Banu Alicioglu, Fatih mah. 4. cad. 43. sok. Ziraatiler Sitesi B Blok no: 8, 22030, Edirne, Turkey.
Phone: +90.2842363089, Fax: +90.2842352730

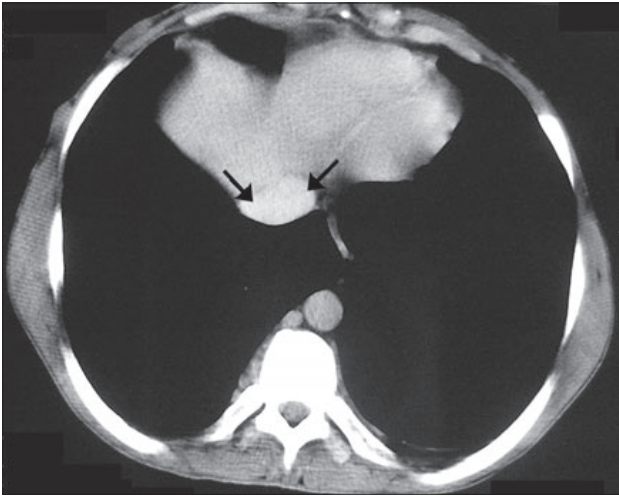


Fig. 2. Abdominal computed tomography scan. Normal caliber suprahepatic segment of IVC.

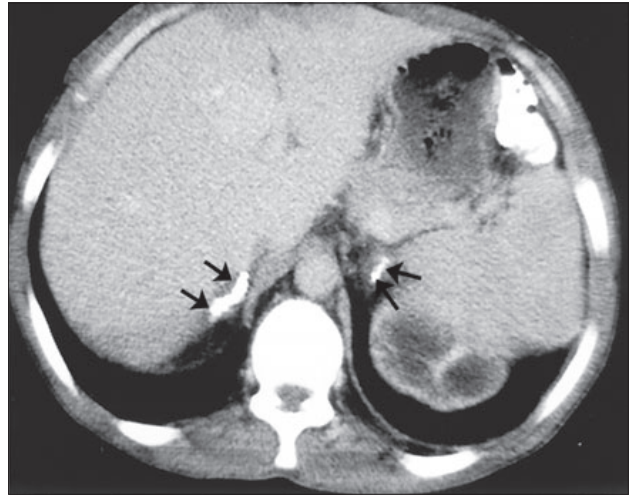


Fig. 3. Calcifications of the bilateral adrenal glands without evidence of mass (arrows).



Fig. 4. Parenchymal atrophy with mild dilatation of the collecting system of both kidneys. Hypoplastic renal segment of IVC (short thick arrow) with collaterals, and prominent hemiazygos vein (long thin arrow). Collaterals on abdominal wall are also seen (small arrows).

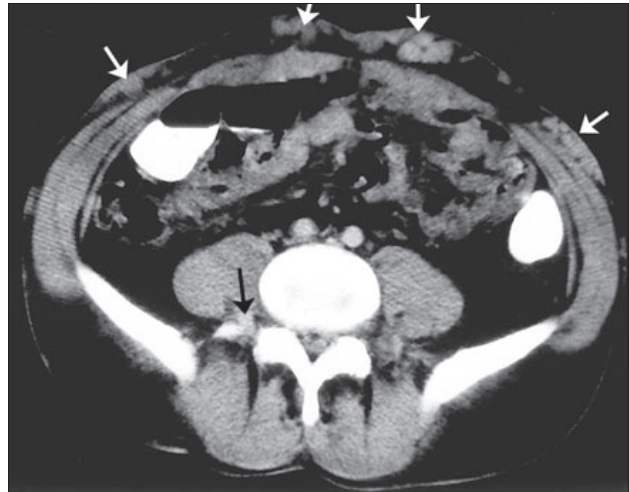

Fig. 5. Collateralization of paraspinal vein seen on the right, and massive varices of superficial collateral veins at abdominal wall.

rent deep venous thrombosis episodes. Abdominal contrast enhanced computed tomography depicted the absence of renal and infrarenal IVC as well as both common iliac veins. Some small prevertebral and paravertebral collaterals as well as superficial collateral veins in the abdominal wall were extensively varicose, tortuouse and dilated. Bilateral calcification of adrenal glands without mass attracted our attention. Parenchymal atrophy and mild dilatation of the collecting system of both kidneys was marked, but no stone or external compression was detected. (Figs 2–5). Blood urea nitrogen and creatinin levels were in normal limits.

Discussion

The embryology of IVC is well-known; it includes formation, regression and anastomosis of three sets of longitudinal

paired veins: In order of appearance, they are the postcardinal, subcardinal and supracardinal veins. The normal IVC converts to a unilateral right-sided system consisting of four segments, namely of hepatic, prerenal, renal and postrenal segments. The hepatic IVC develops by coalescence of hepatic sinusoids, which are derived from the vitelline vein. The right subcardinal vein develops into the suprarenal segment of IVC thus forming an anastomosis with the hepatic segment. The renal segment develops from anastomoses between the subcardinal and supracardinal veins. The postrenal IVC is formed by confluence of the common iliac veins, the caudal extremity of the right postcardinal vein, the right postcardinal-supracardinal anastomosis, a part of the right supracardinal vein, and the right supracardinal-subcardinal anastomosis.

The absence of IVC includes two entities: Absence of the entire IVC and absence of infrarenal IVC with preservation of

the suprarenal segment. Etiopathogeneses of these two entities are controversial, completely different etiologies were proposed by several authors

It is clear that the failure of proper formation of all these three paired venous systems results in the absence of the entire IVC, whereas the absence of the infrarenal IVC implies a failure in the development of the postcardinal and supracardinal veins. Firstly, d'Archambeau and Milner proposed the theory of IVC thrombosis in intrauterine or perinatal period based on the fact that a single embryological breakdown cannot explain infrarenal IVC absence. This thesis is supported by McDonald and Ramanathan's works. The study of McDonald et al showed three cases with thrombus in IVC, which subsequently became invisible on venographies in the following period. Ramanathan reported a 12 year-old female patient with infrarenal IVC absence whose medical records indicated that she had been treated for thrombosis of IVC and right renal vein. The absence of associated congenital anomalies in theirs, as well as in our case supports the assumption of developmental disorder.

The differential diagnosis of bilateral adrenal calcification includes neonatal sepsis and hemorrhage in the absence of tumor. Adrenal hemorrhage and renal vein thrombosis are two distinct vascular entities but often occur together in perinatal period. Renal vein thrombosis may be accompanied by IVC. Neonatal hemorrhage is more commonly seen on the left because the left adrenal vein drains directly into left renal vein. However when IVC is thrombosed, both adrenals are affected. Nonetheless, bilateral adrenal hemorrhage with RVT in fetus is very rare; there are only two cases reported in literature. Parenchymal atrophy of both kidneys in our case suggests to be a venous infarction sequela due to the extent of thrombi in small venules. The case is unique by being presented with varicocele, the fact of which suggests drainage disturbance of the gonadal vein to IVC. Unfortunately, since the patient refused venography, the vascular pathways of venous circulation could not be mapped.

As a conclusion, cases with infrarenal IVC absence are extremely rare in literature. This case presents radiologic evidence

of perinatal thrombosis. Since the mentioned abnormality is a developmental disorder, not an embryological one, the term 'absence' of infrarenal IVC is a misnomer. In such a case, the term 'hypoplasia' of infrarenal IVC is proposed by the authors.

References:

1. Bass JE, Redwine MD, Kramer LA, Huynh PT, Harris JH Jr. Spectrum of congenital anomalies of the inferior vena cava: Cross-sectional imaging findings. *Radiographics* 2000; 20: 639–652.
2. Bass JE, Redwine MD, Kramer LA, Harris JH Jr. Absence of the infrarenal inferior vena cava with preservation of the suprarenal segment as revealed by ct and mr venography. *Amer J Roentgenol* 1999; 172: 1610–1612.
3. Artico M, Lorenzini D, Mancini P, Gobbi P, Carloia S, David V. Radiological evidence of anatomical variation of the inferior vena cava: Report of two cases. *Surg Radiol Anat* 2004; 26: 153–156.
4. Balzer KM, Pillny M, Luther B, Grabitz K, Sandmann W. Spontaneous rupture of collateral venous aneurysm in a patient with agenesis of the inferior vena cava: A case report. *J Vasc Surg* 2002; 36: 1053–1057.
5. Milner LB, Marchan R. Complete absence of the inferior vena cava presenting as a paraspinous mass. *Thorax* 1980; 35: 798–800.
6. Kieran S, Neary P, Owens A, Mehigan D. Inferior vena cava agenesis with paravertebral muscle collateralisation. *EJVES Extra* 2004; 8: 127–129.
7. Ramanathan T, Hughes TM, Richardson AJ. Perinatal inferior vena cava thrombosis and absence of the infrarenal inferior vena cava. *J Vasc Surg* 2001; 33: 1097–1099.
8. McDonald P, Tara R, Gilday D, Reilly BJ. Some radiological observations in renal vein thrombosis. *Amer J Roentgenol* 1974; 120: 368–388.
9. Brill PW, Jagannath A, Winchester P, Markisz JA, Zirinsky K. Adrenal hemorrhage and renal vein thrombosis in the newborn: MR imaging. *Radiology* 1989; 170: 95–98.
10. Lau KK, Garcia EF, Kwan WY, Albrecht L, Stein-Wexler R. Bilateral renal venous thrombosis and adrenal hemorrhage: Sequential prenatal us with postnatal recovery. *Pediatr Radiol* 2007; 37: 912–915.

Received September 17, 2008.

Accepted January 22, 2009.