

## CLINICAL STUDY

## Devastating injury of the groin with vascular lesion

Babala J<sup>1</sup>, Cingel V<sup>1</sup>, Hargas M<sup>2</sup>, Sefranek V<sup>3</sup>, Horn F<sup>1</sup> Trnka J<sup>1</sup>*Department of Paediatric Surgery, Children's University Hospital, Bratislava, Slovakia.*

jozef.babala@post.sk

**Abstract:** A 13-year old girl suffered an injury of the left inguinal region in October 2002. The mechanism of the injury was a fall off a merry-go-round with subsequent trailing by the iron frame, which resulted in devastation of the soft tissues and vessels of her left groin. The patient was transported to the Department of Paediatric Surgery in a state of haemorrhagic shock. A part of the iron frame was still sticking out of her groin. Emergent surgery and haemostasis was followed by reconstructive vascular surgery. Vascular ischaemic-reperfusion syndrome appeared 8.5 hours after the injury. A second episode of haemorrhagic shock developed on the 6th post-operative day, after a dislodgement of an arterial thrombus from a small artery, which was not obvious during the surgery. The situation required emergent wound exploration and surgical control of the bleeding. A third episode of haemorrhagic shock developed on the 9th post-operative day, after an excessive administration of heparin. This time no surgical bleeding was detected during wound exploration. The last episode of haemorrhagic shock appeared 6 months later, during the patient's menarche. She was ashamed to tell her parents about her heavy bleeding for several days.

Authors of this article conclude that it is not necessary to increase the dose of Heparin above 20 mcg/kg/hour, even though the value of aPTT is not as high as we would expect. We should expect also the possibility of severe bleeding due to menarche on the anticoagulant therapy in adolescent female patients. Authors also consider both arterial and deep venous reconstructions to be adequate methods of treatment in case of extensive devastating injury of the groin region in the adolescent period (Fig. 5, Ref. 5). Full Text (Free, PDF) [www.bmj.sk](http://www.bmj.sk).

Key words: vascular trauma in childhood, haemocoagulation problems.

Firstly, the description of a devastating injury with vascular lesion of the left inguinal region in a 13-year old female patient, and her treatment. Secondly, the analysis of the development, treatment and outcome of the haemorrhagic shock that appeared immediately after the injury, then reappeared on the 6th, and 9th post-operative days, as well as 6 months after the injury.

**Methods**

Retrospective analysis of a 3-year period after the injury. The authors would like to emphasise the importance of correlation between the use of anticoagulant therapy and other factors connected with the development of haemorrhagic shock.

The dose of the anticoagulant therapy has been correlated with the results of laboratory tests and patient's clinical condition.

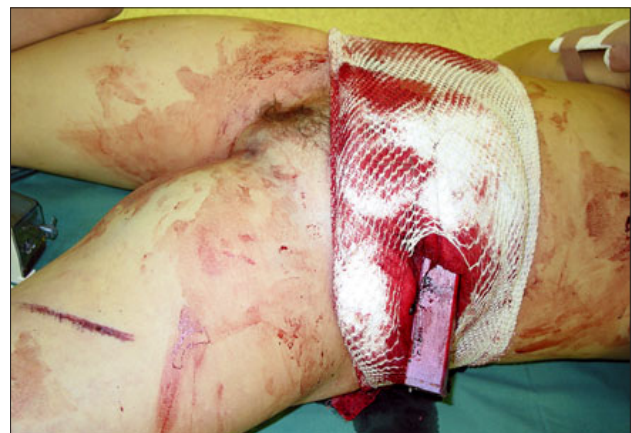<sup>1</sup>Department of Paediatric Surgery, Children's University Hospital, Bratislava, Slovakia, <sup>2</sup>ITU, The Manor Hospital, Oxford, UK, and <sup>3</sup>Clinic of Vascular Surgery, The National Institute of Cardiovascular Diseases, Bratislava, Slovakia

**Address for correspondence:** J. Babala, MD, PhD, Dept of Paediatric Surgery, Children's University Hospital, Limbova 1, SK-833 40 Bratislava, Slovakia.  
Phone: +421905268020

**Results**

A 13-year old female (body weight 50 kg) suffered an injury of the left inguinal region with an excessive devastation of soft tissues and vessels in October 2002.

The mechanism of injury was a fall off a merry-go-round and subsequent trailing of the patient by the iron frame, causing devastation of the soft tissues and vessels of her left groin.



**Fig. 1.** Injury of left groin caused by iron frame of a merry-go-round as a result of being trailed by the latter.

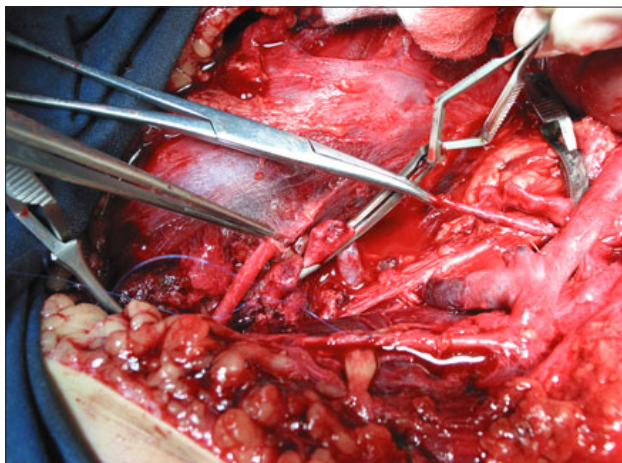


Fig. 2. Devastation of the soft tissues and vessels of left groin.

The patient was transported to the Department of Paediatric Surgery in a state of haemorrhagic shock (BP: 80/45 mmHg, Hct: 0.16; Hb: 3.9 g/dl; Ery: 1.76). Haemodynamic resuscitation commenced immediately during her transfer into the operating theatre, where the extraction of the iron frame, still sticking out of her groin was performed and emergent haemostasis achieved (Figs 1 and 2). Total amount of 10 units of blood, 4 units of FFPs, 3 litres of colloids and electrolytes together with inotrope support were administered perioperatively. After the stabilisation of patient's condition, direct vascular reconstruction was performed.

An interposition of the devastated femoral artery using a dacron prosthesis between the common femoral artery and superficial femoral artery in an end-to-end fashion (Fig. 3). Venous flow was secured also using a Dacron prosthesis, which connected the distal end of femoral vein (end-to-end anastomosis) with the external iliac vein by the end-to-side anastomosis. (We used a dacron prosthesis of 8 cm in size and 7 mm in length).

On the 6th post-operative day the second episode of haemorrhagic shock developed, namely after the dislodgement of an arterial thrombus from a small artery, which was not obvious at the time of the primary operation. We suppose that the dislodgement of arterial thrombus was caused by anticoagulant therapy. (BP: 68/45 mmHg, CVT: 3 mmHg, Hct: 0.15, Hb: 5.3 g/dl, Ery: 1.91). The patient's stabilisation was achieved by subsequent surgical haemostasis and evacuation of the haematoma from the retroperitoneal space within inguinal region.

In spite of elevating the Heparin dose up to 30 mcg/kg/hour it was not possible to raise the aPTT level 2–3 times above the normal level, and the value of aPTT remained 1.5-fold the normal value.

The third episode of haemorrhagic shock appeared on the 9th post-operative day (hypotension, decrease in CVP, tachycardia, Hct 0.16, Hb 5.4 g/dl, Ery 1.94). No surgical bleeding was detected during wound exploration.

Diffuse bleeding was stopped by insertion of fibrin foam into the operating wound.

Adjustment of the medical treatment was necessary. We restarted Heparin infusion, followed by LMWH treatment 24 hours

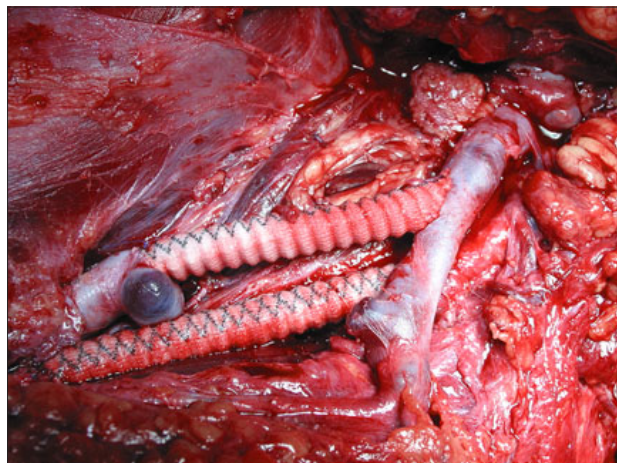


Fig. 3. Arterial and venous reconstruction by Dacron prosthesis.

later. The patient's condition returned to normal and intensive physiotherapy was started. LMWH was replaced by oral anticoagulant Warfarin (INR-2,08...).

The next episode of haemorrhagic shock that occurred six months after the injury was very surprising. Since menarche appeared, the patient was ashamed to tell her parents about her bleeding for nine days. INR index was 3.45 at that time. (Hct 0.17, Hb 6.2 g/dl, Er 2.07) The bleeding was stopped by hormonal curettage, and anticoagulant therapy was changed. Warfarin was replaced by Aspirin and Sulodexide (an oral anticoagulant targeting the factor X). The treatment was finished 1 year after the injury.

The movement of the patient's lower extremity was restored almost up to its full range. The only remaining 10-degree deficit in dorsal flexion of the foot caused by ischemic changes in the anterior tibial muscle is not visible during normal activity.

## Discussion

Damage of the tissues was very extensive; synthetic prosthetic material for arterial and venous reconstruction in a non-aseptic traumatized area was used. We decided to reconstruct the venous flow because of extensive damage of collateral drainage system bringing about a high risk of severe venous insufficiency. Our aim was to restore the venous drainage in patient's leg in spite of high risk of thrombosis. The compartment syndrome appeared 8.5 hours after the injury. Fasciotomy above the anterior tibialis muscle and muscles of the calf was performed to influence its progression. Doppler ultrasound study of the venous graft confirmed its patency, even 3 years after the injury (Figs 4 and 5).

Klinker DB et al (3) analysed paediatric vascular injuries, including the patterns of injury, morbidity and mortality with results that extremities were affected in 67 %, amputation was required in 10.7 %, and the overall mortality was 9.7 %.

Haemorrhage continues to be one of the leading causes of death after trauma (5). Schmal H et al (4) analysed three cases, and established a treatment algorithm. At first, life-saving steps

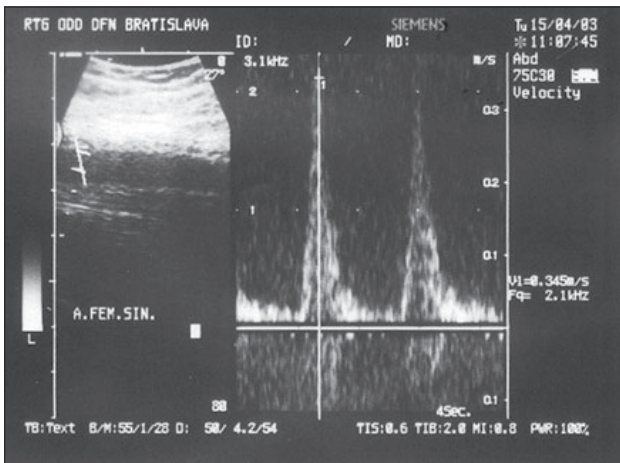


Fig. 4. Ultrasound of arterial flow.

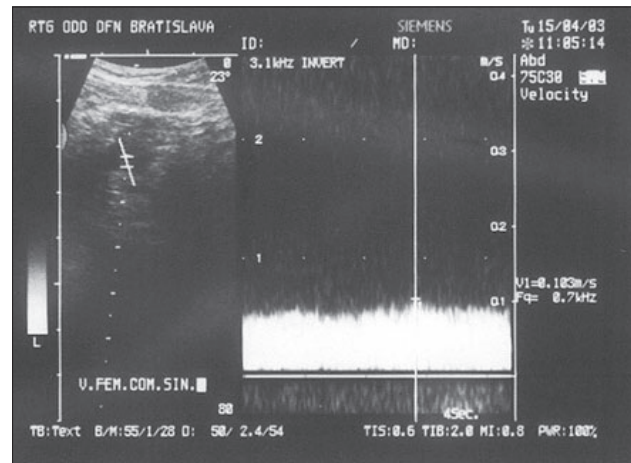


Fig. 5. Ultrasound of venous flow.

have to be taken, and accompanying injuries should be treated thereafter. In order to obtain best results, Bettili and coworkers (2) stress the importance of early revascularization by end-to-end suturing in case of short lesions, and by using autologous tissue in case of longer lesions. Furthermore, authors emphasize the importance of repairing venous injuries.

Our reason for choosing Heparin anticoagulation in the acute phase of treatment was based on the advantage of its titratability according to activated partial thromboplastin time (aPTT), and availability of its antidote Protamine sulphate in case of its overdose. In our opinion, it is not so easy to control the effect of low molecular Heparins (like Nandroparine etc.) and therefore the neutralizing of their effect might be more difficult.

In our case, the dose of Heparin was not in correlation with both, the value of aPTT and the patient's haemocoagulation status. We believe that the change in physiological response was caused by massive blood and fluid replacement during intensive care of three consecutive episodes of haemorrhagic shock during the nine-day period after injury. As long as the clotting and other factors were not in physiological range, we could not expect precise results.

Since trauma patients are susceptible to early development of coagulopathy, we recommend Heparin resistance to be evaluated with reservation accordingly to Thieu et al (5). Hypothermia, acidosis, and dilution during intensive care can worsen the present coagulopathy and perpetuate bleeding. Routinely used clotting screen parameters failed to describe this state accurately (5).

The bleeding during menarche was not so severe. However, the danger was in its intensity and long-term character. Contemporarily, INR index rose up to value of 3.45 on the same dose of Warfarin. The patient was ashamed to confide to her parents about her bleeding for 9 days. Despite the fact that her twin sister had had her menarche only a few months earlier, we did not warn the patient about the possibility of excessive bleeding during menarche under anticoagulant therapy. In a case like this, co-operation of gynaecologist, haematologist and surgeon is highly recommended. In a retrospective review of children and adolescents

(103 patients), 29.1 % were managed by paediatric surgeons, 38.8 % by extremity specialists, 17 % by vascular surgeons, 5.8 % by neurosurgeons, and 9.3 % by others (3). At our department of Paediatric Surgery, Children's University Hospital, the patient was under the care of paediatric surgeons specialized in vascular reconstructive surgery, Babala J et al (1).

## Conclusion

Authors conclude that it is not necessary to increase the dose of Heparin above 20 mcg/kg/hour, even though the value of aPTT is not as high as we would expect. In adolescent female patients, we should expect the onset of menarche. Therefore, it is unavoidable to instruct girls and their parents about the risk of severe bleeding in patients on anticoagulant therapy.

In devastating injuries of the groin region during adolescent period, we consider deep venous reconstruction to be an adequate method because it is not possible to rely on sufficiency of the collateral circulation only.

## References

1. Babala J, Horn F, Sykora L, Cingel V, Vidiscak M, Haviar D, Siman J. Supracondylar fractures of the humerus and disorders of circulation. *Rozhl Chir* 2001; 80: 545—548.
2. Bettili G, Bianchi S, Camoglio FS, Piovesan P, Adami CA. Vascular traumatic lesions in childhood and adolescence. *Minerva Cardioangiolog* 1996; 44: 155—160.
3. Klinker DB, Arca MJ, Lewis BD, Oldham KT, Sato TT. Pediatric vascular injuries: patterns of injury, morbidity, and mortality. *J Pediatr Surg* 2007; 42: 178—183.
4. Schmal H, Klempert C, Haag C, Bonnaire F. Complex pelvic injury in childhood. *Unfallchirurg* 2002; 105: 748—754.
5. Tieu BH, Holcomb JB, Schreiber MA. Coagulopathy: Its Pathophysiology and Treatment in the Injured Patient. *World J Surg* 2007; Epub, PMID 17426904.

Received September 23, 2008.

Accepted January 22, 2009.