

CASE REPORT

Spontaneous regression of complex cystic renal mass of Bosniak class IV – a rare phenomenon

Weibl P^{1,2}, Lutter I¹, Romancik M¹, Karwandgar M¹, Kollarik B¹, Obsitnik M¹

Department of Urology, University Hospital, Bratislava, Slovakia. pweibl@yahoo.com

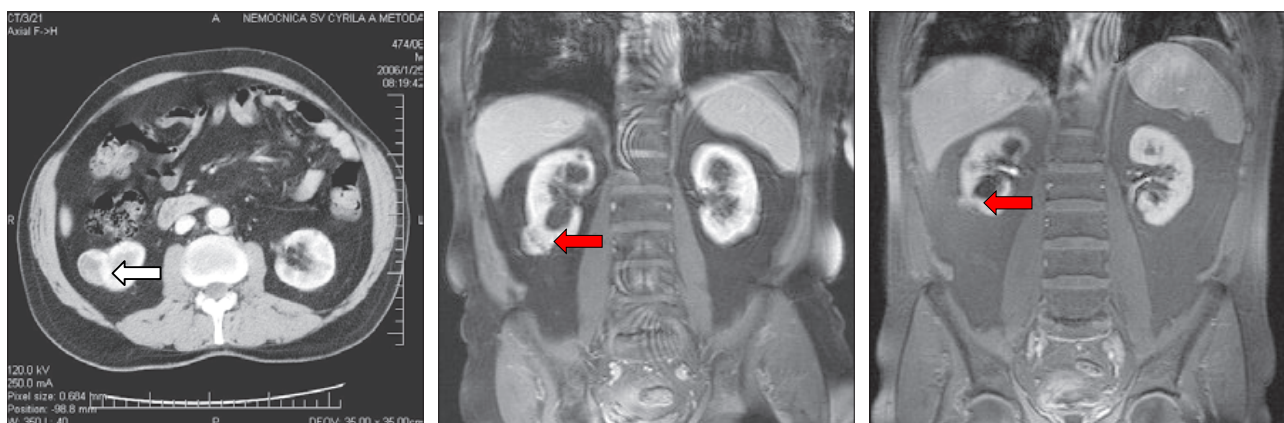
Abstract: Spontaneous remission of simple renal cyst or complex renal cyst Bosniak III or IV class is a rare phenomenon. Our report describes a spontaneous partial regression of complex renal cyst Bosniak IV during the observation of complex cystic renal masses. A 66 year old male high risk patient (ASA score 3–4) refused all surgical intervention and was suggested for active surveillance strategy. We observed spontaneous partial regression of the complex cyst in this patient. To our knowledge this is the first report of spontaneous partial regression of complex renal cyst Bosniak IV class (Fig. 3, Ref. 5). Full Text (Free, PDF) www.bmj.sk.
Key words: spontaneous regression, complex cystic renal mass, Bosniak class, urology.

Case report

A 66-year-old male patient was referred to our clinic because of US finding of a complex renal cyst of the right kidney with hyperechoic content. The lesion was detected accidentally. It appeared as a cortical complex cystic mass of the right kidney. Patient underwent a CT examination, which revealed a complex renal cystic lesion of Bosniak III class with thickened wall. The thickened part of the cystic wall had attenuation numbers on pre-contrast CT-scan 45HU and on nephrographic phase images

95HU. The lesion measured 40 mm in its largest diameter (Fig. 1). Patient was asymptomatic, without microscopic haematuria and normal with levels of hemoglobin and serum creatinine. The patient is treated for arterial hypertension, he is also regularly monitored by cardiologist because of low heart ejection-fraction and cardiomyopathy. ASA score of the patient was III–IV. He also refused any kind of surgical intervention, which was discussed with him.

We have subsequently enrolled him in our subset of patients in a prospective study focused on observation of complex renal



Figures 1, 2, 3. CT of the complex renal cyst of the right kidney of Bosniak III class (white arrow); MRI correlation within 6 months, the lesion was upgraded into Bosniak IV class (red arrow); control MRI after 30 months of observation – renal cyst has regressed (red arrow).

¹Department of Urology, University Hospital, Bratislava, Slovakia, and
²Euromedix limited, Bratislava, Slovakia

Address for correspondence: P. Weibl, MD, PhD, Dept of Urology, University Hospital, Comenius University, Antolska 11, SK-851 07 Bratislava 5, Slovakia.

cystic masses of Bosniak II, IIF, III and IV classes. In this prospective study, 35 renal cystic lesions (Bosniak II(23); IIF(7); III(2) and IV(3)) were included and observed. Lesions measured at least 2 cm in diameter (median 3.6 cm). All patients were asymptomatic, without microscopic haematuria, mean patients'

age was 59 years. CT/MRI scans were performed at 6 monthly and annual intervals. Our policy is that every patient in the follow-up protocol undergoes MRI correlation that is done between 21 to 180 days after the first CT examination. Between these periods, any progression changes should be minimal. The mean follow-up period was 37 months. After 6 months of observation, the patient underwent MRI, which has led to an upgrade of the lesion into the Bosniak IV category (Fig. 2). Within 30 months, the patient underwent another MRI, which revealed a spontaneous partial regression of the cystic mass of the left kidney (Fig. 3). Patient's history was uneventful; no trauma; surgical intervention or any other factors were excluded.

Discussion

Spontaneous or traumatic ruptures of simple renal cysts have been documented in the literature so far (1).

Observation of complex renal cystic masses of Bosniak class IIF/III/IV is an alternative option to surgical therapeutic management (2, 3, 4). Despite the lack of data based on long-term follow-up and very low potential risk of developing a metastatic disease (5), 3 scenarios have to be considered as follows: 1) spontaneous rupture of cystic mass with intracapsular or retroperitoneal spillage of cystic fluid (where malignant cells could theoretically be present) with uneventful course; 2) spontaneous regression with rupture of the cyst followed by spillage and haemorrhage presented as symptomatic subcapsular retroperitoneal hematoma or rupture into the pyelocaliceal system of the kidney; or 3) spontaneous regression of the entire mass without any spillage or haemorrhage.

Observation of surgical complex cystic lesions is an option in high-risk and elderly patients, however studies with long-term follow-up are necessary. To our knowledge, this is the first report of a spontaneous partial regression of a complex renal cyst of Bosniak class IV.

References

1. **Papanicolaou N, Pfister RC, Yoder IC.** Spontaneous and traumatic rupture of renal cysts: Diagnosis and outcome. *Radiology* 1986; 160: 99–103.
2. **Isreal GM, Bosniak MA.** Follow-up CT of moderately complex cystic lesions of the kidney (Bosniak category IIF). *Amer J Radiol* 2003; 181: 627–633.
3. **Volpe A, Jewett MAS.** The natural history of small renal masses. *Urology* 2005; 8: 384–390.
4. **Kouba E, Smith A, McRackan D, Allen EM and Pruthi RS.** Watchful waiting for solid renal masses: insight into the natural history and results of delayed intervention. *J Urol* 2007; 177: 466–470.
5. **Chawla AN, Crispin PL, Hanlon AL et al.** The natural history of observed renal masses: Meta-Analysis and review of the literature. *J Urol* 2006; 175: 425–431.

Received August 1, 2008.
Accepted December 18, 2008.