

EXPERIMENTAL STUDY

Small bowel graft revascularization in experiment

Oliverius M, Balaz P, Kudla M, Valsamis A, Cap J, Adamec M

Transplant Surgery Department, Institute for Clinical and Experimental Medicine, Prague, Czech Republic.
maol@ikem.cz

Abstract: Objectives: The technical aspects of a procedure are most important for the outcome of the experiment. This study was designed to compare two techniques suitable for graft revascularization.

Methods: The first technique, where the animal is both donor and the recipient, consists of connecting the grafts' vascular anastomoses to the mesenteric vessel bed. In the second technique, one animal is the graft donor and the other is the recipient, with revascularization to the central vessel bed (subrenal inferior vena cava and aorta). Techniques of restoring digestive tract continuity and creation of diagnostic „chimney ileostomy“ were identical in both groups. All experimental animals were monitored clinically regularly basis as per protocol (weight, temperature, stoma appearance, output and nature of stools). Blood and biopsy samples were obtained on days 0, 3, 5, 7, 10, 20, and 30.

Results: Overall, 43 transplant procedures were performed. The first group included 18 transplants and 66.7 % animals had vascular complications. While in the second group (25 transplant procedures), vascular complication rate was only 12 % (3 out of 25) perhaps due to technique modifications.

Conclusion: Our experiment showed that both types of vascular anastomosis could be used in small bowel transplantation. Connecting the graft vessels to the aorta and inferior vena cava is technically simpler and safer because of fewer subsequent complications (Tab. 1, Fig. 4, Ref. 6). Full Text (Free, PDF) www.bmj.sk.

Key words: bowel transplantation, pigs, techniques, vascular anastomosis.

Small bowel transplantation is currently the standard method of treatment of patients with end-stage bowel failure who have developed life-threatening complications while receiving parenteral nutrition (1, 2). Critical considerations for the procedure to be successful are the technicalities of graft harvesting, preservation and suturing. Given its anatomic and physiological similarities with humans, the pig is the ideal experimental model for mastering these issues (3). Our study was designed to compare two possible experimental models of small bowel transplantation in the pig in terms of feasibility, technical complexity, survival and, last but not least, costs.

Methods

In an effort to ensure maximum absence of species resemblance, the experiment was undertaken using outbred animals, i.e., pigs weighing 30–35 kg. All animals were kept in the animal unit of the Experimental Department of the Institute for Clinical and Experimental Medicine while complying to applicable standards for handling laboratory animals as stipulated for by

Transplant Surgery Department, Institute for Clinical and Experimental Medicine, Prague, Czech Republic

Address for correspondence: M. Oliverius, MD, Transplant Surgery Dept, Inst for Clinical and Experimental Medicine, Videnska 1958/9, CZ-140 00 Prague 4, Czech Republic
Phone: +420.721.351528

Acknowledgement: The experiment is part of a study supported by IGA NR/ 8896-3 (Small bowel transplantation in experiment).

Act 246/92 Coll. (4). Prior to graft harvesting and/or transplantation, the animals were pre-treated (stresnil 7 mg/kg, ketamine 10 mg/kg, atropin 0.01 mg/kg), with subsequent anesthesia induction (hypnomidate 1 mg/kg + fentanyl 5 ml). Throughout the procedure, anesthesia was maintained with a mixture of anesthetics (isofluran 1–2 % + fentanyl 0.2 ml/kg) used on a standard basis in our laboratory, with ventilation controlled by an SV Siemens 900 system. Together with pre-treatment, all animals were given veterinary amoxicillin-clavulanate at a dose of 0.05 mg/kg. Another two doses were administered at 24 hour intervals after the first dose. Pain in the postoperative course was controlled by analgesia (butorphanol 0.2 mg/kg). Animals surviving to postoperative day 30 (end of experiment) were sacrificed in compliance with Act. 246/92 Coll. by circulatory arrest, under general anesthesia, induced by the administration of a high dose of an anesthetic, with subsequent autopsy.

The overall survival of animals is affected by a variety of factors (infection, immunosuppression used, rejection, etc.). For the procedure to be marked as a technically successful (harvesting, graft preservation, actual transplant procedure), the animals had to survive for more than 48 hours. Animals dying during anesthesia induction for reasons unrelated to the procedure were not included into the study. The crucial consideration for technical failure was the macroscopic finding during autopsy.

Experimental groups

Group one animals (n1=18) had simultaneous small bowel graft harvesting from two animals at a time, in two operating theaters.

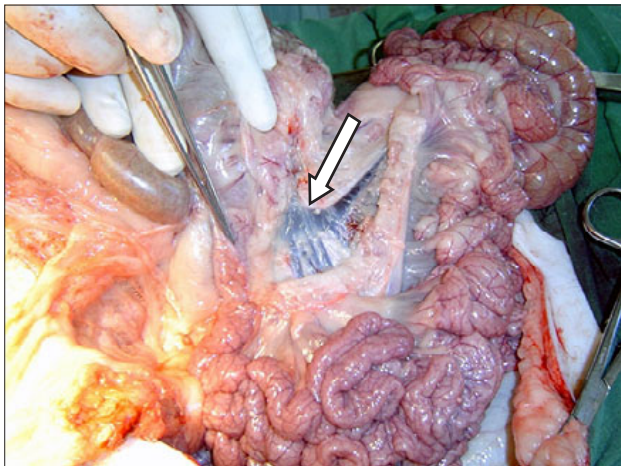


Fig. 1. Branching of the mesenteric vein with origin of the right colic vein - the point of vein transection and future anastomosis in group n1 is indicated by arrow.

The technique was based on vascular anastomosis to the superior mesenteric artery. As a result, the donor becomes the recipient of the other graft.

In the other group (n2=25), one animal served only as a graft donor while the another animal was the recipient. Graft revascularization was accomplished by connecting mesenteric vessels to the central vessel bed (subrenal aorta and vena cava inferior).

Technique of harvesting and transplantation

Group (n1). The abdominal cavity is opened by extended midline laparotomy. The root of mesentery is transected in the area of the terminal ileum while strictly sparing the entire ileocolic arcade to continue along it up to the origin of ileocolic vessels from right colic vessels. Lymphatic vessels leading to packets of lymph nodes are carefully ligated to prevent subsequent lymphatic leakage into the abdominal cavity.

The small bowel mesenterial root is transected 20 cm from the beginning of the first jejunal loop. Here, it may be occasionally necessary to sacrifice the first jejunal arterial branch by ligation, particularly in cases with early branching of the superior mesenteric artery. Should blood supply be impaired, a portion of the bowel is subsequently resected. The trunk of the superior mesenteric artery and vein is mobilized. Next, the bowel is ligated and transected at the point of the planned resection line at either end. Clamps are placed on the mesenteric vein and artery just below the origin branches to the colon, and the vessels are transected (Fig. 1). I.v. heparin is administered at a dose of 2000 IU prior to clamping. Cannulation of the arterial stump is started by perfusion with preservation solution (Custodiol r HTK solution) while cooling the bowel with crushed ice at the same time. The amount of the solution used was consistent with graft size in an effort to obtain optimal perfusion. Once perfusion is completed, the graft, immersed in the remaining preservation solution, is wrapped into a plastic bag under aseptic conditions and stored in a cooling box.

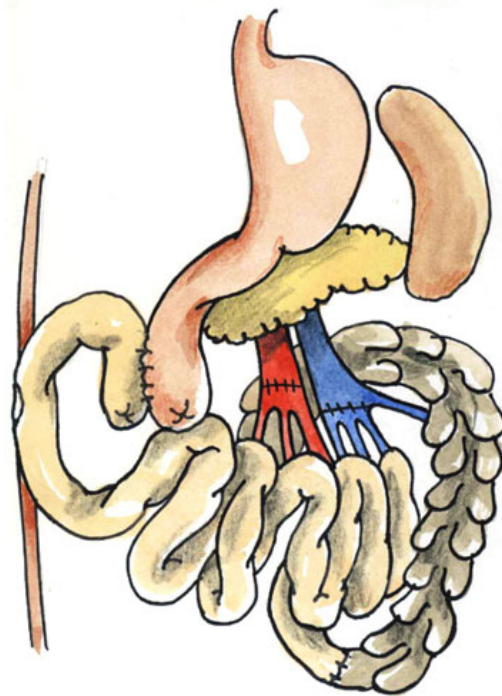


Fig. 2. Schematic representation of transplantation in groups n1.

Using the same technique, graft harvesting from the other animal is under way in another operating theater.

Transplantation in both animals is begun after the 2-hour period of cold ischemia. Upon removing the graft, wrapped in a cold towel from a cooling box, it is immediately placed into the wound. First a vascular conduit to the mesenteric artery stump is established to be followed by anastomosis onto the superior mesenteric artery. An arterial anastomosis is constructed using single stitches with Prolene 6/0 suture. Using continuous suture, venous anastomosis is constructed between the superior mesenteric veins of graft and donor. Upon unclamping, the graft is perfused while warming it with warm physiological solution (Fig. 2).

After suturing the vascular anastomoses, digestive tract continuity is restored. End-to-end anastomosis is established to the terminal ileum. The oral segments of the loop after obtaining zero histological samples from the graft for future analysis are blinded with a tobacco-pouch suture. About 20 cm from the oral end side-to-side anastomosis is constructed, after clamping, between the oral side of the donor jejunum and graft. The openings in the root are tightly closed and the surroundings of the vascular anastomoses beyond the root margins are fixed.

The procedure is completed by bringing mural jejunostomy through an opening in the right hypogastrium to the oral end of the occluded loop. This so-called „chimney stoma“ serves for visual control of the graft and subsequently allows to obtain protocol biopsy samples.

The abdominal cavity is closed by continuous suture.

Group (n2). In the second group, one animal becomes donor while the other is recipient. The procedure is begun in an identical manner. First, the course of the ileocolic arcade, to be spared, is identified. The right colic branch supplying the colon is ligated. The arcades originating from the ileocolic vessels and leading to terminal ileum are ligated approximately 15 cm from the ileocecal valve and the future resection line on the terminal ileum is marked. The serous layer of the small bowel is mobilized from the duodenum, and the mobilization of the whole root is completed.

The oral resection line is drawn about 20 cm behind the duodenojejunal flexure. The transected loop is blinded. The trunk of the superior mesenteric vein is exposed. Next, we proceed along the trunk to below the pancreas and isolate the individual pancreatic branches and splenic vein which are ligated and divided up to the origin of the portal vein. To the left of the vein, the superior mesenteric artery is exposed. The pancreaticoduodenal branches are then ligated and divided. The aorta is encircled above the origin of the superior mesenteric artery and prepared for clamping.

The graft prepared in this manner is wrapped into a warm towel and the trunk of the aorta and vena cava inferior above the origin of the iliac vessels is mobilized. In the aorta, the origins of both renal arteries are isolated, with both arteries ligated, and heparin is administered. Upon placing ligature above the origin of both common iliac vessels, a cannula is inserted into the aorta, the portal vein transected under the pancreas, and bowel perfusion with cold preservation solution initiated. Crushed ice is placed into the abdominal cavity and the preserved graft is immersed, after thorough perfusion, in the remaining preservation solution.

Actual transplantation

The bowel graft along with the root is exposed using a technique similar to that in the first group. The trunk of the superior mesenteric artery and vein is isolated and transected right behind the origin of the right colic branch supplying the colon. The bowel is removed after transecting the oral segment of the jejunum and terminal ileum.

The retroperitoneum is opened below the origin of renal vessels to reach the abdominal aorta and vena cava inferior. Both vessels are exposed to the extent necessary for clamping. A Satinsky clamp is placed on the vena cava inferior, followed by longitudinal venotomy. The graft, wrapped in an ice-cold towel, is placed into the wound and venous anastomosis between the vena cava and the graft mesenteric vein is constructed. Upon completing an anastomosis, a short clamp is placed above it, with blood flow restored along the whole vena cava.

Upon clamping the abdominal aorta and cutting off a circular opening, anastomosis between the patch of the graft aorta and recipient aorta is established. Once suturing the anastomoses is completed, the clamps are removed and graft reperfusion started while warming it with warm physiological solution (Figs 3, 4). The technique of restoring bowel continuity, gastrotomy and jejunostomy creation is identical.

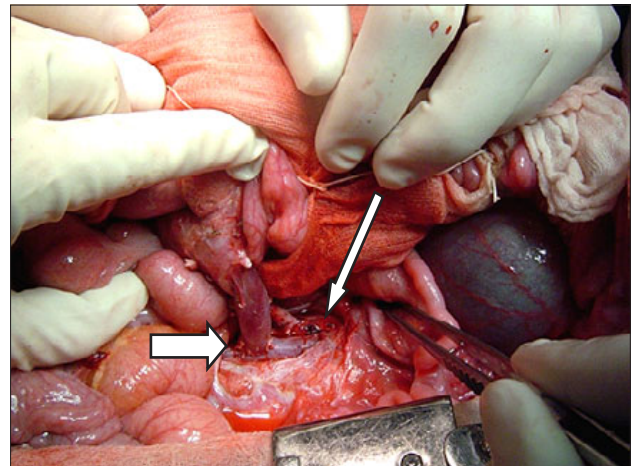


Fig. 3. Anastomosis of the superior mesenteric artery to the aorta (thin arrow) and portal vein (thick arrow) following perfusion in group n2.

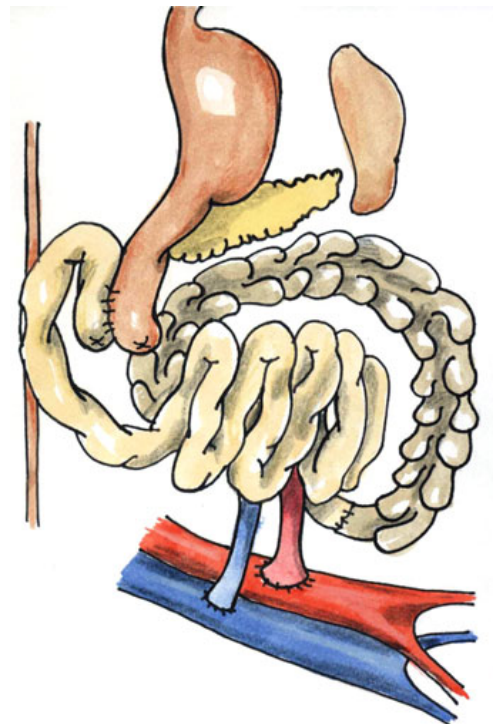

Fig. 4. Schematic representation of transplantation in groups and n2.

Results

In the first group (n1=18 animals), a technical complication with subsequent loss of the animal developed in 12 animals out of the 18 (66.7 %). One animal died of sepsis associated with bronchopneumonia on postoperative day 1 with a viable graft and functional anastomoses. Five animals from this group survived (range 3–32 days; mean 12.5; median 5.5 days).

Tab. 1. Causes of death within the first 48 hours post-transplantation (technical anastomotic failure marked with grey).

	Group n1	Group n2
Bleeding from anastomosis	1	3
Occlusion of anastomosis with graft ischemia	11	0
Non-vascular complications	1	4

In the second group, three animals out of 25 died due to technical complications (12 %). Another 3 animals died within the first 48 hours from bowel perforation with maintained blood flow through the anastomoses, and one animal died from circulatory failure during anesthesia shortly after transplantation. The other 18 animals survived over the long term (range 2–30 days; mean 16 days; median 11 days) (Tab. 1).

Discussion

Small bowel transplantation, from harvesting of a high-quality graft, through preservation, to subsequent revascularization is a most challenging surgical procedure. The most frequent causes of transplantation failure include technical complications related to vascular anastomoses. In addition to bleeding, these include kinking and/or stenosis of the anastomosis resulting in graft thrombosis and ischemia. Acute rejection has no major effect on the outcome within the first 48 hours. In the literature, technical complications are reported in 10–50 % of cases, particularly in the so-called learning curve period (5, 6).

The animal we chose as our model for the experiment was a pig because of its anatomic and physiological similarity to humans. The animals used worldwide for small bowel transplantation in experiment are mostly mini-pigs. Their breeding in the Czech Republic does not comply with requirements on outbred breeding due to the shortage of male pigs used to inseminate female pigs which for our experiment was carried out with regular pigs.

Although we considered the first approach of revascularization with the graft connected to the animal's own mesenteric vessel more convenient given the numbers of experimental ani-

mals used, the study has shown it is technically feasible yet much more demanding in terms of actual performance. The result is a higher rate of complications with subsequent loss of experimental animals. Use of the second technique of graft revascularization is technically simpler with a significantly lower incidence of complications leading to graft loss due to vascular causes. As opposed to the first group with significantly predominant complications related to graft stenosis or kinking, no such complications occurred in the second group. There were three cases of death due to technical error caused by bleeding.

Conclusion

Small bowel transplantation is a technically challenging procedure. Our experimental study has shown that graft revascularization with connection to the mesenterico-portal vessel bed using one animal both as donor and recipient is technically feasible. However, it is accompanied with a higher rate of complications compared with transplantation using two animals, with one serving only as graft donor and the other graft recipient, and the anastomosis sutured onto the central vessel bed.

References

1. Pascher A, Kohler S, Neuhaus P, Pratschke J. Present status and future perspectives of intestinal transplantation. *Transplant International* 2008; (21) 5: 401–414.
2. Ruiz P, Kato T, Tzakis A. Current status of transplantation of the small intestine. *Transplantation* 2007; 83 (1): 1–6.
3. Matia I, Balaz P, Fronck J, Jackanin S, Pomfy M, Rybarova E, Kron I, Ryska M. Serotonin levels in the small bowel mucosa as a marker of ischemic injury during small bowel preservation. *Annals Transplantation* 2004; 9: 48–51.
4. Act 246/1992 Coll. against cruelty to animals, in current wording. *Collection of laws* 1992; 50: 1284.
5. Caleja-Kempin J, Vazquez-Esteviz J, Martin-Cavanna J et al. Vascular thrombosis in small bowel transplantation: a comparative study in the pigs. *Transplantation Proceedings* 1998; 30: 2646.
6. Kaneko H. Technical aspects of small bowel transplantation in the pig allograft model. *Transpl Proc* 1996; 28 (3): 1843–1844.

Received October 10, 2008.

Accepted December 1, 2008.