

CASE REPORT

The additional tendons of the extensor digitorum muscle of the hand: an anatomical study with a clinical significance

Srijit Das, Israa M Sulaiman, Farida Hussan, Azian Abd Latiff, Fariyah Haji Suhaimi, Faizah Othman

Department of Anatomy, Faculty of Medicine, Universiti Kebangsaan Malaysia. das_srijit23@rediffmail.com

Abstract: The extensor digitorum (ED) muscle of the hand originates from the lateral condyle of the humerus and splits into four tendons; each for one phalanx except the thumb. Literature reports have described multiple tendons (usually two) to each digit but in the presented study we observed four tendons to the ring finger, what is rare. During a routine dissection of the cadavers, we observed an anomalous arrangement of the ED tendon on the left hand of a 42-year-old male. The anomalous tendons to the ring finger were studied in detail, the surrounding structures were carefully delineated and the specimen was photographed. The ED muscle originated as usual from the lateral condyle of the humerus, continued downwards, passing inferiorly to the extensor retinaculum to split into individual tendons for each of the digits. There was a single tendon to the index, middle and ring finger as usual but the ring finger displayed four tendons. All the tendons attached to the phalanges were as described in anatomy textbooks. The arrangement of the anomalous tendons of ED to each of the digits is not uncommon, but existence of four tendons to the ring finger is extremely rare. The increased number of tendons to the ring finger may increase the extension component of the ring finger. Anatomical knowledge of the tendons of the extensor muscles of the hand may be also beneficial for hand surgeons performing graft operations (*Fig. 2, Ref. 11*). Full Text (Free, PDF) www.bmj.sk.

Key words: extensor digitorum, muscle, variations, anatomy, tendon, graft, surgery.

Standard textbooks of anatomy mentions the fact that the ED is one of the dozen extensor muscles belonging to the posterior compartment of the forearm which arises from the lateral condyle of the humerus, forms a prominent belly in the middle of the forearm, thereby passing under the extensor retinaculum to split into tendons for each of the digits except the thumb (1,2). The tendons then diverge on the dorsum of the hand, thereby passing to each finger and are attached to the extensor expansion of the phalanges (1, 2).

According to the standard textbooks of anatomy, the tendons of the ED may be deficient, but occasionally they are doubled or tripled in one or more digits with the incidence of such variations more common in the index or the middle finger (1, 2). It is very uncommon to observe four tendons to the ring finger as observed in the presented case. To our best knowledge, even literature reports have not described the presence of four tendons to the ring finger. The presence of four tendons to the ring finger as observed in the presented case may increase the extension component of the fourth digit. Anatomical knowledge of such

variations should be considered while performing tendon graft surgeries.

A Case Report

During a routine dissection of the cadavers for the undergraduate medical students, we observed an anomalous arrange-

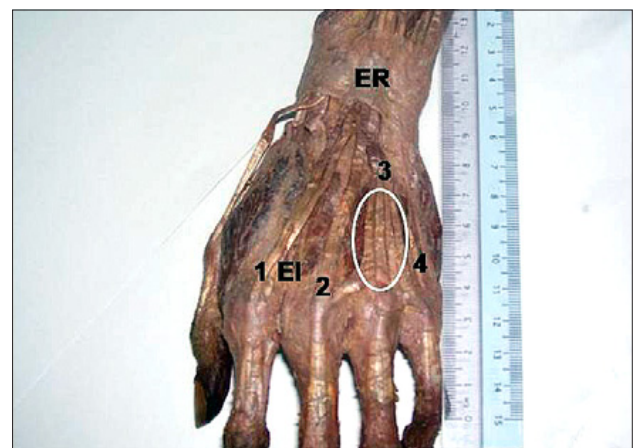


Fig. 1. Photograph of the anomalous left hand (extensor surface): 1, 2, 3, 4: four tendons of ED to each of the digits. EI – tendon of extensor indicis, ER – extensor retinaculum. The four tendons passing to ring finger are encircled.

Department of Anatomy, Faculty of Medicine, Universiti Kebangsaan Malaysia, Kuala Lumpur, Malaysia

Address for correspondence: Srijit Das, MD, Dept of Anatomy, Faculty of Medicine, University Kebangsaan Malaysia, Jalan Raja Muda Abd Aziz, 50300 Kuala Lumpur, Malaysia.
Phone: +6.03.92897263, Fax: +6.03.26989506

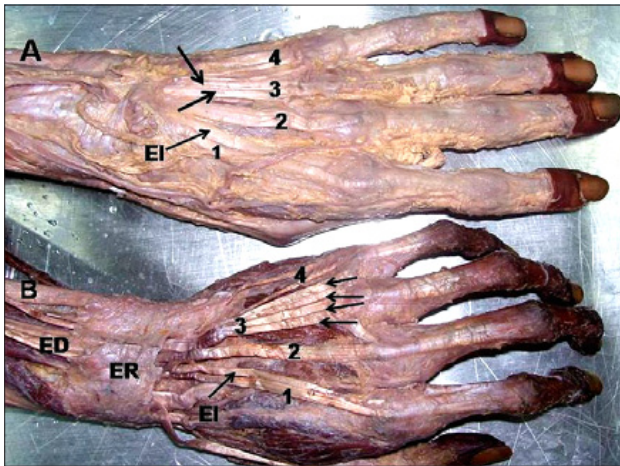


Fig. 2. Photograph of the anomalous hand compared to the normal hand (dorsal view). A – normal hand: EI – tendon of extensor indicis. 1, 2, 3, 4: four tendons of ED to each of the digits. The two tendons to the ring finger are shown with 2 arrows. B – anomalous hand: ED – extensor digitorum, ER – extensor retinaculum, EI – tendon of extensor indicis. 1, 2, 3, 4: four tendons of ED to each of the digits. The four tendons to the ring finger are shown with 4 arrows.

ment of the tendons of ED in the ring finger, i.e. the 4th digit on the left hand of a 42-year-old male. The anomalous tendons to the ring finger were studied in detail and the surrounding structures were delineated. Morphometric measurements were taken and the specimen was photographed (Fig. 1). The anomalous tendons were also compared to the normal arrangement of the tendons of the ED (Fig. 2).

The ED muscle originated as usual from the lateral condyle of the humerus along with other extensors of the forearm. The ED traversed the extensor retinaculum (ER) along with the tendon of the extensor indicis (EI) through a separate tunnel. The tendons then split into slips meant for each of the lateral four digits. At a distance of 1.5 cm from the ER, the ED tendon exhibited an anomalous arrangement while continuing into the fourth digit i.e. ring finger. The tendons split into 4 distinct parts in the ring finger (Fig. 1). All four tendons were close to each other and inserted into the extensor expansion as usual. No abnormality in the arrangement of the number of tendons of the ED to the other digits or any other associated muscle tendon was observed.

Discussion

The tendon of the ED may exhibit multiple variations in terms of number. Even the standard textbooks of anatomy mention that the tendon of ED may be doubled or even tripled in any of the digits and such a variation has been reported to be more common in the index or the middle finger (1, 2). Hence, even a double tendon to any of the digits may be taken as usual finding. There are even reports of double or triple tendons to the long fingers, single or double tendons to the little finger and occasionally double tendons to the little finger (3). A concurrent anomaly of

the three slips to the extensor digiti minimi and a separate tendon of ED to the little finger have been reported (4). A past study had also reported the ED muscle with a single tendon to the index and middle finger with an absence of any tendon to the ring finger (5). Interestingly, another study by one of the authors had detected a double tendon to the ring and the little fingers and three tendons to the ring finger (6, 7). Considering the earlier findings, the present study is a rare entity which describes four tendons to the ring finger.

Various reports describing anomalous tendons of the ED not only provide additional information on the existing literature but also arouse a profound academic interest in clinicians. Usually, these are incidental findings during a routine cadaveric dissection and autopsies. Many times, the presence of variations may be asymptomatic thereby having lower chances for detection (8).

The embryological reasoning for such types of anomaly is explained by the fact that the precursor extensor muscle mass differentiates into three bundles: namely the superficial extensor digitorum communis, extensor carpi ulnaris and extensor digiti quinti proprius and any developmental defect is related to the developing extensor sheet of the forearm (9).

It should be reminded that any successful tenosynovectomy in the treatment of de Quervain's disease requires an adequate anatomical knowledge on the extensor tendons (10). Prior anatomical knowledge of the tendons may help in planning tendon graft surgeries.

Literature reports have depicted that synovitis of extensor tendons are observed in 30 % of the rheumatoid arthritis cases with bigger chances of the tendons ruptures in the 4th and 5th digits and the extensor pollicis longus (11). Thus, the tendons of the ring finger assume a higher clinical significance. In the presented study, we observed four distinct thin tendons to the fourth digit without any additional abnormalities of the extensor muscles. The presence of such multiple thin tendons may be vulnerable to rupture in diseases like rheumatoid arthritis.

Conclusion

The presented study reported an anomalous quadrupled tendon of ED to the ring finger, what may be important for academic and clinical purpose. Prior anatomical knowledge of such variations may help check any inadvertent injury during hand surgery or help in planning tendon graft surgeries.

References

1. Williams PL et al. Gray's Anatomy. The Anatomical Basis of Medicine and Surgery. 38th Edition. Edinburgh, Churchill Livingstone 1997, p. 849–850.
2. Sinnatamby CS. Last's Anatomy. Regional and Applied. 10th Edition, Edinburgh, Churchill Livingstone, 2001, p. 71–72.
3. von Schroeder HP, Botte MJ. Anatomy of the extensor tendons of the fingers: variations and multiplicity. J Hand Surg Amer 1995; 20 (1): 27–34.

4. **Seradge H, Tian W, Baer C.** Anatomic variation of the extensor tendons to the ring and little fingers: a cadaver dissection study. *Amer J Orthop* 1999; 28 (7): 399–401.
5. **Zilber S, Oberlin C.** Anatomical variations of the extensor tendons to the fingers over the dorsum of the hand: a study of 50 hands and a review of the literature. *Surg* 2004; 113 (1): 214–221.
6. **Paul S, Das S.** Anomalous extensor tendons of hand: a case report with clinical importance. *Colombia Medica* 2007; 38 (2): 141–143.
7. **Mestdagh H, Bailleul JP, Vilette B, Bocquet F, Depreux R.** Organization of the extensor complex of the digits. *Anat Clin* 1985; 7 (1): 49–53.
8. **Nayak SR, Krishamurthy A, Prabhu LV, Jiji PJ, Ramanathan L, Kumar S.** Multiple supernumerary muscles of the arm and its clinical significance. *Bratisl Lek Listy* 2008; 109 (2): 74–75.
9. **Abu-Hijleh MF.** Extensor pollicis tertius: an additional extensor muscle to the thumb. *Plast Reconstr Surg* 1993; 92 (2): 340–343.
10. **Shiraishi N, Matsumura G.** Identification of two accessory muscle bundles with anomalous insertions in the flexor side of the right forearm. *Okajimas Folia Anat Jpn* 2007; 84 (1): 35–42.
11. **Nevasier RJ, Wilson JN, Gardner MM.** Abductor pollicis longus transfer for replacement of first dorsal interosseous. *J Hand Surg Amer* 1980; 5: 53–57.

Received July 11, 2008.

Accepted October 20, 2008.