

CLINICAL STUDY

Management of the prosthetic vascular graft infections – the influence of predictive factors on treatment results

Treska V¹, Houdek K¹, Vachtova M¹, Smid D¹, Kormunda S²

Department of Surgery, University Hospital, Medical Faculty of Charles University of Prague, Pilsen, Czech Republic. treska@fnplzen.cz

Abstract: *Background:* This prospective non-randomized single center study evaluated the predictive significance of various factors to the treatment outcomes of the prosthetic vascular graft infections.

Methods: 46 patients with the prosthetic vascular graft infection underwent the treatment. The prosthesis excision was performed in 37 cases. The extra-anatomical reconstruction was implanted in 18 and the in situ reconstruction in 12 patients. In 9 patients, only local treatment was applied. The influence of the preoperative factors (patient's age, type of primary procedure, type of infection, positive hemoculture, diabetes mellitus, comorbidity, C-reactive protein, leucocytosis, repeated interventions) on the result of the treatment was evaluated with the multivariate analysis.

Results: On the 30 day, the postoperative mortality was 23.9 %. One and three years after the treatment, 72.1 and 57.8 % of patients, respectively, survived. C-reactive protein above 90 mg/l (Wilcoxon test $p < 0.02$, Log-rank test $p < 0.01$), and leucocytosis $> 13 \times 10^9/l$ (Wilcoxon test $p < 0.0001$, Log-rank test $p < 0.0004$) were significant factors for patients morbidity and mortality. There were no preoperative factors with a statistically significant cut-off value which should be important for the long-term graft patency.

Conclusion: C-reactive protein and leucocytosis are simple preoperative predictive markers of the treatment results of the prosthetic vascular graft infections. An early and aggressive diagnostic and therapeutic procedure is recommended in patients with the pre-operative levels of CRP higher than 90 mg/l and leucocytosis of $13 \times 10^9/l$ (Tab. 5, Fig. 3, Ref. 30). Full Text (Free, PDF) www.bmj.sk.

Key words: prosthetic vascular graft infection, predictive factors, morbidity, mortality, graft patency.

Prosthetic vascular graft infections (PVGI) are the most serious complications in vascular surgery, with high rates of morbidity and mortality. 30 years ago, the mortality of PVGI was higher than 50 %, and 50–75 % of patients experienced a loss of limb. The sophisticated methods in the treatment of patients with lower extremity ischemia, as well as thorough antibiotic prophylaxis of primary vascular and endovascular procedures, changed the incidence of infections after the vascular reconstructions, which is now relatively low (0.5–5 %) (1, 2). However, 15–30 % of patients with PVGI still experience the loss of limb, and 20–40 % of patients die within 1 year of the occurrence of PVGI (3, 4).

The aim of the prospective non-randomized study was to evaluate the significance of preoperative prognostic factors for morbidity and mortality in patients with PVGI. This study also provides the current management of prosthetic vascular graft infection.

Material and methods

Between January 1, 2001 and December 12, 2007, a total of 46 patients with PVGI were admitted to the Department of Surgery, University Hospital in Pilsen. The average age of the patients was 60.7 ± 9.4 years, and the men – women ratio was 5:1. The primary procedures were aortofemoral or bifemoral reconstructions (end to side central anastomoses) in 16 cases, femoropopliteal reconstructions in 25 cases and profundoplasties or extra-anatomical reconstructions in 5 cases. All procedures were performed in patients with peripheral arterial occlusive disease, no patient suffered from aneurysm. The period from the primary intervention to the occurrence of infection was on average 2.7 ± 4.1 years. There were no infections during the first hospital stay after the primary vascular reconstruction. At the time of admission, 28 infected reconstructions (60.8 %) were functional, whereas 18 reconstructions (39.1 %) were thrombosed. The infection process involved the proximal (central) part of aortofemoral or bifemoral grafts in 9 cases. In the remaining cases, the graft infection was localised peripherally (Table 1). Forty one (89.1 %) patients had symptoms of PVGI. Symptoms of PVGI were atypical in 5 (10.9 %) patients (Table 2). The diagnosis of PVGI was established by patient history, clinical examination, laboratory tests (C-reactive protein, leucocytosis), microbiologic profile, ultrasonography (USG), computed tomo-

¹Department of Surgery, University Hospital, Medical Faculty of Charles University of Prague, Pilsen, Czech Republic, and ²Institute of Social Medicine, Medical Faculty of Charles University, Pilsen

Address for correspondence: V. Treska, MD, PhD, Dept of Surgery LFUK, Alej Svobody 80, CZ-304 60 Pilsen, Czech Republic. Phone: +420.37.7104270

Acknowledgement: The study was supported by the research project VZ MSM 002 16 208 19.

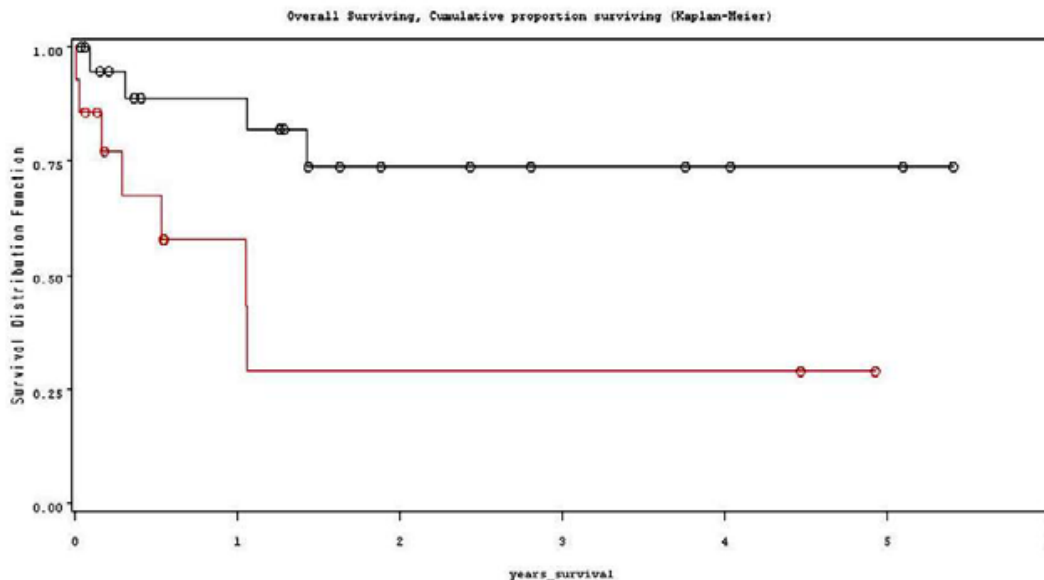


Fig. 1. The influence of the admission value of C-reactive protein on the high amputation and mortality (red – CRP >90 mg/l, black – CRP <90 mg/l).

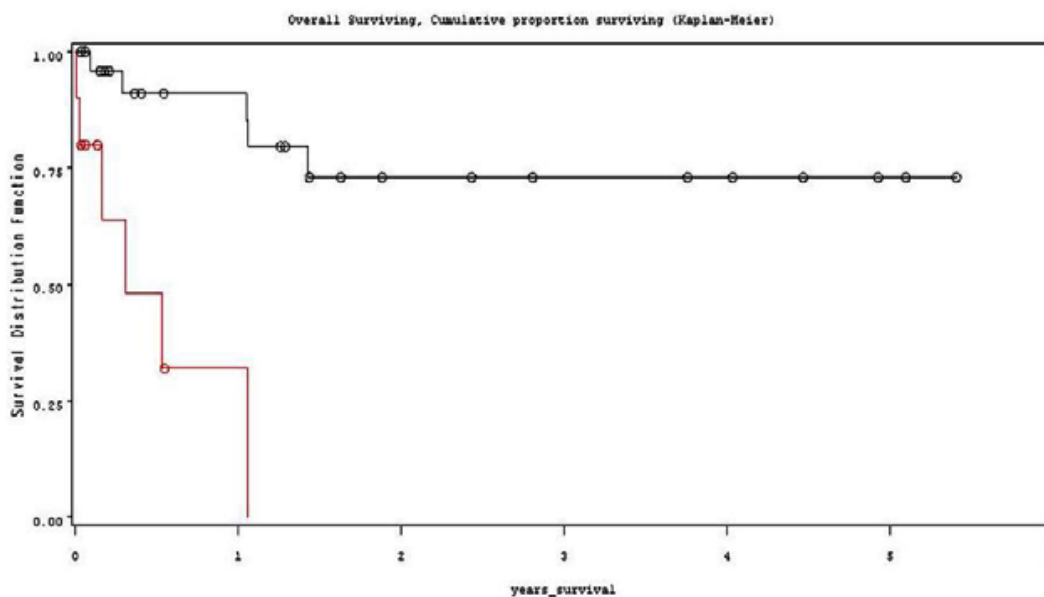


Fig. 2. The influence of the admission value of leukocytes on the high amputation and mortality (red – leukocytes >13x10⁹/l, black – leukocytes <13x10⁹/l).

ment (end point – patient’s death or a high amputation of the limb). Preoperative serum level of CRP >90 mg/l (Wilcoxon $p < 0.02$, Log-rank test $p < 0.01$) (Fig. 1), and leucocytosis higher than $13 \times 10^9/l$ (Wilcoxon, $p < 0.0001$, Log-rank test, $p < 0.0004$) (Fig. 2, Tab. 4), were statistically significant for the high amputation and mortality of patients. The age of patients, type of infection, positivity of hemoculture, diabetes mellitus or other comorbidity (tumors, chronic pancreatitis), the time from the

primary reconstruction to the occurrence of infection and repeated intervention were statistically non-significant factors for patients, morbidity and mortality. Using the multivariate Cox’s regression model, we evaluated that the pre-operative level of leukocytes above $13 \times 10^9/l$ (Hazard ratio 8.4, $p < 0.002$) was statistically highly significant for the patient mortality, as it increases the risk of death 8.4 times. There were no preoperative factors with a statistically significant cut-off value, which should be

Tab. 4. The influence of individual factors on treatment results (end point-high amputation, mortality).

Factor	Cut off value	Kaplan-Meier		Cox Hazard model	
		Log-rank test (p<)	Wilcoxon test (p<)	Hazard ratio	p<
Age	56	0.07	0.07	3.87	0.08
AF (ABF) x FP x others	–	0.09	0.06	16.3	0.01
Central x peripheral type of infection	–	0.07	0.11	3.17	0.09
Staphylococcal infection	–	0.97	0.97	0.92	0.91
G + infection	–	0.56	0.60	0.68	0.57
G – infection	–	0.83	0.91	1.15	0.83
Mixed infection	–	0.34	0.69	1.88	0.35
Positive hemoculture	–	0.71	0.65	0.74	0.72
Leukocytosis	13x 10 ⁹	0.0001	0.0004	9.35	0.001
C-reactive protein	90	0.01	0.02	4.40	0.02
Diabetes mellitus	–	0.16	0.14	0.26	0.20
Comorbidities	–	0.26	0.18	2.13	0.27
Infection interval (years)	0.24	0.14	0.27	2.98	0.16
Repeated interventions	–	0.51	0.51	-	0.99

Tab. 5. The influence of individual factors on graft patency in the follow-up period.

Factor	Cut off value	Kaplan-Meier		Cox Hazard model	
		Log-rank test (p<)	Wilcoxon test (p<)	Hazard ratio	Chi-square test (p<)
Age	56	0.07	0.07	3.87	0.09
AF (ABF) x FP x others	–	0.10	0.15	0.35	0.12
Central x peripheral infection	–	0.08	0.12	3.17	0.09
Staphylococcal infection	–	0.90	0.82	0.92	0.91
G + infection	–	0.56	0.60	0.68	0.57
G – infection	–	0.83	0.91	1.15	0.83
Mixed infection	–	0.34	0.70	1.88	0.35
Positive hemoculture	–	0.71	0.65	0.74	0.71
Leukocytosis	13x 10 ⁹	0.08	0.08	4.35	0.09
C-reactive protein	90	0.10	0.12	2.40	0.15
Diabetes mellitus	–	0.16	0.14	0.26	0.20
Comorbidities	–	0.26	0.18	2.13	0.27
Infection interval (years)	0.24	0.14	0.27	2.98	0.16
Repeated interventions	–	0.51	0.51	Cannot be computed	Cannot be computed

important for the long-term graft patency (Tab. 5). 72.1 % of patients with a functional reconstruction survive 1 year after the treatment, and 57.8 % of patients survive 3 years (Fig. 3).

Discussion

PVGI may occur any time after the performance of the primary vascular reconstruction. The median of this period was 3 years, with 70 % of PVGI coming later than 1 year after the primary vascular reconstruction.

In 1972, Szilagyi (4) first divided PVGI, in simple form, into 3 degrees, according to their clinical severity. The first degree included infections affecting the dermis, the second included subcutaneous tissue and the third degree included infections affecting the vascular prosthesis. In 1983, Bunt (5) divided infections of the aortic vascular reconstructions according to the presence of the aortoenteric fistula. In 1988, Samson modified Szilagyi's classification into 5 degrees and proposed a management of PVGI (6). In 1990, Bandyk (7) classified PVGI according to the presence of various kinds of microorganisms, and in

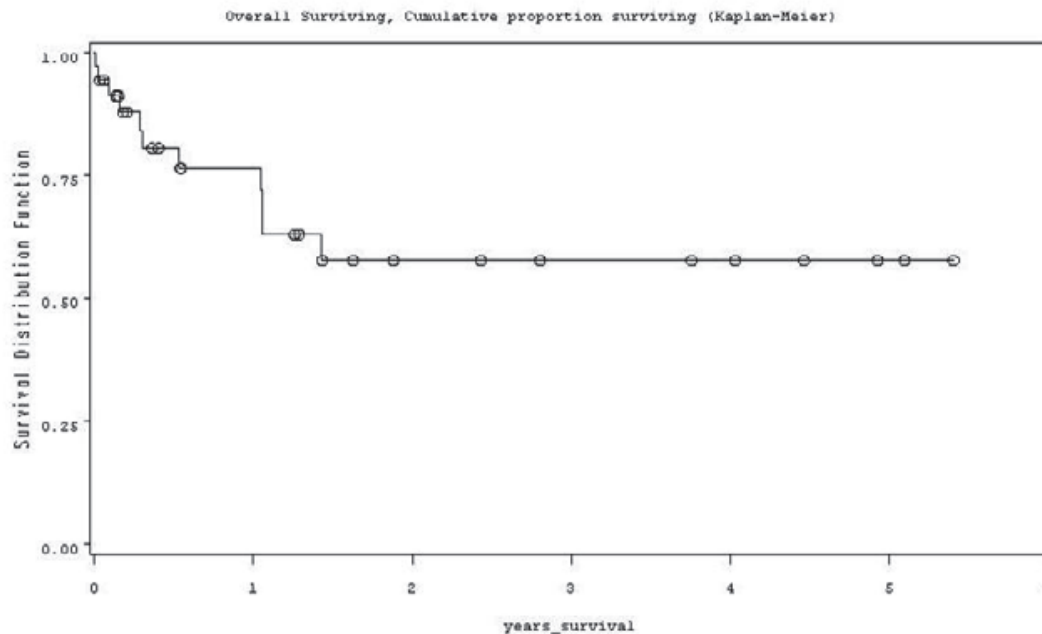


Fig. 3. Survival of patients with functional reconstruction.

1995, Goeau-Brisssoniere (8) divided PVGI in relation to their occurrence from the primary vascular reconstruction into early infections, occurring within 3 months from the primary vascular reconstruction, and late infections, occurring later than 3 months from the date of the primary reconstruction.

Factors causing a predisposition to the occurrence of a PVGI are following: failure to observe basic conditions of asepsis during vascular reconstruction with direct contamination of the vascular prosthesis; incorrect indication for vascular reconstruction of patients with an infection in the organism; urgent vascular reconstruction (trauma, rupture of aneurysm); time-consuming surgical procedures; repeated procedures or, in some cases, simultaneous procedures in the abdominal cavity (e.g. procedures on the gastrointestinal tract). Vascular reconstructions with implants of vascular prosthesis in the inguinal area are more susceptible to infections, compared with intra-abdominal reconstructions. Vascular reconstructions on limbs where necrosis (gangrene) is present are also susceptible to infection, particularly in diabetics or patients with an immunity disorder.

From the microbiological point of view, PVGI are caused by a wide spectrum of microorganisms. For the early PVGI, highly virulent groups are typical, such as *Staphylococcus aureus*, *Enterobacter*, *Klebsiella*, *Pseudomonas*, *Proteus*, *Escherichia coli*, *Salmonella* (9). At present, a major problem for early PVGI represents methicillin resistant *Staphylococcus aureus* (MRSA), vancomycin resistant *Enterococcus* (VRE) and *Pseudomonas* infections (high grade infections), since there is a high morbidity and mortality of the affected patients (10). For the late PVGI, *Staphylococcus epidermis* is a typical agent (low grade infection), which is often characterised by a long-term symbiosis with the host before clinical manifestation of the infection. In patients with

a reduced immunity for various reasons, serious mycotic graft infections may occur (*Candida*, *Mycobacterium*, *Aspergillus*) (11).

The symptoms of PVGI are various. Early PVGI show local manifestations, such as swelling, inflammation or fistula, particularly in inguinal area, bleeding or false aneurysm, aortoenteric fistula, thrombosis of vascular reconstruction, or peripheral embolization. Early PVGI are usually accompanied by general symptoms of infections. Late PVGI have very weak symptoms, expressed mainly by local signs of infection – false aneurysm, thrombosis of reconstruction, bleeding (particularly in aortoenteric fistula). Most cases of late PVGI have no general symptoms.

In the present era of endovascular procedures it is also necessary to mention this sphere of the vascular surgery, which is and will continue to be burdened by the occurrence of infections, as is the case of open vascular reconstructions. In 2005, 15 cases of endovascular stent or stent graft infections were reported, out of which 3 ended in the death of the patient (12). The main etiopathogenetic agents were *Staphylococcus aureus* and *Staphylococcus epidermis*. The symptoms were localized pain in the area of the implanted stent, swelling, inflammation of the affected limb, often accompanied by general symptoms of infection. The cause of patient death was mostly rupture of the affected artery, followed by a massive bleeding.

The basic diagnostic indicators, apart from clinical examination and patients history, are increased levels of leukocytes and CRP, sedimentation and positive bacteriological culture from the site of the vascular infection, and a positive hemoculture. USG with findings of the accumulation of fluid around the vascular reconstruction and false aneurysm in anastomosis, as well as CT and MRI have a high sensitivity (around 95 %) and specificity (about 55 %) for PVGI (13, 14). Suspected PVGI on CT or

MRI can be identified by a free prosthesis with no signs of healing in the surrounding tissue, by the accumulation of fluid with gas bubbles around the vascular reconstruction, tissue swelling around the reconstruction and false aneurysm in anastomosis. The advantage of CT or USG is the possibility of the aspiration of the liquid around the vascular reconstruction for subsequent bacteriological examination. Using the above mentioned examinations, in the absence of clinical manifestation, it is difficult to distinguish the early PVGI from post-operative changes, simple hematoma and the presence of gas after surgery, which is registered in about 15 % of the patients. If, however, the accumulation of fluid, possibly with gas bubbles, lasts more than 3 months even in a clinically silent manifestation, we have to consider the presence of PVGI (15). Other examination methods include PET CT and scintigraphy with leukocytes marked with gallium or indium. However, this examination has a high number of false positive results, particularly in the first 6 weeks after the vascular reconstruction (16).

Basically, there are three surgical possibilities in the treatment of PVGI (17). The first is the excision of the infected reconstruction with a large-scale debridement of the infected tissue without making a new reconstruction. This method is possible only in patients who, as a result of PVGI, have developed thrombosis of the reconstruction, which is bridged with a sufficient collateral circulation. Even then is this method burdened with a high number of amputations (33–36 %), and is used at the least of all surgical procedures. The second method, so called 'gold standard', consists of the excision of the PVGI together with the infected tissue and the replacement with an extra-anatomical reconstruction (or vice versa). The remaining question is the order of the procedures. It is possible either to perform a simultaneous procedure, which means a PVGI excision and the immediate establishment of an extra-anatomical reconstruction (or vice versa), or a so-called staged procedure with an interval of 2–4 days between the excision of the reconstruction and the revascularization (18, 19). On the basis of our experience, we prefer the simultaneous treatment. The staged procedure was originally chosen in order to minimize a re-infection of the new vascular reconstruction, but clinical results did not support this intention. A certain advantage of this procedure is the shorter duration of surgery and the reduced number of transfusions. The disadvantage of the procedure, particularly in PVGI in the aortic area, is the risk of the aortic stump insufficiency, with a massive, often fatal, bleeding. Another particular disadvantage, mainly in infections of the abdominal aortic area, where the axillo-bifemoral reconstruction has been established, is its considerably lower long-term function compared to the anatomic reconstruction. The third method is the excision of the PVGI with a large-scale debridement of the infected tissue, and simultaneous in situ reconstruction. The advantage of the in situ reconstruction is its good long-term function, but the disadvantage is a high percentage of the prosthetic graft reinfections (in >20 % cases). In our procedures, we also use the so-called local treatment, particularly in infections localized in the wound on the limb that do not reach the vascular reconstructions. In a number of patients, a complete

debridement of the wound, applying a bactericidal solution compresses, turned out to be the right choice. Therapeutic procedures in PVGI must not be generalized, as every patient with a PVGI requires a strictly individual approach in order to select the best therapeutic procedure.

There are several choices of vascular reconstructions, particularly the in situ reconstructions with a risk of the reinfection. In peripheral reconstructions, an autologous vein (most often vena saphena magna or vena femoralis) is considered, as it is generally the most resistant to the reinfection. Another possibility is to use arterial or venous allografts (20), fresh or cryopreserved. At present, fresh allografts are preferred. From the long-term point of view, the cryopreserved grafts have a high percentage of complications (stenoses, dilations, thromboses and so on). Another possibility is in impregnated, so-called infection resistant, prostheses. The prostheses are impregnated either with antibiotics (Rifampicin) or with silver (21, 22, 23). The disadvantages of the rifampicin impregnated vascular prostheses are following: a very rapid development of resistance in *Staphylococcus aureus* and *Staphylococcus epidermidis*, low sensitivity to MRSA and *Escherichia coli*, a reduction of antibiotic concentration in the prosthesis with time. All these disadvantages are obsolete in the prostheses impregnated with silver, which also demonstrate a very good healing ability in tissue. We use the silver impregnated prostheses (Silver Graft, BBraun, Germany) in our group. However, only the long-term results will show the contribution of these so-called impregnated prostheses in the area of PVGI. At present, there is no optimal vascular prosthesis for PVGI in repeated procedures that would meet the conditions for long-term function and high resistance to infections.

Together with surgical therapy of the vascular reconstruction infections, treatment with antibiotics must be applied (24). At first, the antibiotic treatment is empirical, based on antibiotics effective in staphylococcal and Gram-negative microbes (for example, flucloxacilin, dicloxacillin, first generation of cephalosporins, vancomycin, rifampicin, clindamycin, linezolid), but they must be changed immediately to a targeted antibiotic treatment after sensitivity has been determined. The antibiotic treatment must be long-term, with a minimum of 4–6 weeks, intravenous, and with a subsequent oral therapy for the period of 3–6 months. Some authors recommend a lifelong antibiotic treatment (25, 26).

Prognosis of patients with PVGI depends upon various factors. Recent literature data (27, 28, 29, 30) deal all with the influence of the type of vascular reconstruction (in situ, extra-anatomical), graft material (vein, allograft, PTFE, Rifampin or Silver-soaked grafts) and timing of reoperation on treatment results. Our prospective non-randomized study is the first study in the literature dealing with the influence of some factors on admission that could have a predictive significance for prognosis of patients with PVGI. To the statistical analysis we chose factors, which were simply determinable during the admission of patients. The preoperative level of CRP and the number of leukocytes in particular were very significant factors influencing the result of PVGI treatment. The infections of the pelvic recon-

structions (central type infections) were of borderline significance for the result of the therapy.

Conclusion

Our study demonstrates the high importance of the admission levels of CRP and the leucocytosis for patient's morbidity and mortality. An early and aggressive diagnostic and therapeutic procedure is recommended in patients with the pre-operative levels of CRP higher than 90 mg/l and leucocytosis of $13 \times 10^9/l$.

References

1. **Shahidi S, Eskil A, Lundof E, Klaerke A, Jensen BS.** Detection of abdominal aortic graft infection: comparison of magnetic resonance imaging and indium-labeled white blood cell scanning. *Ann Vasc Surg* 2007; 21: 586–592.
2. **Homer-Vanniasinkam S.** Surgical site and vascular infections: treatment and prophylaxis. *Int J Infect Dis* 2007; 11 Suppl 1: S17–22.
3. **Armstrong PA, Back MR, Bandyk DF, Johnson BL, Shames ML.** Selective application of sartorius flaps and aggressive staged surgical debridement can influence long-term outcomes of complex prosthetic graft infections. *J Vasc Surg* 2007; 46: 71–78.
4. **Szylagyi DE, Smith RF, Elliott JP, Vrandecic MP.** Infection of arterial reconstruction with synthetic grafts. *Ann Surg* 1972; 176: 321–333.
5. **Bunt TJ.** Synthetic vascular graft infections. *Surgery* 1983; 93: 733–746.
6. **Samson RH, Veith FJ, Janko GS, Gupta SK, Scher LA.** A modified classification and approach to the management of infections involving peripheral arterial prosthetic grafts. *J Vasc Surg* 1988; 8: 147–153.
7. **Bandyk DF.** Aortic graft infection. *Sem Vasc Surg* 1990; 3: 122–134.
8. **Goeau-Brissonniere O.** Infection from arterial prostheses. *Presse Med* 1995; 24: 454–458.
9. **Chiesa R, Astore D, Frigerio S.** Vascular prosthetic graft infection: Epidemiology, bacteriology, pathogenesis and treatment. *Acta Chir Belg* 2002; 102: 238–247.
10. **Bunt TJ.** Vascular graft infections: an update. *Cardiovasc Surg* 2001; 9: 225–233.
11. **Valentine RJ, Clagett GP.** Aortic graft infections: Replacement with autogenous vein. *Cardiovasc Surg* 2001; 9: 419–425.
12. **Chambers ST.** Diagnosis and management of staphylococcal infections of vascular grafts and stents. *Int Med J* 2005; 35: S72–S78.
13. **Orton DF, LeVeen RF, Saigh JA.** Aortic prosthetic graft infections: Radiologic manifestations and implications for management. *RadioGraphics* 2000; 20: 977–993.
14. **Egun A, O'Neill H, Ward AS.** Intragraft thrombus: An early CT finding in aortic graft infection. *Eur J Vasc Endovasc Surg* 2000; 20: 482–483.
15. **Castelli P, Caronno R, Ferrarese S.** New trends in prosthesis infection in cardiovascular surgery. *Surg Infect* 2006; 7 (Suppl 2): S45–S47.
16. **Lauwers P, Van den Broeck S, Carp L, Hendriks J, Schil PV, Blockx P.** The use of positron emission tomography with (18) F-fluorodeoxyglucose for the diagnosis of vascular graft infection. *Angiology* 2008; 58: 717–724.
17. **Oderich GS, Bower TC, Cherry KJ.** Evolution from axillofemoral to in situ prosthetic reconstruction for the treatment of aortic graft infections at a single center. *J Vasc Surg* 2006; 43: 1166–1174.
18. **O'Connor S, Andrew P, Batt M.** A systematic review and meta-analysis of treatments for aortic graft infection. *J Vasc Surg* 2006; 44: 38–45.
19. **Sigala F, Menenakos C, Baunach C.** Inguinal anastomotic aneurysm due to salmonellosis treated with orthotopic reconstruction. *Vasa* 2006; 35: 37–40.
20. **Zhou W, Lin PH, Bush RL.** In situ reconstruction with cryopreserved arterial allografts for management of mycotic aneurysms or aortic prosthetic graft infections: a multi-institutional experience. *Tex Heart Inst J* 2006; 33: 14–18.
21. **Schmacht D, Armstrong P, Johnson B.** Graft infectivity of rifampin and silver-bonded polyester grafts to MRSA contamination. *Vasc Endovasc Surg* 2005; 39: 411–420.
22. **Ueberrueck T, Meyer L, Zippel R.** Healing characteristics of a new silver-coated, gelatine impregnated vascular prosthesis in the porcine model. *Zbl Chir* 2005; 130: 71–76.
23. **Ricco JB, InterGard Silver Study Group.** InterGard silver bifurcated graft: features and results of a multicenter clinical study. *J Vasc Surg* 2006; 44: 339–346.
24. **Gabriel M, Pukacki F, Checinski P.** Current options in prosthetic vascular graft infection: comparative analysis of 63 consecutive cases. *Langenbecks Arch Surg* 2004; 389: 272–277.
25. **Terpling S, Schade LC, Schonheyder HC.** Long-term home-based parenteral antibiotic treatment of a prosthetic vascular graft infection caused by *Pseudomonas aeruginosa*. *Scand J Infect Dis* 2004; 38: 388–392.
26. **Stone PA, Armstrong PA, Bandyk DF.** Use of antibiotic-loaded polymethylmethacrylate beads for the treatment of extracavitary prosthetic vascular graft infections. *J Vasc Surg* 2006; 44: 757–761.
27. **Kieffer E, Gomes D, Chiche L.** Allograft replacement for infrarenal aortic graft infection: early and late results in 179 patients. *J Vasc Surg* 2004; 39: 1009–1017.
28. **Batt M, Magne JL, Alric P.** In situ revascularization with silver-coated polyester grafts to treat aortic infection: early and midterm results. *J Vasc Surg* 2003; 38: 983–989.
29. **Perera GB, Fujitani RM, Kubaska SM.** Aortic Graft Infection: Update on Management and Treatment Options. *Vasc Endovasc Surg* 2006; 40: 1–10.
30. **Mussa FF, Hedayati N, Zhou W, El-Sayed HF, Kougiaris P, Darouiche RO, Lin H.** Prevention and treatment of aortic graft infection. *Expert Rev Anti Infect Ther* 2007; 5: 305–315.

Received July 31, 2008.

Accepted October 20, 2008.