

## COMPARATIVE ANATOMY

# An anatomico-radiological study of the grooves for occipital sinus in the posterior cranial fossa

Srijit Das<sup>1</sup>, Azian Abd Latiff<sup>1</sup>, Fariyah Haji Suhaimi<sup>1</sup>, Faizah Bt Othman<sup>1</sup>, Mohd F Yahaya<sup>1</sup>, Fairus Ahmad<sup>1</sup>, Hamzaini Abdul Hamid<sup>2</sup>

*Department of Anatomy, Universiti Kebangsaan Malaysia, Jalan Raja Muda Abdul Aziz, Kuala Lumpur, Malaysia.*

**das\_srijit23@rediffmail.com**

**Abstract:** *Background:* The occipital sinus (OS) lies in the attached margin of the falx cerebelli in the internal occipital crest of the occipital bone. The OS extends from the foramen magnum to the confluence of sinuses. Standard textbooks and research reports do not describe in detail any variation in the groove for the occipital sinus.

*Methods:* In the present study, we examined a total of 50 human dried skulls for the groove of OS and its possible variations. We also performed an osteological study supplemented with digital X ray and CT scan.

*Results:* Out of 50 skull specimens, a single case with two grooves for OS was observed (2 %). The two grooves for OS traversed as two limbs from the foramen magnum to join the other at the internal occipital protuberance. An accessory faint groove was also found at the lateral aspect of the left limb. Interestingly, in the same specimen, the superior sagittal sinus instead of continuing as right transverse sinus, continued as left transverse sinus. The X ray and CT scan of the anomalous bone specimen were compared to those of the normal bone specimen.

*Discussion:* To the best of our knowledge, this is the first anatomico-radiological study of multiple OS groove with associated anomalies. Surgeons should be aware of the variations of the OS in order to check any inadvertent injury during skull surgeries. Presence of such variations may also result in erroneous interpretation of radiological findings (*Tab. 1, Fig. 7, Ref. 17*). Full Text (Free, PDF) [www.bmj.sk](http://www.bmj.sk).

Key words: occipital sinus, gross anatomy, variations, surgery, radiology.

The OS is small sinus which lies in the attached margin of the falx cerebelli. The OS begins near the foramen magnum and ends in the confluence of sinus. According to standard textbooks of anatomy, OS may be occasionally paired but no detailed information regarding its variations or incidence has been published (1). Few reports on the use of cadaveric skulls to define the venous sinuses were found in the literature (2, 3, 4). Many past research studies have described the clinical anatomy of the veins of the posterior cranial fossa by using different imaging methods (5, 6, 7, 8) but there is paucity of literature on the anatomico-radiological study of grooves of OS.

Although some research studies had used retrograde jugular venographies to look into the variations of OS (9) or studied the

sinuses of the occipital region (8), none had reported the OS variations concurrently present with the continuation of the superior sagittal sinus as the left transverse which was seen in the present case. In the extensive search of literature, only a single report of the duplication of the dural sinus was found, but it was confined to the straight sinus (10).

It is very important to understand the intracranial circulation with respect to the haemodynamics of the dural venous sinuses. A past study had stressed this fact (11). The direction of blood flow may be important while attempting surgical procedures on the occipital region. Presence of multiple sinuses in the region of the occipital bone may result in unnecessary hemorrhage. It is also important for proper fixation of occipital screws in occipitocervical fusion (12, 13) hence, proper knowledge of anatomy of OS is mandatory. Thus, prior anatomical knowledge may be beneficial to the neurosurgeons. Often, the venous thrombosis involving the OS is diagnosed by the radiologist and such variations of sinuses should be borne in mind.

We decided to study the normal and abnormal anatomy of the grooves for the OS in osteological specimens while subjecting it to digital X ray imaging and 3D imaging by high resolution computed tomography (CT). Thus, the study approached from two angles i.e. a detailed anatomy of the multiple OS supplemented with the digital X ray and CT scan findings. We as anatomists believe that the abnormal and abnormal anatomy of the

<sup>1</sup>Department of Anatomy, Universiti Kebangsaan Malaysia, Jalan Raja Muda Abdul Aziz, Kuala Lumpur, Malaysia, and <sup>2</sup>Department of Radiodiagnosis, Hospital Universiti Kebangsaan Malaysia, Jalan Yaacob Latif, Bdr Tun Razak, Cheras, Kuala Lumpur, Malaysia

**Address for correspondence:** Srijit Das, MD, Dept of Anatomy, Faculty of Medicine, Universiti Kebangsaan Malaysia, Jalan Raja Muda Abdul Aziz, 50300 Kuala Lumpur, Malaysia.

Phone: +6.03.92897263, Fax: +6.03.26989506

**Acknowledgement:** The authors sincerely wish to acknowledge the help on Ms Hairi Ghazalli from the Department of Anatomy and the technical staff of Radiodiagnosis, Hospital Universiti Kebangsaan Malaysia for her active support and help.

**Tab. 1. The presence of the normal and abnormal grooves for occipital sinus.**

	Anomalous specimen (n=1)	Normal specimens (n=49)
Distance of internal occipital protuberance from foramen magnum	4.5 cm above the foramen magnum.	4.5±0.3 cm from the foramen magnum.
No of OS and its grooves	The two grooves of the OS, began as two limbs from the foramen magnum, separated by a distance of 1.4 cm. Both of these OS ended in the confluence of the sinuses. The left groove was more prominent.(Fig.1, 2B, 4&6)	There was only a single groove of the OS which ended in the confluence of the sinuses. (Fig.2A, 3, 5)
Fate of superior sagittal sinus	Continued as left transverse sinus. (Fig.1, 2B, 4)	Continued as right transverse sinus. (Fig. 2A, 3)

OS and its grooves may be important for academic and clinical purpose.

### Methods

A total of fifty dried cadaveric skulls were taken for the study. We admit that we did not have the details about the age, sex and history of the individuals. We also admit that more number of skulls were not available for the study. The grooves meant for the OS in the occipital bone were studied in detail. Special importance was laid on the location and the number of OS in each skull. Morphometric measurements were taken and the bone specimen was photographed. The skull specimens were also taken for digital radiographic studies using the Philips Digital Diagnost VM, a multipurpose single detector digital radiography system. We also obtained CT scan of the skull using Siemens, Somatom sensation 64. The protocol of the CT helped in obtaining thin slice of the bone with 1mm thickness. We also obtained 3D images of the skull with the grooves marked for the OS.

### Results

The anomalous OS accompanied by abnormal drainage of sagittal sinus was present in a single cadaveric skull (2 %).

Out of the 50 specimens studied, we observed the internal occipital protuberance to be located at an average distance of 4.5±0.3 cm from the foramen magnum. In the anomalous specimen, the internal occipital protuberance was located at a distance of 4.5 cm above the foramen magnum. All the 49 specimens exhibited presence of single groove for OS (98 %). Presence of two grooves for OS was noted in a single specimen (2 %). The presence of the normal and abnormal grooves for OS was clearly shown in the radiological study.

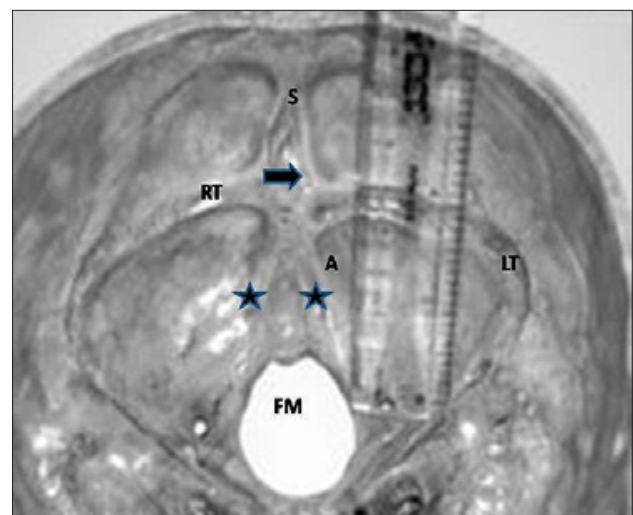
The results were tabulated in Table 1.

### Discussion

In the present study, we observed dual grooves for OS which traversed as two different limbs to end at the internal occipital

protuberance. Although conventional textbooks of anatomy mention that OS may be paired (1), in the present study we also observed an associated anomaly of the course of the superior sagittal sinus which continued as left transverse sinus, instead of the normal right transverse sinus. The presence of the two grooves for the OS signifies that there were two falx cerebelli because the OS is usually attached to the margins of each of the falx cerebelli.

A past research study in a Japanese population has shown that superior sagittal sinus drains into the right transverse sinus in 27 %, incompletely to the right in 26 %, equally to the bilateral transverse sinus in 31 %, incompletely to the left in 8 % and completely to the left in 8 % (14). As per research reports, the occipital sinus is confirmed in 82 % cases (8) In the present case, we observed a single (2 %) case of an abnormal drainage of the



**Fig. 1. Photograph of anomalous specimen showing: S – superior sagittal sinus, RT – right transverse sinus, LT – left transverse sinus, FM – foramen magnum, A – accessory groove. The grooves for the two occipital sinuses are marked with asterix (\*). The superior sagittal sinus near its lower end can be seen as bifurcated. The continuation of superior sagittal sinus into left transverse sinus is marked with arrow.**

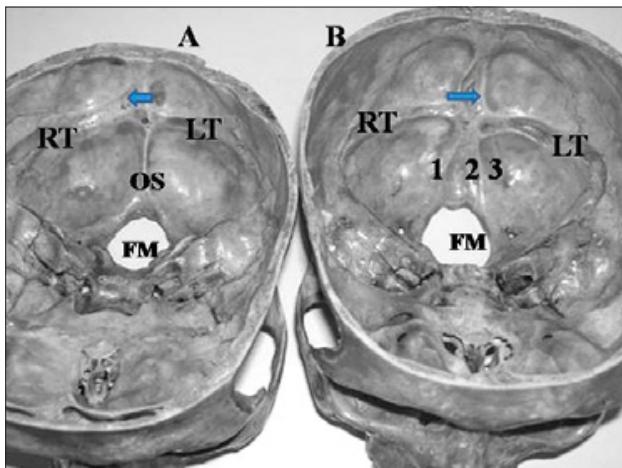


Fig. 2. A is the normal specimen showing: LT – left transverse sinus, RT – right transverse sinus, FM – foramen magnum, 1 – single groove for occipital sinus. Note the continuation of sagittal sinus as right transverse sinus marked with arrow. B is the abnormal specimen showing: LT – left transverse sinus, RT – right transverse sinus, FM – foramen magnum, 1, 2, 3 – grooves for occipital sinus. Note the continuation of sagittal sinus as left transverse sinus marked with arrow.

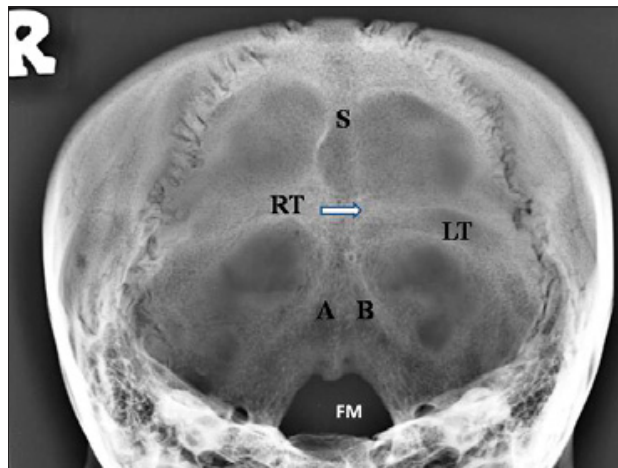


Fig. 4. Digital X-ray of the anomalous skull specimen showing: S – superior sagittal sinus, RT – right transverse sinus, LT – left transverse sinus, A & B – double grooves for occipital sinuses, FM – foramen magnum. The arrow shows the continuation of superior sagittal sinus as left transverse sinus. Note – the single midline density is replaced by two less prominent ones in the X-ray depicting the double occipital grooves.

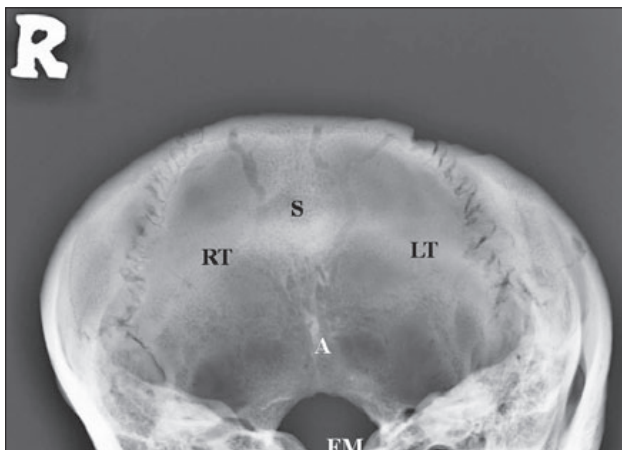


Fig. 3. Digital X ray of the normal skull showing: S – superior sagittal sinus, RT – right transverse sinus, LT – left transverse sinus, A – single occipital sinus, FM – foramen magnum.

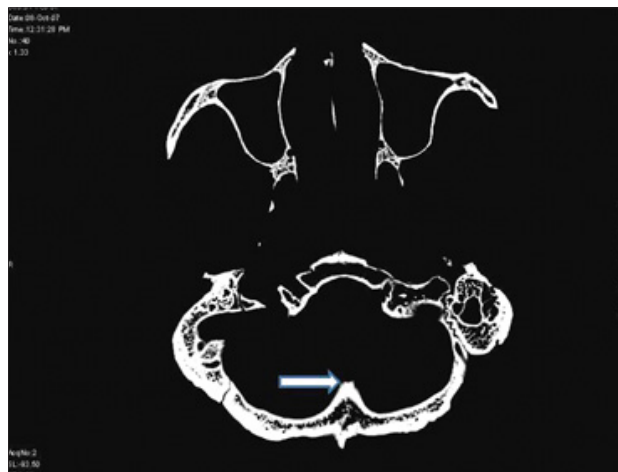


Fig. 5. CT scan (at a higher cranial level) of the normal skull showing: The single groove for the OS marked with arrow.

superior sagittal sinus into the left transverse sinus which may be regarded as a rare variation. The groove marked for dural sinuses could be easily visualized in the 3D CT images (Figs 5, 6). We believe that these findings may be beneficial for clinical purpose.

It has been documented that the anatomical changes which occur during the fetal period result in ballooning of the transverse sinuses forming the occipital and the marginal sinuses near the foramen magnum (8, 15). After birth, there is a considerable brain development and associated hemodynamic changes occur which may result in the formation of an abnormal sinus. In the present case, there was duplication of the OS along with abnormal drainage of the superior sagittal sinus which may clearly spell out some developmental defect. The prominence of the left

groove may signify a greater amount of blood flow in the left OS. Admittedly, we did not have any history of the patient to corroborate this fact.

A past study had reported triplicate falx cerebelli but it was associated with a single occipital sinus (16). According to this study a complex dural venous variation in the posterior cranial fossa is possible and that may be the reason why we also observed a complex variation of the sinuses in the occipital region. To the best of our knowledge there is no anatomico-radiological study highlighting the dual grooves for OS along with associated anomalous course of superior sagittal sinus.

The abnormal angulation or position of the dural sinuses may be a cause of embolism (17). The anomalous sinuses in the present

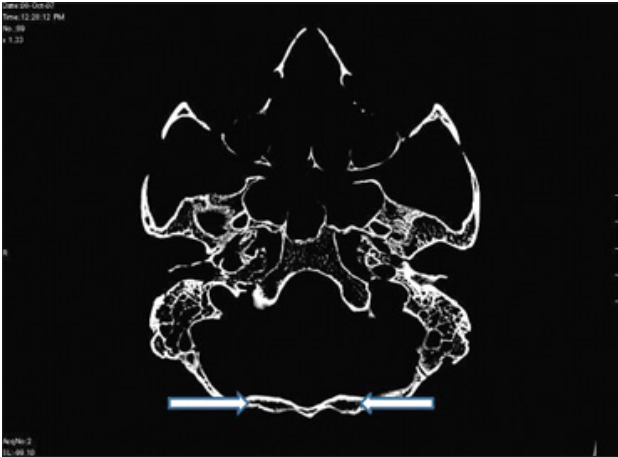


Fig. 6. CT scan (at a lower cranial level) of the anomalous skull showing: The double grooves for the OS marked with two arrows.

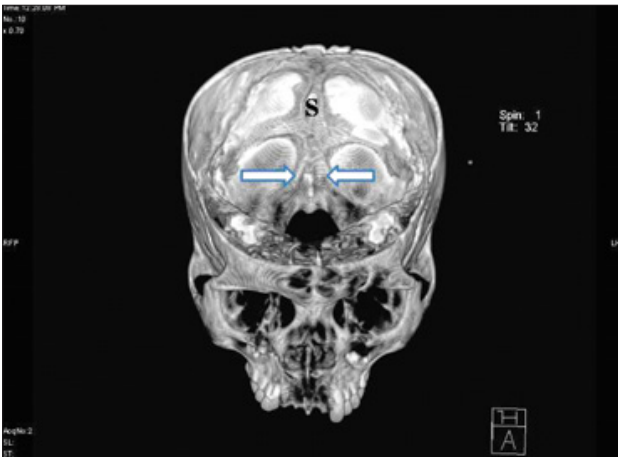


Fig. 7. Three Dimensional image of the skull showing: double grooves of OS marked with two arrows, S – sagittal sinus.

case may also be liable for such embolism. The course of superior sagittal sinus near the confluence of sinuses was also bifurcated making it liable to be affected by embolism.

During any neurosurgical operations involving the occipital region, pre-operative diagnosis of the sinus blood flow around the torcular Herophili is essential. Usually the occipital region is explored in brain tumors, cerebrovascular disorders and AV malformations (18, 19). Often the occipital screws are used in occipitocervical fusion and it is essential for the surgeon to have a clear knowledge of the sinuses and its variations (13).

Anatomical studies have described the anomalous pattern of dural venous sinuses but there are no reports to correlate it radiologically (20). Angiograms may have to be obtained for diagnosing the venous channels (8) and it is very important that the radiologists have proper anatomical knowledge of the dural venous system and its possible anomalies. In the present case, the digital and 3 dimensional image of the anomalous specimen (Figs 4, 6) depicted the double OS which may be beneficial to

radiologists. We opine that Magnetic Resonance Venography may have to be performed before any surgical procedure, to rule out the presence of any anomalous blood vessel.

## Conclusion

Honestly, we admit that a larger number of sample size would have altered the results but we highlighted the normal and abnormal anatomy of the grooves of the OS supplemented with appropriate radiological findings. We believe that the knowledge of such variations may be beneficial for academic and clinical purpose.

## References

1. **Standring S (Ed).** Gray's Anatomy. The Anatomical Basis of Clinical Practice, New York; Elsevier Churchill Livingstone, 2005: 277—281.
2. **Browning H.** The confluence of dural venous sinuses. *Amer J Anat* 1953; 93: 307—329.
3. **Bisaria KK.** Anatomic variations of venous sinuses in the region of the torcular Herophili. *J Neurosurg* 1985; 62: 90—95.
4. **Goto N, Koda M (Eds).** Blood vessels in the central nervous system [in Japanese]. Anatomical variations in Japanese. Tokyo; University of Tokyo Press, 2000: 11—39.
5. **Matsushima T, Rhoton AL Jr, Oliveira E de, Peace D.** Microsurgical anatomy of the veins of the posterior fossa. *J Neurosurg* 1983; 59 (1): 63—105.
6. **Oka K, Rhoton AL Jr, Barry M, Rodriguez R.** Microsurgical anatomy of the superficial veins of the cerebrum. *Neurosurgery* 1985; 17 (5): 711—748.
7. **Ayanzen RH, Bird CR, Keller PJ McCully FJ Theobald MR, Heiserman JE.** Cerebral MR venography: normal anatomy and potential diagnostic pitfalls. *Amer J Neuradiol* 2000; 21 (1): 74—78.
8. **Singh M, Nagashima M, Inoue Y.** Anatomical variations of occipital bone impressions for dural venous sinuses around the torcular Herophili, with special reference to the consideration of clinical significance. *Surg Radiol Anat* 2004; 26 (6): 480—407.
9. **Dora F, Zileli T.** Common variations of the lateral and occipital sinuses at the confluens sinuum. *Neuroradiology* 1980; 20 (1): 23—27.
10. **Minakawa T, Tanaka R, Koike T, Takeuchi S, Abe H.** Cerebral arteriovenous malformations associated with a straight sinus anomaly. *Neurosurgery* 1992; 31 (1): 19—24.
11. **Simoes S.** An anatomical study of the laterotrigeminal venous system. *Ann Anat* 1993; 175 (2): 115—118.
12. **Zipnick RI, Merola AA, Gorup J, Kunkle K, Shin T, Caruso SA, Haher TR.** Occipital morphology. An anatomic guide to internal fixation. *Spine* 1996; 21 (15): 1719—1724.
13. **Nadim Y, Lu J, Sabry FF, Ebraheim N.** Occipital screws in occipitocervical fusion and their relation to the venous sinuses: an anatomic and radiographic study. *Orthopedics* 2000; 23 (7): 717—719.
14. **Hirata K (Ed).** Cranium [in Japanese]. Anatomical variations in Japanese. Tokyo: University of Tokyo Press, 2000: 11—39.

- 15. Okudera T, Huang YP, Ohta T, Yokota A, Nakamura Y, Maehara F, Utsunomiya H, Uemura K, Fukasawa H.** Development of posterior fossa dural sinuses, emissary veins, and jugular bulb: morphological and radiologic study. *Amer J Neuroradiol* 1994; 15 (10): 1871–1883.
- 16. Shoja MM, Tubbs RS, Loukas M, Shokouhi G, Oakes WJ.** A complex dural venous variation in the posterior cranial fossa: a triplicate falx cerebelli and an aberrant venous sinus. *Folia Morphol (Warsz)* 2007; 66 (2): 48–51.
- 17. Iwabuchi T, Sobata E, Suzuki S, Ishihara H.** The significance of dural sinus pressure in neurological surgery — correlation with surgical position]. *No Shinkei Geka* 1983; 11 (11): 1167–1176.
- 18. Koos WT, Spetzler RF, Pendle G, Perneczky A, Lang J (Eds).** Color atlas of microneurosurgery. Stuttgart; Thieme, 1985: 125–128.
- 19. Yasui Kamiyama H (Eds).** Microsurgery of cerebral aneurysms. Niigata; Elsevier, 1985: 11–13.
- 20. Srijit D, Shipra P.** Unusual venous sinuses. *Bratisl Lek Listy* 2007; 108 (2): 104–106.

Received April 14, 2008.  
Accepted September 20, 2008.