

## COMPARATIVE ANATOMY

# The morphology of meningo-orbital foramen in south Indian population

Ashwin Krishnamurthy, Soubhagya R Nayak, Latha V Prabhu, Dil Islam Mansur, Lakshmi Ramanathan, Sampath Madhyastha, Vasudha Saralaya

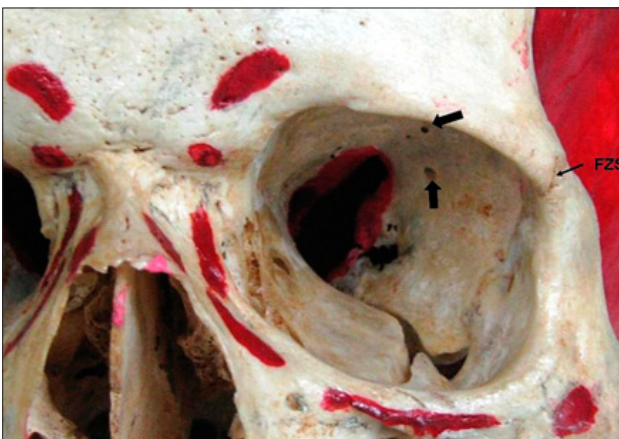
Department of Anatomy, Kasturba Medical College, Center for Basic Sciences, Bejai, Mangalore, Karnataka state, India. [anataashwin@gmail.com](mailto:anataashwin@gmail.com)

**Abstract:** When present, the meningo-orbital foramen forms an additional link between the orbit and the middle cranial fossa. It contains an arterial anastomose between the middle menigeal artery – the meningo-lacrimal branch and the lacrimal artery – the meningeal branch. The incidence of this foramen is known to vary between 28–82.9 %. In the present study of 138 dry adult skulls of South Indian origin, the meningo-orbital foramen was present in 80.4 % of population. The mean distance of the meningo-orbital foramen from the supra-orbital notch was 34.14 mm (29–38 mm) and from the fronto-zygomatic suture it was 26.10 mm (28–35 mm). The incidence and location of the meningo-orbital foramen may be of surgical significance to ophthalmologists (Tab. 1, Fig. 3, Ref. 7). Full Text (Free, PDF) [www.bmj.sk](http://www.bmj.sk).

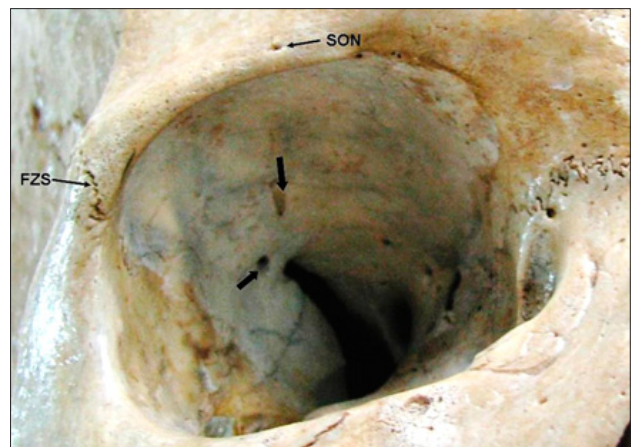**Key words:** meningo-orbital foramen, supra-orbital notch, fronto-zygomatic suture, orbit, clinical significance.

The meningo-orbital foramen is a small opening in the orbit lateral to the lateral end of the superior orbital fissure. Lacrimal foramen, foramen of Hyrtl, foramen meningo-orbitale, cranio-orbital foramen, sinus canal foramen, sphenofrontal foramen are the other names used for this in literature. The position of meningo-orbital foramen can be quite variable relative to the supe-

rior orbital fissure, laying either lateral to it, confluent with the lateral end of the fissure, or occupying any intermediate position between these extremes (1). Kwiatkowski et al (2) in their study on 92 orbits have mentioned that the minimal distance between the supraorbital notch (or foramen) and the meningo-orbital foramen was 35.0 (28–44) mm. The minimal distance from the cross-point of the entrance to the orbit and the fronto-zygomatic suture was (21.3–35.5) mm. The prevalence of the foramen varies apparently from 28 to 82.9 % (2, 3, 4). The aim of the present study was to define the incidence and location of the meningo-orbital foramen in South Indian population since anatomical



**Fig. 1.** Anterior view of the left orbit with two meningo-orbital foramen (Block arrows). FZS – Fronto-zygomatic suture.



**Fig. 2.** Anterior view of the right orbit with two meningo-orbital foramen (Block arrows). SON – Supraorbital notch, FZS – Fronto-zygomatic suture.

Department of Anatomy, Kasturba Medical College, Center for Basic Sciences, Bejai, Mangalore, Karnataka state, India

**Address for correspondence:** Ashwin Krishnamurthy, MD, Dept of Anatomy, Kasturba Medical College, Center for Basic Sciences, Bejai, Mangalore-575004, Karnataka state, India.  
Phone: +91.824.2211746, Fax: +91.824.2428183

**Tab. 1. Minimal distances between the meningo-orbital foramen and selected reference points (in millimeters). Data expressed as mean, standard deviation (in parentheses) and range.**

Minimal distance from meningo-orbital foramen to	All skulls		Male skulls		Female skulls	
	L	R	L	R	L	R
Supra-orbital notch (or foramen)	34.1(3.56) 30–37	34.2(4.91) 29–38	34.3(3.49) 32–37	34.2(3.56) 31–38	33.4(3.26) 30–35	33.8(13.3) 29–38
Fronto-zygomatic suture	25.7(3.7) 22–32	26.5(4.75) 23–35	25.7(4.2) 22–32	26.2(1.9) 23–29	26(2.1) 24–28	28.3(18.2) 24–35

variations may be of surgical significance to ophthalmologists and neurosurgeons operating on tumors in this region.

### Material and methods

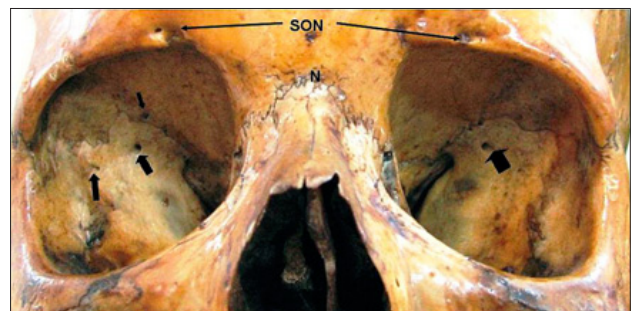
138 adult dry human skulls (99 male and 39 female) of south Indian origin were investigated. All the skulls were obtained from the collection of the Department of Anatomy, Kasturba Medical College, Mangalore, Karnataka state, India. The sex determination of the skull was based on their main morphological features. The study of meningo-orbital foramina was undertaken after determining the sex of the skull. The incidence of the foramen was studied. The minimum distances of the foramen from the supraorbital notch (or foramen) and fronto-zygomatic suture were noted.

### Results

The meningo-orbital foramen was present in 80.4 % of the orbits studied. The prevalence of the foramen in female skulls was observed to be 38.5 %, compared to 87.9 % in male skulls. 37 % of the skulls had the presence of the foramen unilaterally (either on right or on the left side) and 43.5 % skulls had it on both sides. The mean distance of the meningo-orbital foramen from the supra-orbital notch was 34.14 mm (29–38 mm) and from the fronto-zygomatic suture was 26.10 mm (28–35 mm). The results of the measurements of the minimal distances between the meningo-orbital foramen and two selected reference points are mentioned in Table 1.

### Discussion

This study examined the occurrence of meningo-orbital foramen in 138 dry adult skulls. The prevalence of the foramen in 80.4 % of orbits is almost equal to the incidence reported by Erturk et al (4). Other authors have mentioned a slightly lower prevalence. Santo Neto et al (5) have reported the presence of the foramen in 3 out of 50 orbits. Mysorekar and Nandedkar (6) examined 100 Indian skulls and reported the foramen in 34 right orbits and 36 left orbits. Kwiatkowski et al (2) in their study on 92 orbits have mentioned the incidence of the foramen to be 28 %. They have mentioned that the incidence was higher in females. Georgiou and Cassel (3) have reported the incidence of the for-



**Fig. 3. Anterior view of the orbits with multiple meningo-orbital foramen on right side (Block arrows) and single foramen (Block arrow) on the left side. SON – Supraorbital notch, N – Nasion.**

men in 49 % of skulls. From our studies on 138 skulls we are able to conclude that the incidence of the foramen appears to be region-specific as our results are much higher than that of Mysorekar and Nandedkar (6) who also reported the incidence in Indian population. Brien and McDonald (7) in their study on 60 orbits reported that 30 orbits from 22 skulls showed the presence of the foramen.

The results of the measurements of the minimal distances between the meningo-orbital foramen and the two selected reference points are comparable with those of Kwiatkowski et al (2).

The meningo-orbital foramen represents an embryonic conduit between the supraorbital division of the stapelial artery and the permanent stem of the ophthalmic artery. In adults this may be represented by a connecting vessel between the orbital branch of the anterior division of the middle meningeal artery and the lacrimal branch of the ophthalmic artery (3). The anatomy of the cranio-orbital foramen and the course of the orbital branch should be well-known to surgeons reconstructing the anterior base of the skull, the orbit after orbital base surgery, and during excision of meningiomas (4).

### References

1. Diamond MK. Homologies of the meningeal-orbital arteries of humans: a reappraisal. *J Anat* 1991; 178: 223–241.

2. **Kwiatkowski J, Wysocki J, Nitek S.** The morphology and morphometry of the so-called „meningo-orbital foramen“ in humans. *Folia Morphol* 2003; 62 (4): 323—325.
3. **Georgiou C, Cassell MD.** The foramen meningoorbitale and its relationship to the development of the ophthalmic artery. *J Anat* 1992; 180 (1): 119—125.
4. **Erturk M, Kayalioglu G, Govsa F, Varol T, Ozgur T.** The cranio-orbital foramen, the groove on the lateral wall of the human orbit, and the orbital branch of the middle meningeal artery. *Clin Anat* 2005; 18 (1): 10—14.
5. **Santo Neto H, Pentead CV, de Carvalho VC.** Presence of a groove in the lateral wall of the human orbit. *J Anat* 1984; 138: 631—633.
6. **Mysorekar VR, Nandedkar AN.** The groove in the lateral wall of the human orbit. *J Anat* 1987; 151: 255—257.
7. **Brien AO, McDonald SW.** The meningo-orbital foramen in a Scottish population. *Clin Anat* 2007; 20: 880—885.

Received April 11, 2008.  
Accepted September 20, 2008.