

CLINICAL STUDY

Prenatal diagnosis of perplexing cases of lipidoses

Ahmed L Aboul Nasr¹, Ekram M Fateen²

Gynecology and Obstetrics Department, Faculty of Medicine, Cairo University, Cairo, Egypt.
efateen@yahoo.com

Abstract: *Objective:* To present and discuss the technical, ethical and counseling difficulties that were encountered in the prenatal diagnosis of some perplexing cases of lipidoses.

Patients: Four pregnant women were referred to us for prenatal diagnosis with the diagnosis of lipidosis in an affected sibling.

Discussion: 1) It is recommended to do the enzyme assays as the first choice in all cases suspected clinically to have lipidoses in order to establish the diagnosis instead of doing invasive procedures as liver and bone marrow biopsies. 2) Activity of more than one enzyme should be assayed to confirm specific deficiency against reference values. 3) Suspected prenatal diagnosis and indefinite diagnosis should only be considered after detailed and non-directive counseling (Tab. 1, Fig. 4, Ref. 5). Full Text (Free, PDF) www.bmj.sk.

Key words: lipidosis, prenatal diagnosis, chorionic villus sampling.

Sphingolipidoses are lysosomal storage disorders leading to the accumulation of undegraded lipids that contain ceramide (composed of sphingosine and long-chain fatty acid) attached to a polar residue (1). Prenatal diagnosis can be undertaken for those with history of affected child. Direct enzyme assay in chorionic villus samples between 11–12 weeks of gestational age should provide early diagnosis (2). In all cases it is important to establish the enzyme deficiency in the proband (3).

Problems and dilemmas

During our work on prenatal diagnosis of lipidoses since 2000, some couples were referred to us with the history of affected sibling who had been clinically diagnosed but not confirmed enzymatically.

Many problems surrounded these diagnoses. First, the diagnosis was based mostly on clinical grounds and sometimes on liver or bone marrow biopsies. Second, in many cases, the affected sibling had died by the time of referral. Therefore, there was no possibility to reach and verify the final diagnosis enzymatically. Third, carrier detection by mutation analysis for parents was not available; in addition, carrier detection by enzyme activity is not reliable. Fourth problem, the mother was pregnant and seeking help in prenatal diagnosis of the current pregnancy.

We were faced with a difficult situation imposed upon us a responsibility to deal with both, ethical and scientific dilemmas

of doing (or not doing) prenatal diagnosis in a pregnant female with a suspected diagnosis of lipidoses. The ethical dilemma was to answer the question as to whether to do or not to do prenatal diagnosis. If the answer is “Yes”, then we have two possibilities after CVS and enzyme assay. In case that the tested enzyme is found to be deficient, the final diagnosis is reached. In case that the deficiency in the tested enzyme is not found, the fetus may still be affected by another type of lipidosis if the provisional clinical diagnosis was not correct from the start. If the answer is “No”, there is the risk of losing the chance of diagnosing a specific disorder prenatally. The scientific dilemma was to answer the questions as to which enzyme(s) should be tested and whether we can do more than one-enzyme assay. The answer is governed by the provisional clinical diagnosis and the amount of retrieved chorionic villi.

The aim of our work is to discuss the technical, ethical and counseling difficulties that were encountered in the prenatal diagnosis of some perplexing cases of lipidoses.

Subjects and methods

Four cases, with the total of 8 pregnancies and 8 chorionic villi samples, were studied. Patients were subjected to history taking, genetic counseling, pedigree construction, physical examination and ultrasound scan. Consanguinity was found in 3 couples (75 %).

Chorionic villus sampling was done by transabdominal route using the free-hand fine-needle aspiration method with a 20-gauge needle under continuous simultaneous ultrasound guidance. If sufficient villi were not obtained on the first attempt, a second pass was made. The chorionic villi were dissected free of maternal decidua as quickly as possible. The sample was placed in sterile medium or saline and frozen.

¹Gynecology and Obstetrics Department, Faculty of Medicine, Cairo University, ²Biochemical Genetics Department, National Research Center, Egypt

Address for correspondence: Ahmed L Aboul Nasr, Gynecology and Obstetrics Department, Faculty of Medicine, Cairo University, Cairo, Egypt.

Tab. 1. Normal values of enzymes activities.

| | In CVS | In Leukocytes |
|--------------------------------------|--------|---------------|
| β-glucosidase (μmol/gptn/h) | >1 | 1–5 |
| β-Hexosaminidase A (μmol/L/h) | >5 | 50–200 |
| β-Hexosaminidase B (μmol/L/h) | >50 | 350–3500 |
| Sphingomyelinase (nmol/gptn/h) | >1 | 1.5–5 |
| β-galactocerebrosidase (μmol/gptn/h) | >0.5 | 0.5–5 |

Chorionic villi were thawed, placed in a small Duall homogenizer and washed once with PBS, and the pellet was homogenized in a small amount of distilled water. The homogenate was diluted with distilled water up to the protein concentration of 0.8–2 mg/ml. The specific enzyme was assayed directly in this homogenate (4).

Synthetic substrates were used to measure the activities of the enzymes.

4-methylumbelliferyl-β-D-glucopyranoside (for β-glucosidase)

4-methylumbelliferyl-β-D-N,N',N"-triacetylchitotrioside (for chitotriosidase)

4-methylumbelliferyl N-acetyl-β-D-glucosaminide-6-sulphate (for β-Hexosaminidase A)

4-methylumbelliferyl-2-deoxy-D-glucopyranoside (for β-Hexosaminidase B)

Hexadecanoylamino-P-nitrophenylphosphorylcholine (for sphingomyelinase)

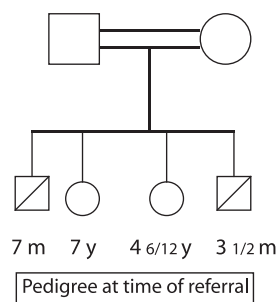
6-hexadecanoyl-4-methylumbelliferyl-β-D-galactopyranoside-6-hexadecanoyl-4-methylumbelliferone+galactose (for β-galactocerebrosidase)

All enzymes activities were measured fluorimetrically except that of sphingomyelinase which was measured colorimetrically.

Normal values of enzymes activities in the chorionic villi and in the leukocytes are shown in Table 1. Chitotriosidase activity is measured in the plasma (normal is 4–80 μmol/L/h).

Case 1

A pregnant Palestinian from Gaza aged 26 years. Her obstetric code was 4002. All deliveries were normal. She has 2 living healthy girls aged 7 and 4 1/2 years. Two boys died at the age of 7 months and 3 1/2 months. Both suffered 7m 7 y 4 6/12 y 31/2 m from hepatosplenomegaly and severe



Pedigree at time of referral neurologic manifestations. Liver biopsy was done for the second boy who died 10 minutes after the biopsy. Histopathologic diagnosis was sphingolipidosis. On coun-

seling, we explained that we would measure four enzymes in CVS to exclude or diagnose the commonest types of lipidoses. These enzymes were β-glucosidase for Gaucher disease, β-hexosaminidase A and B for GM₂ Gangliosidosis “Tay-Sachs and Sandhoff disease” and sphingomyelinase for Niemann-Pick disease types A and B. We explained that we could not diagnose or exclude Niemann-Pick type C. CVS was done the next day when the mother was at 12 weeks of gestation. The procedure was easy and yielded enough material from the first puncture. All enzymes showed normal activities. 46.7 μmol/gptn/h for β-glucosidase, 504 μmol/L/h for β-Hexosaminidase A, 3476 μmol/L/h for β-Hexosaminidase B and 45.37 nmol/gptn/h for sphingomyelinase. She delivered a healthy girl. At her second pregnancy, she presented at 15 weeks of gestation due to the curfew in Gaza and transport blockade to Egypt. Although she was in stress and the CVS was more difficult than the first time, we obtained enough material to assay four enzymes. All enzymes showed normal activities. 13.2 μmol/gptn/h for β-glucosidase, 248 μmol/L/h for β-Hexosaminidase A, 3870 μmol/L/h for β-Hexosaminidase B and 17.7 nmol/gptn/h for sphingomyelinase.

Comment

As the two tested fetuses were predicted to be normal, the definitive diagnosis of the previously affected siblings could not be extrapolated.

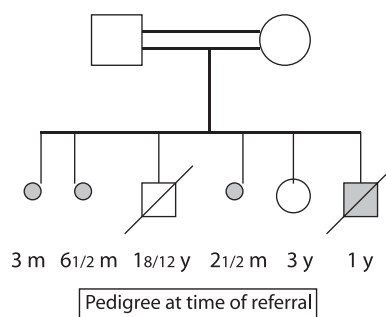
Procedures as liver and bone marrow biopsies are invasive, time-consuming, delayed and may lead to loss of opportunity to state the proper diagnosis of lipidoses.

Technically speaking, more than one enzyme could be done in a successful chorionic villus sampling yielding enough material.

It is justifiable ethically to do prenatal diagnosis where the diagnosis is not conclusive, if the patient understands not only the advantages but also the limitations and disadvantages of the procedure in a nondirective counseling.

Case 2

A pregnant Egyptian from Shobra-El-khema aged 33 years. Her obstetric code was 3031 with history of 2 cesarean sections performed to terminate her last two deliveries. She has only one living healthy 3 m 61/2 m 1 8/12 y 21/2 m 3y 1y daughter. She had a



son aged 1 year suspected on clinical grounds to suffer from Krabbe disease with hepatosplenomegaly and severe neurologic manifestations. β-galactocerebrosidase was normal (1.4 μmol/gptn/h) and chitotriosidase was high (330 μmol/l/h). Chitotriosidase is increased in Krabbe but highly elevated in Gaucher. There-

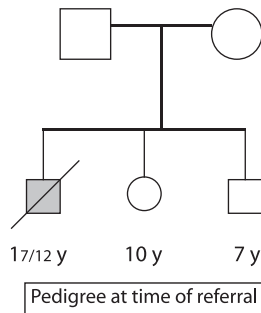
fore, Gaucher disease was suspected and β -glucosidase was planned to be done to verify Gaucher disease. However, the affected sibling died before confirmation and the mother was pregnant at 11 weeks of gestation. The two enzymes, β -galactocerebrosidase and β -glucosidase, were assayed in the chorionic villi. Enzyme activity was normal for β -galactocerebrosidase (0.52 $\mu\text{mol/gptn/h}$) and low for β -glucosidase (0.2 $\mu\text{mol/gptn/h}$). An affected fetus was diagnosed with Gaucher disease. The patient underwent surgical evacuation. CVS in the second pregnancy showed normal activities of β -glucosidase (35 $\mu\text{mol/gptn/h}$), and β -galactocerebrosidase (0.56 $\mu\text{mol/gptn/h}$) done this time as a reference enzyme. In the third pregnancy, β -glucosidase activity was normal (26.6 $\mu\text{mol/gptn/h}$) in chorionic villi. In second and third pregnancies, the patient delivered healthy newborns by cesarean sections.

Comment

If Krabbe disease is suspected clinically, it is better not to do only β -galactocerebrosidase but also chitotriosidase. If Krabbe is excluded and chitotriosidase is high, it is recommended to proceed and do assays for other lysosomal disorders.

Case 3

A pregnant Egyptian from Mansoura aged 30 years. Her obstetric code was 3002. The affected sibling was diagnosed clinically and by bone marrow as Gaucher disease type 2. He died before doing the enzyme assay. 17/12 y 10 y 7 y Chorionic villus sampling was done on the same day of referral as the patient was in her 14th week of gestation. β -glucosidase activity was low (0.068 $\mu\text{mol/gptn/h}$) in chorionic villi. β -glucosidase levels were 0.74 and 0.8 $\mu\text{mol/gptn/h}$ in the leukocytes of the mother and father respectively. The mother did not elect to terminate her pregnancy. The newborn developed hepatosplenomegaly and liver biopsy showed foamy cells. The three enzymes β -glucosidase, chitotriosidase and sphingomyelinase were assayed. Chitotriosidase was high and the other two enzymes were normal. Therefore, the diagnosis of Niemann-Pick type C was suspected. When the patient became pregnant again, we explained that Niemann-Pick type C could not be diagnosed by enzyme assay of sphingomyelinase contrary to types A and B. We discussed that β -glucosidase assay might be helpful if found low as in the previous pregnancy. However, we stressed that if β -glucosidase was found to be normal, this would not exclude the possibility of fetus being affected with Niemann-Pick type C. The couple decided to go for CVS which showed normal β -glucosidase activity (19.8 $\mu\text{mol/gptn/h}$). After delivery, the newborn was checked clinically and enzymatically and proved to be normal.

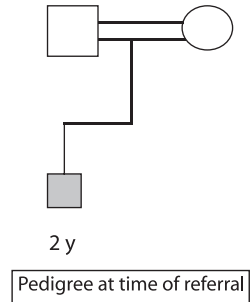


Comment

It is our finding that β -glucosidase activity is sometimes lowered in the chorionic villi of Niemann-Pick type C. This should be more studied in order to elucidate its usefulness in prenatal diagnosis.

Case 4

A pregnant Egyptian from Kafr Shokr (Kalyoubia) aged 32 years. Her obstetric code was 1001. She delivered by C.S. Her son was suspected to suffer from Gaucher disease clinically and his β -glucosidase assay showed low activity (0.23 $\mu\text{mol/gptn/h}$). His plasma 2 y chitotriosidase was high (182 $\mu\text{mol/l/h}$). He was treated as a patient suffering from Gaucher disease with replacement of imiglucerase (cerezyme). After a minimal improvement at the start, the neurologic manifestations worsened and β -glucosidase was assayed. It showed normal activity (34.9 $\mu\text{mol/gptn/h}$). The fetus was not affected by Gaucher disease and the mother continued her pregnancy. After delivery by CS, the newborn developed hepatomegaly and neurologic manifestations. The three enzymes β -glucosidase, sphingomyelinase and chitotriosidase were measured. The first two enzymes were normal, so it is neither Gaucher disease nor Niemann-Pick types A and B respectively. Chitotriosidase was elevated (500 $\mu\text{mol/l/h}$). So, the diagnosis of Niemann-Pick type C was suspected.



Comment

It is our finding that β -glucosidase assay sometimes shows low activity in leukocytes in cases with Niemann-Pick type C. This may lead to a falsely positive diagnosis of Gaucher disease and consequently influence the prenatal counseling.

Counseling for prenatal diagnosis

Counseling is all about communication between the physician and the patient. It is about devoting enough time to listening to patients, understanding their problems and explaining the available and possible options.

Counseling is not a one-way meeting i.e. listening to a monologue. The counselor talks and explains facts and options while the patient is listening. On the other hand, the counselor should listen and show understanding while the patient is complaining and/or raising her fears and problems.

Counseling should be comprehensive, non-directive and non-judgmental. It is about neither judging nor changing the mentality of others.

Counseling is about decisions that have to be made by the patient or the couple, and not decisions made by the physician or

the counselor imposed on patient, after getting to know the whole necessary information.

Recounseling is always needed after obtaining the result of prenatal diagnosis. The patient and/or the couple should not be under any pressure of committing themselves to their original decision taken before knowing the result. They should feel free to rethink all options before taking their final decision.

Recommendations

The measurement of enzyme activity is the test of choice for the diagnosis of different types of lipidoses. Pediatricians should be encouraged to go directly to do the enzyme activity for patients suspicious to have lipidoses.

Enzymatic diagnosis of the affected sibling should be the first-choice test instead of doing invasive procedures as liver or bone marrow biopsies.

Prenatal diagnosis is the option, which should be discussed and available for every pregnant female with history of a sibling affected with lipidoses. A confirmed diagnosis of the affected sibling by enzyme assay is mandatory for proper and exact prenatal diagnosis.

Gaucher disease is the commonest type of lipidoses in Egypt. However, if Gaucher disease and/or Niemann-Pick are suspected in an affected child, the three enzymes namely, β -glucosidase,

sphingomyelinase and chitotriosidase should be done simultaneously for better evaluation of the case and to exclude the possibility of Niemann-Pick disease.

Chitotriosidase is an important enzymatic marker in all cases of hepatomegaly accompanied with neurologic manifestation.

Because of the clinical heterogeneity and relative rarity of the disease, every patient is a potential source of valuable scientific information that offers the prospect of significant clinical returns (5).

References

1. **Zschocke J, Hoffmann GF.** Vademecum Metabolicum. Manual of metabolic paediatrics. Schattauer 2004.
2. **Aboul Nasr A, Fateen E.** Prenatal diagnosis of lipidoses using chorionic villus sampling (CVS): an Egyptian experience. *Laboratorin Medicina* 2002; Suppl.: 38–39.
3. **Besley G, Wraith JE.** Lysosomal disorders. *Current Pediatrics* 1997; 128 (7): 134.
4. **Wenger DA, Williams C.** Screening for lysosomal disorders. 587–617. In: *Hommes FA, Wiley-Liss (Eds). Techniques in diagnostic human biochemical genetics: A laboratory manual.* New York 1991.
5. **Weinreb N, Aggio M, Andersson H et al.** Gaucher disease type 1: Revised recommendations on evaluations and monitoring for adult patients. *Semin Hematol* 2004; 41 (4 Suppl 5): 15–22.

Received May 19, 2008.
Accepted September 20, 2008.