

CASE REPORT

Isolated extra-medullary relapse of acute leukemia following allogeneic bone marrow transplantation

Al Sabty Firas, Demeckova E, Bojtarova E, Czako B, Hrubisko M, Mistrik M

Department of Hematology and Transfusion Medicine, Faculty of Medicine, University Hospital, Comenius University, Bratislava, Slovakia. firasalsabty@yahoo.com

Abstract: Isolated extramedullary relapse (IEMR) of acute leukemia (AL) after allogeneic bone marrow transplantation (BMT) is a rare occurrence. It is seen more commonly after BMT than after conventional chemotherapy (CHT) alone. We describe the natural history and response to treatment in four patients with IEMR following allogeneic BMT. The results indicate a stronger graft-versus-leukemia (GVL) effect in the marrow than in the peripheral tissues (Fig. 4, Ref. 13). Full Text (Free, PDF) www.bmj.sk.

Key words: isolated extra-medullary relapse, acute leukemia, allogeneic bone marrow transplantation, GVL effect.

The curative effect of allogeneic BMT for AL is attributed to the intensive conditioning CHT with or without radiotherapy, as well as an immune-mediated GVL effect. A different pattern of relapse has been observed after allogeneic BMT for patients with AL. Compared with treatment using conventional CHT alone; IEMR appears to be seen more commonly after allogeneic BMT. Extramedullary relapse is a recurrence of leukemia in sites other than the bone marrow. While a full donor's haematopoiesis may be retained, prolonged morphological remission has been observed in the recipient's bone marrow. There appears to be a population of leukemic cells with an affinity to extra-medullary tissues. The failure of the leukemic clone to repopulate the recipient's marrow suggests the presence of a more profound GVL effect in the marrow environment. The optimal treatment for IEMR of leukemia following allogeneic BMT remains uncertain. In the case of IEMR following BMT, the leukemia may still be responsive to further treatment with CHT and/or radiotherapy. With the preservation of donor's haematopoiesis in the recipient's marrow, the use of intensive CHT followed by donor lymphocyte or stem cell re-infusion is a promising option (12, 13). The prognosis is poor in general, but prolonged survival has been observed in some of these patients. In a series of 106 patients with AL who underwent allogeneic BMT in our institution, we reported four cases of IEMR after BMT (cumulative incidence 3.7 %).

Clinical cases

Case 1: A 50 year-old female presented with acute myeloblastic leukemia (AML-M5), intermediate risk – normal karyotype, she received induction and consolidation CHT with the achievement of complete haematological and morphological remission, followed by HLA-matched related donor allogeneic stem cell transplantation (SCT), preceded by myeloablative conditioning regimen (busulfan and cyclophosphamide), with post transplantation graft versus host disease (GvHD) prophylaxis. Successful engraftment was achieved with no features of GvHD. On day +119 of BMT she developed IEMR in the skin of left anterior chest wall (Fig. 1a) (started as erythematous eruption, progressed to multiple firm lesions on the erythematous base on the left anterior chest wall, without local lymphadenopathy). Mammography and ultrasound of left breast, with only thickening of skin and no local axillary lymphadenopathy. Skin biopsy confirmed the local infiltration of myeloblast M5. Bone marrow (BM) aspiration and complete blood picture (CBP) showed complete haematological and morphological remission (with 1 % blast in bone marrow), 95 % donor chimerism, minimal residual disease (MRD) 1.5 % blast. Ultrasound of abdomen and CT scan of lung showed no infiltration of other organs. Reinduction CHT was given with complete regression of skin infiltrate (Fig. 1b). She is still alive. Further plan is donor leukocyte infusion (DLI).

Case 2: A 41-year-old female with the diagnosis pre B-acute lymphoblastic leukemia (ALL) (philadelphia positive-high risk), with multiple cytogenetic abnormalities. She was treated with combined CHT in induction of remission with the achievement of complete haematological and cytogenetic remission, followed by allogeneic HLA-matched unrelated donor ABO compatible stem cell transplantation. Conditioning with total body irradiation

Department of Hematology and Transfusion Medicine, Faculty of Medicine, University Hospital, Comenius University, Bratislava, Slovakia

Address for correspondence: Al Sabty Firas, MD, Dept of Hematology and Transfusion Medicine, Faculty of Medicine, University Hospital, Antolska 11, SK-851 07 Bratislava 5, Slovakia.
Phone: +421.2.68672893, Fax: +421.2.63531592

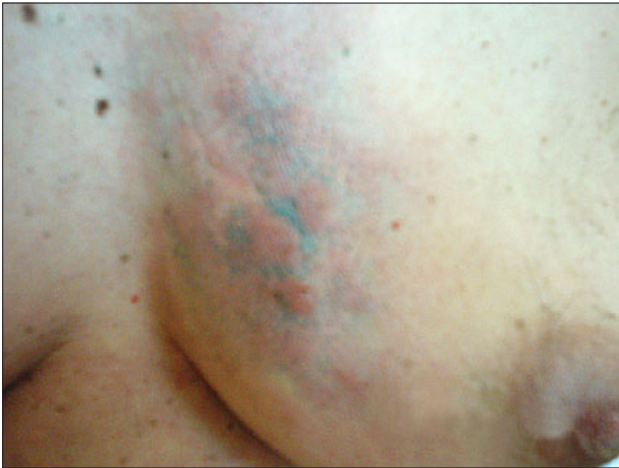

Fig. 1a. Isolated extramedullary relapse of AML in the skin of anterior chest wall before treatment.

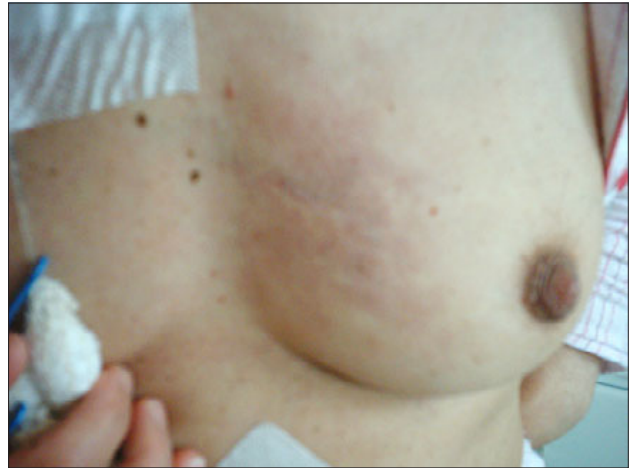

Fig. 1b. Isolated extramedullary relapse of AML in the skin of anterior chest wall after treatment.

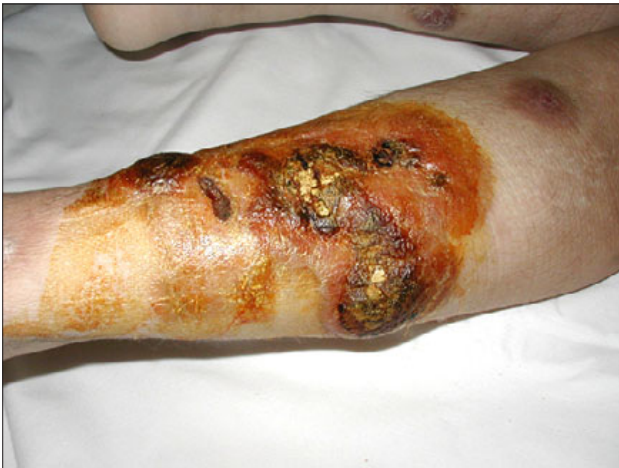

Fig. 2a. Isolated extramedullary relapse of ALL in the skin of lower limbs before treatment.

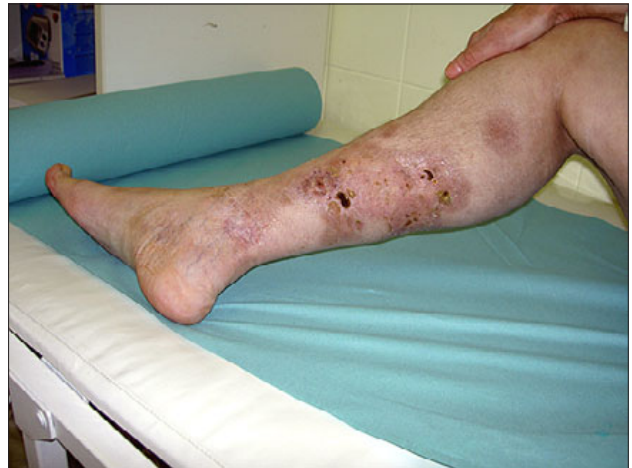

Fig. 2b. Isolated extramedullary relapse of ALL in the skin of lower limbs after treatment.

(TBI), Cyclophosphamide (Cy), antithymocyte globulin (ATG), with post transplantation GvHD prophylaxis. On day +245 of BMT she developed chronic GvHD of the skin, mucous membrane and the liver; treated with corticosteroid and mycophenolate mofetyl. On day +615 of BMT, she developed IEMR in skin of lower limbs (Fig. 2a) (started as bilateral infiltrative lesion, dark red in colour, dry, firm, fixed on the underlying tissues, with skin defect, progressive bilateral leg edema mainly on the left side). Skin biopsy confirmed the lymphoblast infiltration. CBP and BM aspiration, with full haematological and morphological remission, complete donor chimerism. Due to cardiac insufficiency and complex cardiac arrhythmias, treated with corticosteroid and imatinib 800mg/day, with initial response (Fig. 2b). Due to progression of extramedullary relapse with molecular relapse, reinduction CHT was given; but she died shortly after the induction due to sepsis and multiorgan failure. Post-relapse survival 23 weeks.

Case 3: A 26-year-old healthy female at 8 weeks of gestation diagnosed to have T-ALL (high risk). The pregnancy was terminated and induction CHT was delivered with the achievement of complete remission, followed by HLA-matched unrelated donor ABO compatible stem cell transplantation, preceded by TBI+Cy+ATG as a conditioning regimen, with post transplantation GvHD prophylaxis. Successful engraftment was achieved with no features of GvHD. On day +78 after allogeneic SCT the patient developed focal epilepsy with transient loss of consciousness and vomiting, cerebrospinal fluid (CSF) examination showed 29% lymphocytes. Immunophenotype of CSF confirmed the central nervous system (CNS) relapse. CT scan of brain was negative. EEG decrease alpha wave. CBP and BM examination revealed complete haematological, cytogenetic and morphological remission. MRD negative. Blood group and chimerism were of donor type. The patient was treated with intrathecal CHT, after 4 doses the CSF became without malignant cells. Reinduction

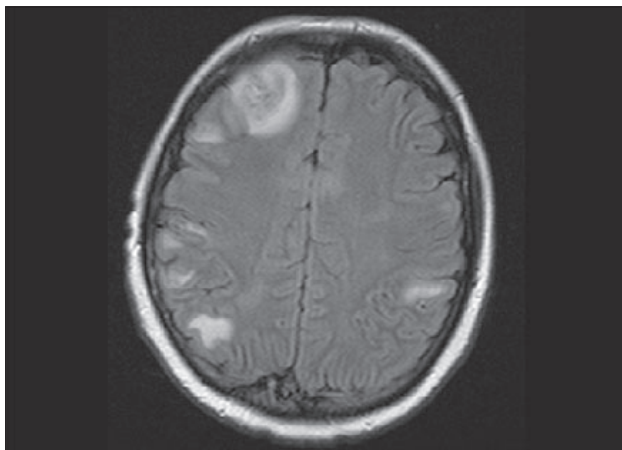


Fig. 3. MRI of brain showing CNS leukemic infiltrations.

CHT started. CSF examination revealed high protein contents so MRI of brain was done with the picture of multiple lesions in grey matter (infra and supratentorial (Fig. 3). CNS Radiotherapy was delivered, but the patient's general condition deteriorated and she died 129 days after allogeneic BMT in hypoplasia and sepsis after reinduction. Post-relapse survival 7 weeks.

Case 4: A 27-year-old female presented with common T-ALL, normal karyotype. She received induction CHT, first and second intensification CHT and CNS radiotherapy, followed by allogeneic SCT from HLA-matched related ABO compatible donor in first complete remission (conditioning regimen TBI + CY). Successful engraftment, complete remission and donor chimerism were achieved. Chronic GvHD limited to skin (face and mouth), liver, treated with corticosteroid. On day +345 after SCT, the patient developed a mass in left breast, which gradually increased in size, with no pain, no discharge, palpable axillary lymph node on the left side. Mammography showed hypogenic mass with axillary lymph node of 2 cm in size. CT scan of chest showed a 10-cm mass in left breast with 1 lymph node in left axilla of 3 cm in size. Core biopsy from the left breast confirmed the diagnosis of extramedullary relapse (lymphoblast infiltration). CT scan of lung and abdomen showed no infiltration of other organs. CBP and BM aspiration revealed no progression of the disease. Complete chimerism of donor type was found. The patient was treated with local radiotherapy of breast and axilla (12 doses), with complete regression. On day +519 after SCT the patient developed leg edema. Transthoracic and transesophageal echocardiography showed pericardial effusion with decreased ejection fraction to 48 %, a picture of non-obstructive hypertrophic cardiomyopathy (infiltrative CMP) (Fig. 4). MRI of the heart with a picture suspected of myocardial infiltration (infiltrate in the anterior and postero-lateral wall of left ventricle and free wall of right ventricle), so endomyocardial biopsy was performed which confirmed myocardial infiltration (T-lymphoblast infiltrate shown by immunohistochemistry). The patient was treated with systemic CHT (daunorubicin) with com-

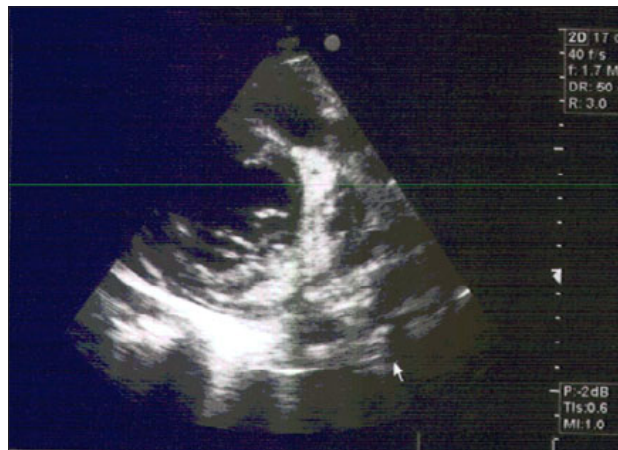

Fig. 4. Echocardiography showing infiltrative cardiomyopathy.

plete regression of myocardial infiltrate. On day +707 after SCT the patient developed relapse in kidneys and BM and she died after a short period. Post-relapse survival 53 weeks.

Discussion

20–50 % of patients with AL relapse after allogeneic BMT. Factors that predict relapse are status of disease at the time of BMT, T cell-depleted marrow transplantation, and absence of GVHD (1, 2). It is now well-known that relapse of AL is less frequent after allogeneic BMT than after autologous or syngeneic BMT and this is attributed to GVL effect that occurs after allogeneic BMT. IEMR in AL patients, excluding CNS relapse, after BMT is rare, and is detected in 0.65 % of those with AL5. It has been reported that recurrence in the bone marrow occurs within 1 to 12 months of the emergence of IEMR and the average survival is 10 months (5).

The main sites of extramedullary recurrence are CNS and the skin (in the form of leukemia cutis), although it may rarely occur also in other sites like the neck, body cavity, sacral area, spine, limbs, nasopharynx, paranasal sinusoid, bladder, perineum, breast, testis, chest wall, stomach, peritoneal cavity, and pleural cavity (5, 6).

Predisposing factors of IEMR in leukemia are known to be the delayed diagnosis of leukemia, chromosomal aberrations, which include t(8;21), inv(16), MLL rearrangement, expression of certain cell surface markers by leukemic cells such as the expression of adhesion molecules, NCAM (CD56), CD15, the expression of T cell markers CD2, CD4 and CD7 and M4 and M5 by the FAB classification (6, 8). Adhesion molecules, such as CD56 and CD15 are thought to play an important role in the adhesion of leukemia cells to other interstitial tissues and the frequent expressions of CD56, CD15, and T cell markers in IEMR occurring in rare sites have been reported (2).

Possible mechanisms of extramedullary relapse without recurrence in the bone marrow have been suggested. One hypothesis is that recurrence occurs in sites that could be inaccessible

to CHT or the GVL effect, such as in the CNS. In those sites, the effect of anti-cancer drugs or immune effector cells of the patient or donor could be much diminished due to the presence of a barrier, or there may exist microenvironments, in which immune cells or cytokines cannot function effectively against malignant cells. One randomized study reported a higher incidence of relapse of AML among patients who received the busulfan plus cyclophosphamide regimen as opposed to cyclophosphamide plus total body irradiation regimen (9), while another study failed to show such a difference¹⁰. Inter-patient variation in busulfan absorption and metabolism may result in low plasma levels of the drug and poor tissue penetration in a proportion of patients and may explain the apparent high incidence of extramedullary relapse¹¹. Late extramedullary relapses of AL have also been reported after allogeneic BMT prepared with TBI containing regimens (12, 13). Another hypothesis is that the anti-tumor effect of GVL and immune surveillance system is not as effective in extramedullary sites as they are in bone marrow (7) In other words; the anti-tumor effect of activated cytotoxic T lymphocytes can be relatively strong in the haemopoietic tissues. However, the mobilization of activated T lymphocytes might be delayed, or activated T lymphocytes might be inhibited at the site of extramedullary relapse.

IEMR is usually accompanied by BM relapse within 1 year of allogeneic BMT, and is known to be a very poor prognostic factor (6, 8). The fact that BM in patients with IEMR is in molecular genetic remission suggests that the GVL effect remains, at least in BM. This observation suggests that as opposed to patients with recurrence in the BM a more significant treatment effect could be expected in those with IEMR, namely by developing a treatment that enhances the GVL effect in extramedullary sites.

Conclusion

The results indicate a stronger GVL effect in the marrow than in peripheral tissues. IEMR was associated with a longer post-relapse survival and better prognosis than marrow-only relapse. The treatment of IEMR following allogeneic BMT is still controversial due to the small number of patients; therefore further studies with larger numbers of patients are warranted.

References

- 1. Giralt SA, Champlin RE.** Leukemia relapse after allogeneic bone marrow transplantation: a review. *Blood* 1994; 84: 3603—3612.
- 2. Barrett AJ, Horowitz MM, Gale RP et al.** Marrow transplantation for acute lymphoblastic leukemia: factor affecting relapse and survival. *Blood* 1989; 74: 862—871.
- 3. Zittoun RA, Mandelli F, Willemze R et al.** Autologous or allogeneic bone marrow transplantation compared with intensive chemotherapy in acute myelogenous leukemia. *New Engl J Med* 1995; 332: 217—223.
- 4. Fefer A, Sullivan KM, Weiden P et al.** Graft versus leukemia effect in man: the relapse rate of acute leukemia is lower after allogeneic than after syngeneic marrow transplantation. *Prog Clin Biol Res* 1987; 244: 401—408.
- 5. Byrd J, Edenfield W, Shields D, Dawson N.** Extramedullary myeloid cell tumors in acute nonlymphocytic leukemia: a clinical review. *J Clin Oncol* 1995; 13: 1800—1816.
- 6. Yener K, Kenneth B, David P et al.** Extramedullary tumors of myeloid blasts in adults as a pattern of relapse following allogeneic bone marrow transplantation. *Cancer* 1999; 85: 608—615.
- 7. Dermime S, Mavroudis D, Jiang Y et al.** Immune escape from a graft-versus-leukemia effect may play a role in the relapse of myeloid leukemias following allogeneic bone marrow transplantation. *Bone Marrow Transplant* 1997; 19: 989—999.
- 8. Byrd JC, Weiss RB, Arthur DC et al.** Extramedullary leukemia adversely affects hematologic complete remission rate and overall survival in patients with t(8;21)(q22;q22): results from Cancer and Leukemia Group B 8461. *J Clin Oncol* 1997; 15: 466—475.
- 9. Blaise D, Maraninchi D, Archimbaud E et al.** Allogeneic bone marrow transplantation for acute myeloid leukemia in first remission: a randomized trial of a busulfan-cytosine versus cytosine-total body irradiation as preparative regimen. *Blood* 1992; 79: 2578—2582.
- 10. Ringdén O, Ruutu T, Remberger M et al.** A randomized trial comparing busulfan with total body irradiation as conditioning in allogeneic marrow transplant recipients with leukemia. *Blood* 1994; 83: 2723—2730.
- 11. Hassan M, Ljungman P, Bolme P et al.** Busulfan bioavailability. *Blood* 1994; 84: 2144—2150.
- 12. Lawson SE, Darbyshire PJ.** Use of donor lymphocytes in extramedullary relapse of childhood acute lymphoblastic leukaemia following bone marrow transplantation. *Bone Marrow Transplant* 1998; 22: 829—830.
- 13. Fleming DR, Greenwood MF, Garrison J et al.** Lymphocyte infusion for delayed extramedullary relapse of acute leukemia following bone marrow transplantation. *Leuk Lymphoma* 1996; 21: 525—528.

Received April 8, 2008.

Accepted June 16, 2008.