

CASE REPORT

Retained hand function following transection of the ulnar nerve

Tubbs R Shane^{1,2}, Loukas M^{3,4}, Shoja MM⁵, Doyle S⁶, Wellons III JC¹*Section of Pediatric Neurosurgery, Children's Hospital, Birmingham, AL. rstubbs uab.edu*

Abstract: Generally, complete transection of a peripheral nerve results in cessation of function of the muscles innervated by such a nerve. We report a case of a child with a traumatically transected ulnar nerve who retained complete hand function. The authors believe this retention of hand function was due to a Martin-Grüber anastomosis, which is an interneural communication between the ulnar and median nerve in the forearm. Such neural variations should be considered when evaluating injuries to the nerves of the upper extremity (Fig. 2, Ref. 5). Full Text (Free, PDF) www.bmj.sk.

Key words: upper extremity, trauma, variation

Unusual presentations following peripheral nerve injury can often be explained by anomalous neural intercommunications. One such variation of the peripheral nerves of the upper extremity is the Martin-Grüber anastomosis (MGA). This connection is found between the median and ulnar nerves in the forearm. We report a child with complete transection of the ulnar nerve at the elbow who continued to have proper function of the muscles served by this nerve following this injury.

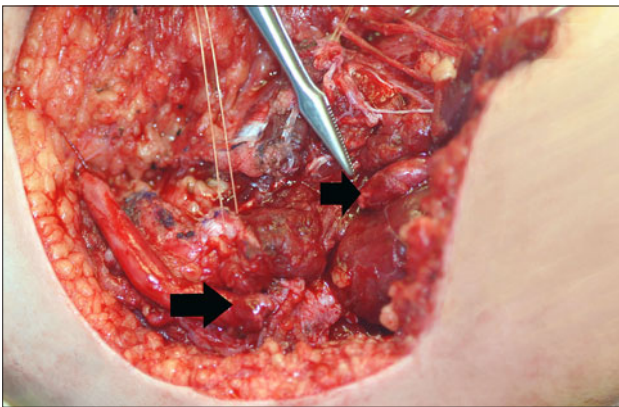


Fig. 1. Intraoperative image noting the complete transection of the ulnar nerve. The distal cut ends of the nerve are seen at the arrows.

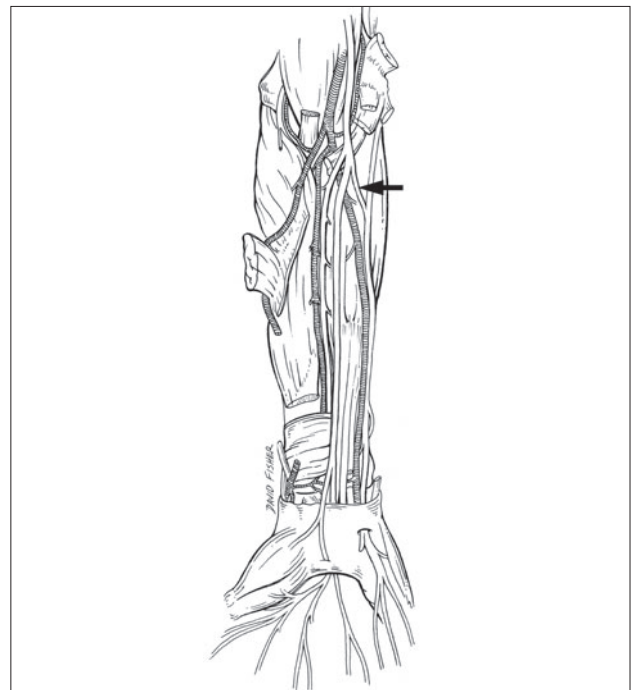


Fig. 2. Schematic drawing of the probable Martin-Grüber anastomosis (arrow) in the patient described herein.

Case report

We present a nine-year-old child who completely transected his ulnar nerve just distal to the medial epicondyle via trauma (Fig. 1). On exam, he maintained function of the entire flexor digitorum profundus (FDP) and ulnarly innervated muscles of the hand (e.g. abduction and adduction of the digits were normal). There was, however, sensory loss over the fifth digit and medial side of the fourth digit. The most likely explanation for such motor preservation is a (MGA) (Fig. 2).

¹Section of Pediatric Neurosurgery, Children's Hospital, Birmingham, AL, ²Department of Cell Biology, University of Alabama at Birmingham, ³Department of Anatomical Sciences, St. George's University, Grenada, ⁴Department of Education and Development, Harvard Medical School, Boston, MA, ⁵Tuberculosis and Lung Disease Institute, Tabriz Medical University, Tabriz, Iran, ⁶Pediatric Orthopedics, Children's Hospital, Birmingham, AL

Address for correspondence: R. Shane Tubbs, PhD, Pediatric Neurosurgery, Children's Hospital, 1600 7th Avenue South ACC 400, Birmingham, AL 35233.
Phone: +205.939.9914, Fax: +205.939.9972

Discussion

MGA is a communicating branch between the median and ulnar nerves found at variable distances distal to the elbow and is reported to occur in up to 15 % of the population (Bergman et al., 1984). Such communications, however, are normally found in baboons and many monkeys (Botte, 2003). These connections normally occur between the flexor digitorum superficialis and FDP muscles (Botte, 2003). The MGA may present as a diagnostic challenge (Kingery et al, 1996). The communication in our patient most likely occurred in the very proximal forearm as the FDP to the fourth and fifth digits was functional.

Van Tieghem et al (1987) reported two incomplete transections of the ulnar nerve proximally in which both patients continued to have some hand function. Congruently, Komar et al (1978) reported complete transection of the median nerve without paresis in a patient thought to have a MGA variation. Such a communication, as seen in our patient, may represent a pathway for redirecting nerve fibers that were not completely sorted in the brachial plexus (Botte, 2003).

Conclusion

Knowledge of MGA variations when treating patients with peripheral nerve lesions will make interpretation of uncommon presentations following nerve injury more precise.

References

1. **Bergman RA, Thompson SA, Afifi AK.** Catalog of Human Variation. Baltimore, Urban & Schwarzenberg 1984 127 pp.
2. **Botte MJ.** Nerve Anatomy in Surgical Anatomy of the Hand and Upper Extremity Doyle JR, Botte MJ (Eds). Philadelphia, Lippincott Williams & Wilkins 2003, 236 pp.
3. **Kingery WS, Wu PBJ, Date ES.** An unusual presentation of a traumatic ulnar mononeuropathy with a Martin-Gruber anastomosis. Muscle & Nerve 1996; 19: 920–922.
4. **Komar J, Szegvari M, Gloviczky Z, Szanto A.** Traumatic section of the median nerve without complete motor paresis: the Martin-Gruber anastomosis. Nervenarzt 1978; 49: 697–699.
5. **van Tieghem J, Vandendriessche G, Vanhecke J.** Martin-Grüber anastomosis: the explanation for late diagnosis of severe ulnar nerve lesions at the elbow. Electromyogr Clin Neurophysiol 1987; 27: 13–18.

Received December 14, 2007.

Accepted April 18, 2008.

SCIENTIFIC AND CLINICAL INFORMATION

Modern trends in the pediatric ophthalmology

Gerinec A

Department of Pediatric Ophthalmology, Children's Teaching Hospital, Comenius University in Bratislava, Slovakia

Pediatric ophthalmology has today very intensive development in many attributes of its pathology and in the entire care. In the paper has been reported about author 35 years experience with many indicators of the progress and the advancement in the pediatric ophthalmology

In the epidemiology has recorded the decrease of infectious eye diseases, malnutrition, but the increase of allergy, congenital anomalies, myopia and ROP in extremely low birth weight infants has reported.

In diagnostics have rapid development laboratory methods of molecular genetics, immunology and biochemistry. The identification of many gene mutation of ocular diseases contributes permanent to etiological diagnostics. Also innovation in devices technique is very important.

Treatment possibilities are increasing by introducing the new pharmacological and microsurgical methods. The substantially improvement of treatment effectiveness is especially in retinopathy of prematurity, pediatric glaucomas, cataract, malignancies and allergies. The minimal therapeutic progress is in optic nerve neuropathies, retinal dystrophies and stationary eye anomalies.

In the prophylaxy are introduced screening methods of congenital cataract in the newborn, visual function and amblyopia in pediatrician, genetic counselling and interdisciplinary cooperation in systemic diseases with ocular manifestation.

This study was presented on the Meeting of the Slovak Medical Society, on the March 3, 2008 in Bratislava.