

## SHORT COMMUNICATIONS

## Glucose transporter type 1 (GLUT-1) deficiency

Bzduch V, Sykora P, Behulova D, Kolnikova M, Klcova V

First Department of Pediatrics, Department of Child Neurology, Department of Clinical Biochemistry, Comenius University Children's Hospital, Bratislava, Slovakia. bzduch@gmail.com

In 1991, de Vivo and colleagues reported novel clinical syndrome characterized by and infantile-onset epileptic encephalopathy, caused by primary deficiency of glucose transporter into the brain (1). Since that time, more than 100 patients have been identified in the USA and elsewhere throughout the world. Early diagnosis of this condition is important, because an effective treatment is available by means of a ketogenic diet. Here we present the first case of glucose transporter type 1 (GLUT-1) deficiency syndrome in Slovakia.

## Case report (2)

A boy of unrelated parents presented at the age of 2,5 months with tonic seizure and shallow respiration, flushing, winking, salivation, smacking, lasted approximately 15 second. Two days later after DiTePer vaccination seizures were longer and more intensive. EEG was without pathology. At the age of 6 months blood and cerebrospinal fluid (CSF) glucose was estimated concurrently. The plasma glucose was 5.8 mmol/l whilst the CSF glucose only 1.1 mmol/l. Importantly the lactate was shown to be normal at 0.86 mmol/l. Ratio of CSF/blood glucose was 0.19, the normal value being 0.6. The combination of infantile seizures with unexplained low-glucose concentrations in CSF (hypoglycorrachia) indicated a defect in glucose transport into the brain termed GLUT-1 deficiency syndrome. DNA analysis confirmed the diagnosis of this syndrome by mutation in the SLC2A1 gene. A ketogenic diet was introduced at 6 months of age (3). Ketosis was initiated by fasting, monitored by bedside blood glucose and 3-OH butyrate determination. A 3:1 (fat : non-fat) ketogenic meal plan was designed and the ratio of the diet was adjusted as needed to produce ketosis (3-OH butyrate 3.0 - 5.87 mmol/l). Ingredients for the ketogenic formula were Basic - Ch (Milupa) and MCT oil and Calogen (SHS) (4). The patient tolerated the ketogenic formula well and remained seizure-free.

## Discussion

GLUT-1 deficiency syndrome is caused by a defect in the glucose transporter that exclusively mediates glucose transport across the blood-brain barrier. A constant feature is the presence of hypoglycorrachia, with a CSF/blood glucose ratio of less than 0.33. Patients present with seizures, developmental delay, secondary microcephaly, and a complex motor disorders. As the ketogenic diet currently represents the only effective treatment for GLUT-1 deficiency (also the treatment of choice for pyruvate

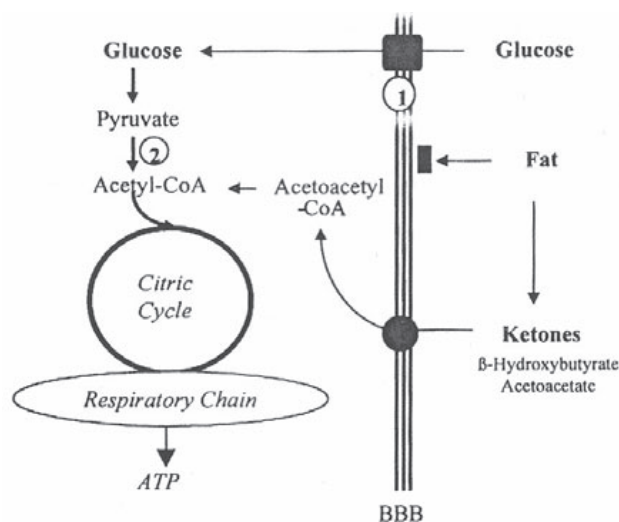


Fig. 1. Ketosis and brain energy metabolism (4).

dehydrogenase deficiency) (Figure 1) the need to introduce the diet early to prevent irreversible neuropathology is compelling.

## Conclusion

GLUT-1 deficiency is a treatable condition, which is still underdiagnosed. It should be suspected in children with unexplained neurological disorders associated with epilepsy and developmental delay and confirmed by a lumbar puncture.

This study was presented at the Meeting of the Slovak Medical Society, on the February 18, 2008, in Bratislava.

## References

1. De Vivo DC, Trifiletti RR, Jacobsen RI et al. Defective glucose transport across the blood-brain barrier as a cause of persistent hypoglycorrachia, seizures, and developmental delay. *New Eng J Med* 1991; 325: 703–709.
2. Bzdúch V, Behúlová D, Klčová V, Sýkora P. The First Case of Glucose Transporter Type 1 (GLUT-1) Deficiency Syndrome in Slovakia. *Čes Slov Pediat* 2006; 61: 586–588.
3. Klčová V. Ketogenic diet. *Nutricia s.r.o.* 2005; 47 p.
4. Klepper J, Leindecker B, Bredahl R et al. Introduction of a ketogenic diet in young infants. *J Inherit Metab Dis* 2002; 25: 449–460.

Received March 24, 2008.  
Accepted March 28, 2008.