

CLINICAL STUDY

Outcomes after surgical repair of sinus venosus atrial septal defect in children

Sojak V¹, Sagat M², Balazova E², Siman J³

*Department of Cardiothoracic Surgery, Leids Universitair Medisch Center, Leiden, the Netherlands.
v.sojak@lumc.nl*

Abstract: *Objectives:* Review of outcomes for children undergoing surgical repair of sinus venosus atrial septal defect (SVASD) and proposal of optimal treatment strategy.

Background: Unlike secundum-type atrial septal defect (ASD II), surgical correction of SVASD is more challenging and carries higher risk of postoperative complications. Several surgical techniques have been proposed to avoid them; however, the data on long-term follow-up are limited.

Methods: Between 1992–2005, 85 patients underwent surgery for SVASD at our institution. 78 and 7 operations were performed through full and partial sternotomy, respectively. The mean age was 7.7 years (2 months – 19 years). All patients with SVASD and no partial anomalous pulmonary venous drainage (PAPVD) or PAPVD in right atrium (n=24) underwent the single-patch repair. Among patients with SVASD and PAPVD in SVC, 22 and 39 patients underwent intracaval baffle and Warden procedure, respectively. Clinical, electrocardiographic and echocardiographic follow-ups were available for all patients.

Results: There were no deaths, reoperations, residual atrial septal defects and pulmonary vein stenosis. Two patients had SVC stenosis. Permanent arrhythmias were noted in 24 patients (28.2 %). The rate of new arrhythmias in the intracaval baffle and Warden subgroup was 54.6 % vs 23.1 % (p=0.01). Moreover, two and one patient from the intracaval baffle subgroup receive antiarrhythmics and had a pacemaker implanted, respectively.

Conclusion: Surgical treatment of SVASD is associated with excellent results and minimal morbidity. The Warden procedure is preferred in patients with SVASD and PAPVD in SVC because of lower incidence of postoperative arrhythmias (Tab. 1, Fig. 4, Ref. 23). Full Text (Free, PDF) www.bmj.sk.

Key words: heart defects, septal defects, pulmonary vein anomalies, arrhythmias.

Sinus venosus atrial septal defect (SVASD) is an interatrial communication usually in the region of the superior sinoatrial junction near the superior vena cava (SVC) orifice, but rarely posterior to the fossa ovalis that is near neither to caval orifice, nor in the region of the inferior sinoatrial junction near the inferior vena cava (IVC) orifice (1). In about 90% of patients, it is associated with partial anomalous pulmonary venous drainage (PAPVD) entering the right atrium (RA) or SVC. Unlike secundum-type atrial septal defects (ASD II), these lesions cannot be treated by interventional cardiology because of the location of SVASD and frequent association with PAPVD. The basic principle of repair is the redirection of PAPVD through the intera-

trial communication into the left atrium (LA). In contrast to ASD II, the repair of SVASD has been more challenging and associated with a higher risk of complications since the earliest reports (2–4). A number of surgical modifications have been proposed to avoid them; however the data on long-term outcome after surgical repair are limited.

The purpose of this study is to review the long-term outcomes for patients who underwent SVASD repair at Children Cardiac Center in Bratislava, Slovakia, to identify possible differences among particular surgical techniques in terms of outcomes, and to propose optimal treatment strategy for these patients.

Methods

In the period from 1992 to 2005, 85 patients were operated on for SVASD without severe coexisting anomalies at Children Cardiac Center, Bratislava, Slovakia. There were 49 males and 36 females. The mean age was 7.7 years (range, 2 months – 19 years). 78 patients (91.8 %) had a superior type of SVASD, 5 patients (5.9 %) had an inferior type of SVASD and 2 patients (2.3 %) had a very rare posterior type of SVASD. PAPVD was noted in 84 patients (98.8 %). It entered the RA in 23 patients

¹Department of Cardiothoracic Surgery, Leids Universitair Medisch Center, Leiden, the Netherlands, ²Children Cardiac Center, Bratislava, Slovakia, and ³Department of Pediatric Surgery, Children University Hospital, Bratislava, Slovakia

Address for correspondence: V. Sojak, MD, Dept of Cardiothoracic Surgery, Leids Universitair Medisch Center, Albinusdreef 2, 2333 ZA Leiden, the Netherlands.
Phone: +31629399773

Acknowledgement: The authors would like to thank all regional pediatric cardiologists in Slovakia who assisted us with the follow-up data.

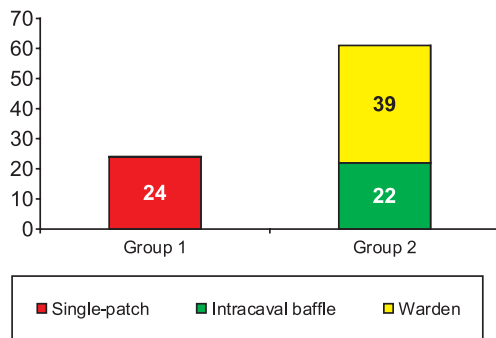


Fig. 1. Operative techniques.

(27.0 %), lower SVC (≤ 2 cm above cavoatrial junction) in 21 patients (24.7 %), and higher SVC in 40 patients (47.1 %). All operations were performed through median sternotomy using cardiopulmonary bypass at moderate systemic hypothermia (28–32 °C). The full sternotomy approach was employed in 78 patients, while the partial lower sternotomy approach was used in 7 patients with SVASD and PAPVD entering the RA or lower SVC. Several surgical techniques were used in this cohort depending on the anatomy of SVASD and PAPVD and the surgeon’s preference (Fig. 1). All patients with SVASD and PAPVD entering the RA and a single patient with SVASD and no PAPVD underwent a single-patch repair of SVASD with inclusion of PAPVD (Group 1). In the remaining cohort (Group 2), 22 patients underwent an intracaval baffle repair (Fig. 2A, B) mostly

with incision across the cavoatrial junction and 39 patients underwent Warden procedure (Fig. 3A, B). SVC was augmented in 8 patients in the intracaval baffle group.

The mean time from surgery to the last follow-up is 10.1 years (range, 3.4–15.1) and 9.3 years (range, 3.3–15.4) in Groups 1 and 2, respectively. In Group 2, the mean time from surgery to the last follow-up is 10.7 years (range, 3.3–15.4) and 8.2 years (4.7–10.6) in the intracaval baffle and Warden subgroup, respectively. Clinical, electrocardiographic and echocardiographic follow-ups were available for all patients. Serial postoperative electrocardiograms were analyzed and compared with preoperative findings by a single cardiologist. Echocardiographic endpoints included the presence of residual septal defect, and systemic or pulmonary venous obstruction. Clinical, electrocardiographic and echocardiographic endpoints were compared first between Groups 1 and 2 and then between the intracaval baffle and Warden subgroups. The data were analyzed using JMP statistical software (SAS Institute, Cary, USA). Based on this analysis an optimal treatment strategy was proposed.

Results

There were no early or late deaths. All patients are in NYHA Class I. No patient required reoperation. There were no residual atrial septal defects. No patient had obstruction of the pulmonary venous return. Two patients (one after Warden procedure one after intracaval baffle repair) with PAPVD entering the SVC had developed late SVC stenosis (pressure gradient >5 mmHg), and one of them underwent successful balloon dilatation with no

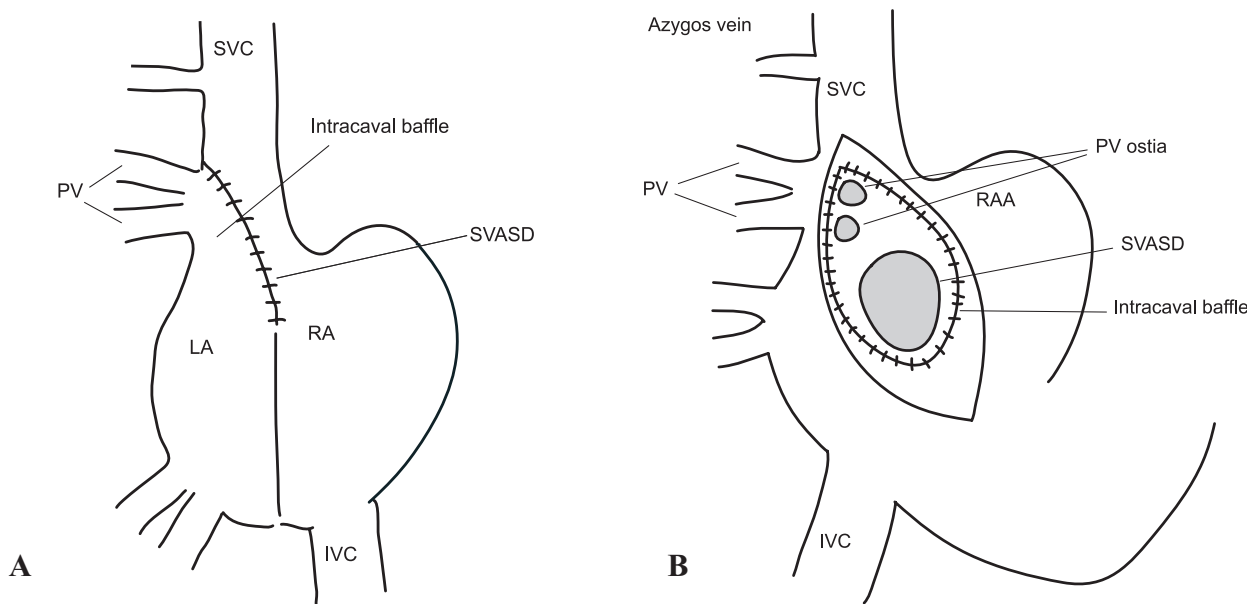


Fig. 2. A) Diagram of intracaval baffle technique in SVASD with PAPVD in the SVC, B) Drawing of intracaval baffle technique in SVASD with PAPVD in the SVC. IVC – inferior vena cava, LA – left atrium; PV – anomalous pulmonary veins; RA – right atrium; SVASD – sinus venosus atrial septal defect; SVC – superior vena cava

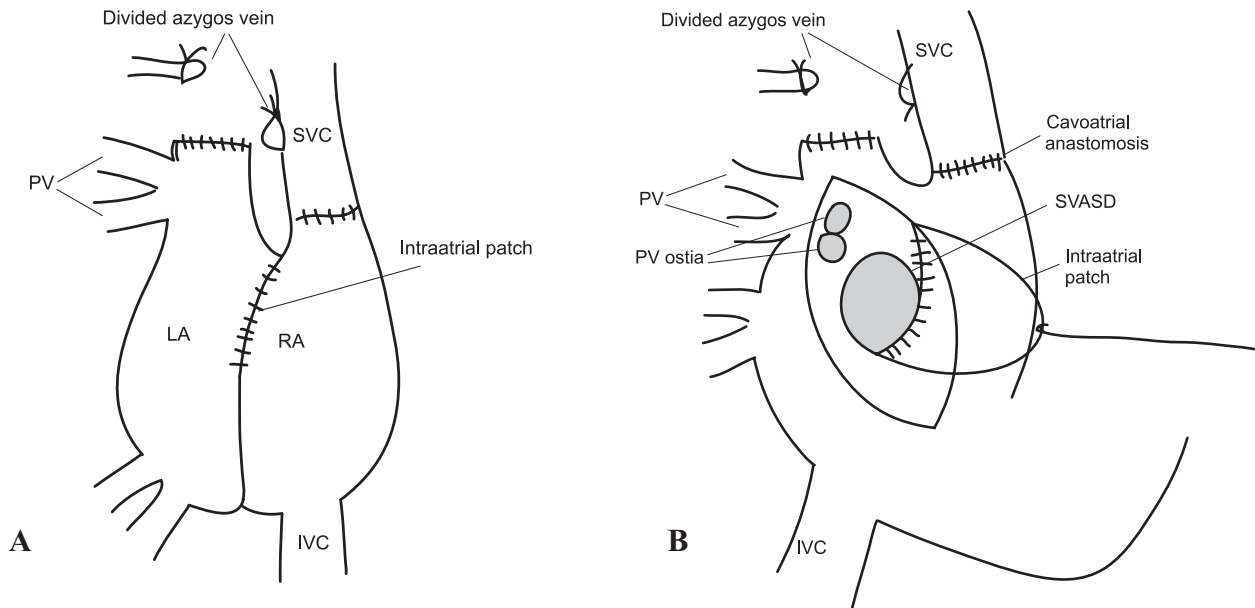


Fig. 3. A) Diagram of Warden repair in SVASD with PAPVD in the SVC, B) Drawing of Warden repair in SVASD with PAPVD in the SVC. IVC – inferior vena cava, LA – left atrium; PV – anomalous pulmonary veins; RA – right atrium; SVASD – sinus venosus atrial septal defect; SVC – superior vena cava.

residual SVC stenosis. New permanent cardiac arrhythmias were noted in 24 patients (28.2 %); in 3 patients (12.5 %) from Group 1 and in 21 patients (34.4 %) from Group 2. The following types of arrhythmias were noted: junctional rhythm (15 patients), sinoatrial node dysfunction (6 patients), atrial ectopic tachycardia (2 patients), and sinus bradycardia (1 patient). The last three types of arrhythmias were noted in Group 2 only. Two patients with atrial ectopic tachycardia are being treated with antiarrhythmics. One patient with sinus bradycardia had a pacemaker implanted. A statistically significant difference in the rate of new permanent arrhythmias was noted between Groups 1 and 2 ($p=0.04$; Pearson test).

In Group 2, new permanent arrhythmia was noted in 12 (54.6 %) and 9 (23.1 %) patients from the intracaval baffle and

Warden subgroup, respectively. Junctional rhythm was found in 5 and 7 patients from the intracaval baffle and Warden subgroup, respectively. Sinoatrial node dysfunction was noted in 4 and 2 patients from the intracaval baffle and Warden subgroup, respectively. Atrial ectopic tachycardia and sinus bradycardia occurred in the intracaval baffle group only. A statistically highly significant difference in the rate of new permanent arrhythmias was noted between the intracaval baffle and Warden subgroups ($p=0.01$; Fisher exact test). A trend toward higher freedom from sinoatrial node disturbances during the follow-up was noted in the Warden subgroup ($p=0.068$; Wilcoxon test) (Fig. 4). Table 1 compares study endpoints in the intracaval baffle and Warden subgroups.

Discussion

Surgical principles of ASDSV repair involve closure of atrial septal defect and redirection of PAPVD into LA. Operative techniques vary with the anatomy of SVASD and especially PAPVD. The repair of inferior, posterior and superior SVASD types with PAPVD entering RA is usually uneventful and associated with minimal morbidity and virtually no mortality in pediatric patients (5, 6). However, surgical correction of SVASD with PAPVD in the SVC is more complex and carries a higher risk of complications (7–10). Various surgical techniques have been suggested: PAPVD redirection through atrial septal defect into the left atrium using an intracaval baffle with or without augmentation of the SVC (intracaval baffle technique; 2, 10, 13, 14); SVC division above the site of PAPVD, SVC connection to the right atrial appendage and patch baffling of the SVC orifice hence PAPVD

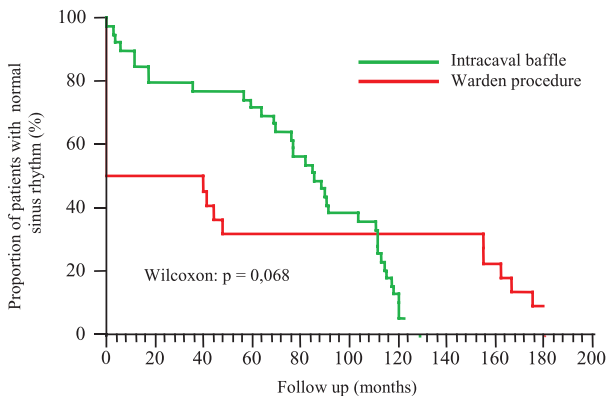


Fig. 4. Freedom from sinoatrial node disturbance during follow-up.

Tab. 1. Patient characteristics in intracaval baffle and Warden procedure subgroups.

	Intracaval baffle technique	Warden procedure
N	22	39
Mean age (range) (years)	8.0 (1.8–17.5)	8.1 (0.6–19.4)
Follow-up (range), years	11.3 (3.3–15.4)	8.2 (4.8–10.8)
Mortality	0	0
Reoperation	0	0
Residual atrial septal defect (n)	0	0
Obstruction of systemic venous return (n)	1	1
Obstruction of pulmonary venous return (n)	0	0
New arrhythmias (n (%))	12 (54.6)*	9 (23.1)*
Junctional rhythm (n)	5	7
Sinoatrial node dysfunction (n)	4	2
Atrial ectopic tachycardia (n)	2	0
Sinus bradycardia (n)	1	0
Antiarrhythmics (n)	2	0
Pacemaker (n)	1	0

* Statistically significant difference (p=0.01; Fisher exact test)

into the left atrium (Warden procedure; 11, 12, 18); limited lateral transcaval approach with single-patch closure of SVASD and baffling of PAPVD into the left atrium (transcaval techniques; 15–17). Recently, less invasive techniques have been introduced in surgical treatment of these lesions thus achieving superior cosmetic results (19, 20).

The intracaval baffle technique was formerly associated with significant morbidity, including obstruction of the pulmonary veins, SVC stenosis or obstruction, and postoperative arrhythmias (2, 7, 10). Some technical modifications resulted in more favorable outcomes after this technique (10, 13, 14).

The Warden procedure has been proposed particularly to prevent postoperative arrhythmias. This technique is designed so that no incision crosses the cavoatrial junction, i.e. sinoatrial node and its arterial supply. Potential complications of this procedure include SVC obstruction (6, 22) and pulmonary venous obstruction (5, 21). However, most recent reports suggest minimal or no complications with this technique (23).

Transcaval techniques have been reported to achieve excellent results with no complications.

At our institution, the choice of operative technique varies with the anatomy of SVASD and especially PAPVD. In patients with inferior, posterior and superior types of SVASD and no PAPVD or PAPVD into the RA, the surgical repair involves closure of SVASD with a pericardial patch that allows anomalous pulmonary veins to drain into the left atrium. In patients with the superior type of SVASD and PAPVD into SVC, an intracaval baffle technique with or without SVC enlargement had been used in all patients until 1997. Because of higher incidence of postoperative arrhythmias, the Warden procedure has been used preferentially in these patients since 1997. In selected patients with SVASD and PAPVD into the RA or cavoatrial junction, we have used less invasive surgical approach (single-patch or intracaval baffle technique through partial lower sternotomy) since 2004.

Our series belongs to the largest ever published by pediatric institutions. The mean follow-up belongs to the longest ever reported. We had no mortality, no reoperations, no residual atrial septal defects, and no pulmonary venous obstruction which compares favorably with other reports (5, 21). We had two cases of SVC obstruction which is consistent with other authors experience (6, 22). The frequency of newly developed arrhythmias in the entire cohort is similar to other reports (6, 22).

Data analysis suggests the following differences between Group 1 and 2: (a) obstruction of systemic venous drainage was noted only in Group 2; this is clearly related to the differences in anatomy of SVASD and PAPVD between both groups; (b) a significantly higher rate of new permanent postoperative arrhythmias was noted in Group 2; this is not surprising as the surgical repair of PAPVD into SVC involves more manipulation with the RA and the cavoatrial junction, hence, higher risk of injury to the sinoatrial node itself or its arterial supply; (c) no patient receives anti-arrhythmic or pacing therapy in Group 1, while 2 patients receive anti-arrhythmics and 1 patient has a pacemaker implanted in Group 2. As a result, surgical repair of SVASD and PAPVD into the SVC carries a higher risk of postoperative complications.

Data review implies the following differences between the intracaval baffle and Warden subgroups: (a) a significantly higher rate of new permanent postoperative arrhythmias and a lower freedom from sinoatrial node disturbances during follow-up was noted in the intracaval baffle subgroup (b) a higher incidence of sinoatrial node dysfunction was noted in the intracaval baffle subgroup; (c) atrial ectopic tachycardia and marked sinus bradycardia occurred in the intracaval baffle subgroup only; (d) no patient receives anti-arrhythmic or pacing therapy in the Warden subgroup, while 2 patients receive anti-arrhythmics and 1 patient has a pacemaker implanted in intracaval baffle subgroup.

In summary, the Warden procedure is associated with significantly lower rate of new postoperative arrhythmias compared

with the intracaval baffle technique. New arrhythmias after the Warden procedure tend to be milder (mostly junctional rhythm and less commonly sinoatrial node dysfunction). In contrast, the intracaval baffle technique carries a higher risk of sinoatrial node dysfunction and more severe arrhythmias requiring anti-arrhythmic and pacing therapy. These data warrant our change in the treatment strategy for patients with SVASD and PAPVD into SVC adopted in 1997.

Only few centers have offered less invasive approach to patients with SVASD and PAPVD. There were no differences in study endpoints between the subgroups operated on through complete and partial sternotomy. However the less invasive approach was associated with superb cosmetic results appreciated by the patients and their families.

In conclusion, the surgical repair of SVASD can be performed with excellent results, low morbidity and no mortality. In patients with SVASD and no PAPVD or PAPVD entering the RA or proximal SVC, the repair can be achieved with right atrial approach from full or partial lower sternotomy. For patients with SVASD and PAPVD entering the higher SVC, the Warden procedure is safe, effective and superior to the intracaval baffle technique mainly because of the lower incidence of postoperative arrhythmias.

References

1. **Jacobs JP, Quintessenza JA, Burke RP, Mavroudis C.** Congenital Heart Surgery Nomenclature and Database Project: Atrial septal defect. *Ann Thorac Surg* 2000; 69: S18—S24.
2. **Kirklin JW, Ellis FH, Wood EH.** Treatment of anomalous pulmonary venous connections in association with interatrial communications. *Surgery* 1956; 39: 389—298.
3. **Schuster SR, Gross RE, Colodny AH.** Surgical management of anomalous right pulmonary venous drainage to the superior vena cava, associated with superior marginal defect of the atrial septum. *Surgery* 1962; 51: 805—808.
4. **Kyger ER, III, Frazier H, Cooley D et al.** Sinus venosus atrial septal defect: early and late results following closure in 109 patients, *Ann Thorac Surg* 1978; 25: 44—50.
5. **Shahriari A, Rodefeld MD, Turrentine MW, Brown JW.** Caval division technique for sinus venosus atrial septal defect with partial anomalous pulmonary venous connection, *Ann Thorac Surg* 2006; 81: 224—230.
6. **Alsoufi B, Cai S, Van Arsdell GS, Williams WG et al.** Outcomes after surgical treatment of children with partial anomalous pulmonary venous connection. *Ann Thor Surg* 2007; 84: 2020—2026.
7. **Frieli B, Guerin R, Davignon A et al.** Surgical treatment of partial anomalous pulmonary venous drainage: A long-term follow-up study. *Circulation* 1973; 45: 159—170.
8. **Chartrand C, Payot M, Davignon A et al.** A new surgical approach for correction of partial anomalous pulmonary venous drainage into the superior vena cava. *J Thorac Cardiovasc Surg* 1976; 71: 29—39.
9. **Lewin AN, Zavanella C, Subramanian S.** Sinus venosus atrial septal defect associated with partial anomalous pulmonary venous drainage: surgical repair. *Ann Thorac Surg* 1978; 26: 185—188.
10. **Trusler GA, Kazenelson G, Freedom RM et al.** Late results following repair of partial anomalous pulmonary venous connection with sinus venosus atrial septal defect. *J Thorac Cardiovasc Surg* 1980; 79: 776—781.
11. **Williams WH, Szon-Chelton, Raviele AR et al.** Extracardiac atrial pedicle conduit repair of partial anomalous pulmonary venous connection to the superior vena cava in children. *Ann Thor Surg* 1984; 38: 345—354.
12. **Warden HE, Gustafson RA, Tarnay TJ, Neal WA.** An alternative method for repair of partial anomalous pulmonary venous connection to the superior vena cava. *Ann Thorac Surg* 1984; 38: 601—605.
13. **Stewart S, Alexson C, Manning J.** Early and late results of repair of partial anomalous pulmonary venous connection to the superior vena cava with a pericardial baffle. *Ann Thorac Surg* 1986; 41: 498—501.
14. **DeLeon SY, Freeman JE, Ibbawi ME et al.** Surgical techniques in partial anomalous pulmonary veins to the superior vena cava, *Ann Thorac Surg* 1993; 55: 1222—1226.
15. **Victor S, Nayak VM.** Transcaval repair of sinus venosus defect, *Tex Heart Inst J* 1995; 22: 304—307.
16. **Nicholson IA, Chard RB, Nunn GR, Cartmill TR.** Transcaval repair of the sinus venosus syndrome. *J Thorac Cardiovasc Surg* 2000; 119: 741—744.
17. **Baskett RJE, Ross DB.** Superior vena cava approach to repair of sinus venosus atrial septal defect. *J Thorac Cardiovasc Surg* 2000; 119: 178—80.
18. **Gustafson RA, Warden HE, Murray GF.** Partial anomalous pulmonary venous connection to the superior vena cava. *Ann Thorac Surg* 1995; 60: 5614—5617.
19. **Bichell DP, Mayer JE, Geva T, del Nido PJ.** Minimal access approach for the repair of atrial septal defect: experience with the initial 96 patients. *Circulation*; in press (1999).
20. **Byrne JG, Adams DH, Mitchell ME, Cohn LH.** Minimally invasive direct access for repair of atrial septal defect in adults. *Amer J Cardiol* 1999; 84: 919—922.
21. **Gaynor JW, Burch M, Dollery C, Sullivan ID, Deanfield JE, Elliott MJ.** Repair of anomalous pulmonary venous connection to the superior vena cava. *Ann Thorac Surg* 1995; 59: 1471—1475.
22. **Stewart RD, Bailliard F, Kelle AM, Backer C et al.** Evolving strategy for sinus venosus atrial septal defect: effect on sinus function and late venous obstruction. *Ann Thor Surg* 2007; 84: 1651—1655.
23. **Baron O, Roussel JC, Videcoq M, Guérin P et al.** Partial anomalous pulmonary venous connection: correction by intra-atrial baffle and cavo-atrial anastomosis. *J Card Surg* 2002; 17: 166—169.

Received February 19, 2008.

Accepted March 28, 2008.