

## CASE REPORT

# Clinical changes in “true” hobnail hemangioma during menstruation

Fernandez-Flores A<sup>1,3</sup>, A Manjon J<sup>2</sup>, Campo F<sup>1</sup>

*Anatomic Pathology, Hospital El Bierzo, Clinica Ponferrada, Ponferrada, Spain. gpyauflowerlion@terra.es*

**Abstract:** Hobnail hemangioma (HH) was known in the past as targetoid hemosiderotic hemangioma (THH). We present a case that meets the criteria of HH in a 34-year-old woman. The lesion presented as a reddish papule on her left hip. It changed periodically during menstruation and the changes included. The biopsy showed the characteristics of a typical HH with moderate iron deposits. Immunohistochemical staining failed to demonstrate either estrogen or progesterone receptors (*Fig. 1, Ref. 15*). Full Text (Free, PDF) [www.bmj.sk](http://www.bmj.sk).

Key words: hobnail hemangioma, targetoid hemosiderotic hemangioma, estrogen receptor, progesterone receptor.

## Case report

A 47-year-old woman came to the consultancy of Dermatology complaining of a skin lesion on the left hip that had appeared one year ago. It measured 2 mm in diameter when she first noticed it and grew slowly. During menstruation periods, the patient noticed that the lesion became swollen with clearer borders. After ovulation, she also noticed that the lesion flattened and slowly grew at the periphery.

Examination revealed a non-well delimited reddish papule of 7x4 mm.

The lesion was removed and the histopathologic examination showed a poorly circumscribed dermal vascular lesion (*Fig. 1, top left*), with some ectatic vascular spaces lined by a single layer of hobnail cells with occasional intraluminal projections (*Fig. 1, top right*). Some of the vascular structures presented an angulated shape (*Fig. 1, bottom, left*), especially in the periphery of the lesion. Moreover, some areas of convincing promontory sign were evidenced. Perls histochemical staining revealed moderate dermal deposits of iron. No fibrin thrombi were evidenced. Moderate perivascular lymphocytic infiltrate was seen with no plasma cells. The latter fact was also corroborated by an immunohistochemical stain against epithelial membrane antigen (Dakocytomation, Monoclonal mouse anti-human (MMAH), epithelial membrane antigen, clone E29, code N1504).

The lesion was diagnosed as hobnail hemangioma.

We performed an immunohistochemical study with additional following antibodies: Vimentine (Dakocytomation, monoclonal mouse anti-swine, clone V9, code N1521), CD34 (Dakocytomation, MMAH, CD34 class II, clone QBEnd-10, code Nr M 7165), CD31 (Dakocytomation, MMAH, endothelial cell, clone JC70A, code N1596), Factor VIII (polyclonal rabbit anti-human von Willebrand factor, code N1505), estrogen-receptors (ER) (Dakocytomation, MMAH, clone 1D5, code N1575), and progesterone-receptors (PR) (Dakocytomation, clone PgR636, code N1630).

CD34, CD31, factor VIII and vimentine outstood the vascular lesion (*Fig. 1, bottom right*). The latter did not show any expression of either ER or PR.

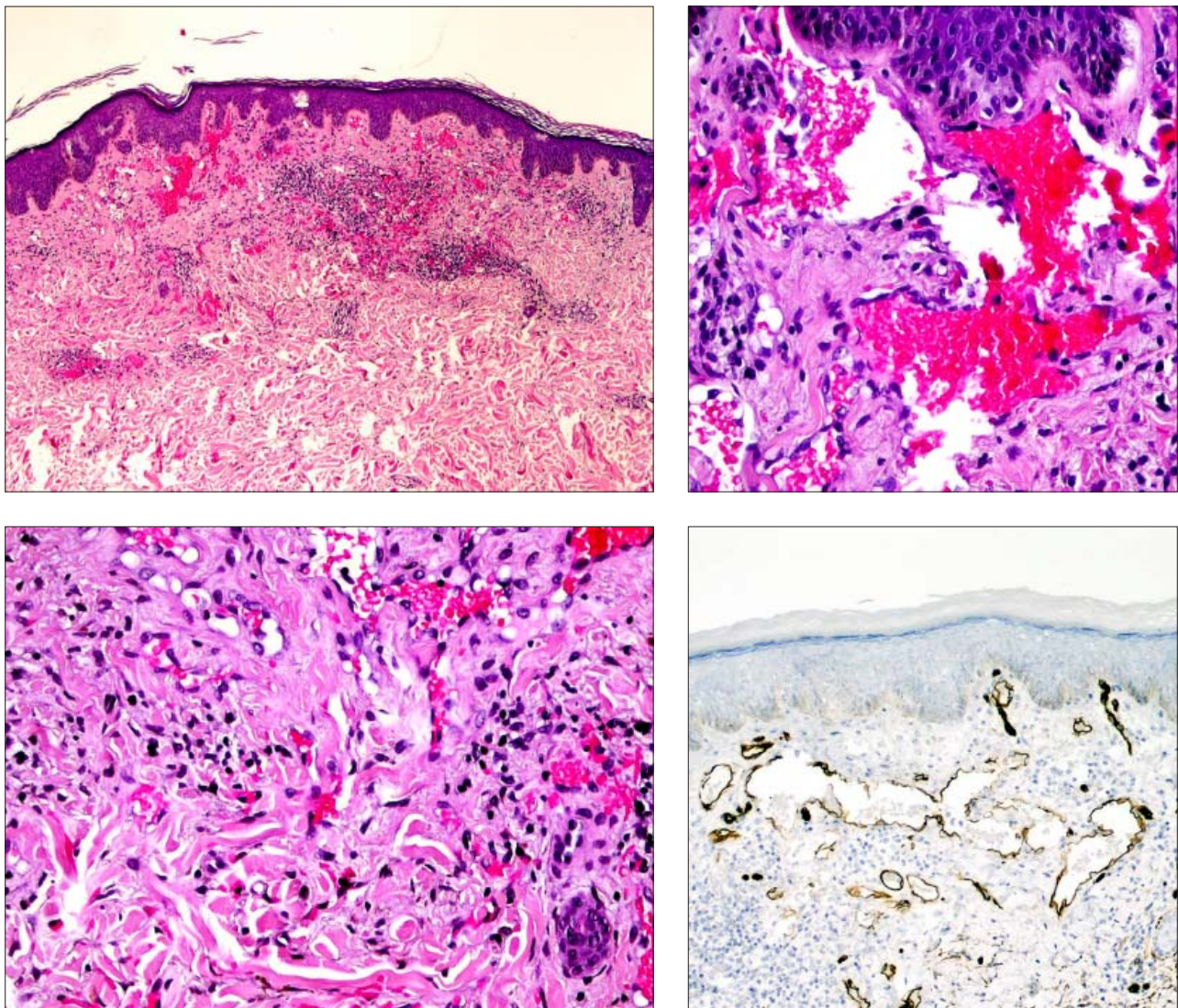
## Discussion

Hobnail hemangioma (HH) (1) was the term proposed to refer to the clinical entity known as targetoid hemosiderotic hemangioma (THH) (2). The renaming was proposed under the observation that many of these lesions do not present a clinical targetoid appearance. Moreover, hemosiderin is not always conspicuous in them.

In recent literature, HH has been alleged to be a type of lymphangioma, mainly due to its immunophenotype, i.e., the immunoeexpression of D2-40, its lack of expression of CD34, and the lack of actin-labeled pericytes (3). Nevertheless, larger series of cases have demonstrated that some cases actually express CD34 (1, 4) and present actin-positive pericytes surrounding the endothelial cells (4). Moreover, CD34 has been demonstrated in many other lesions of lymphatic nature (5). On top of that, D2-40 positivity in some angiomatous entities has alternatively been interpreted by some as a possible origin from stem cells that would be able to differentiate either into lymphatic cells or blood vessel cells (6). Some single-case reports of THH fol-

<sup>1</sup>Anatomic Pathology and <sup>2</sup>Dermatology, Hospital El Bierzo, and the <sup>3</sup>Service of Cellular Pathology, Clinica Ponferrada, Ponferrada, Spain

**Address for correspondence:** Angel Fernandez-Flores, MD, PhD, S. Patología Celular, Clinica Ponferrada, Avenida Galicia 1, 24400 Ponferrada, Spain.  
Phone: +34.987.423732, Fax: +34.987.429102



**Fig. 1.** Top left: Panoramic view of the lesion. In it, the vascular proliferation with dilated vessels as well as dissecting angulary vessels in the periphery can be seen (hematoxylin-eosin). Top right: pseudopapillary projections, with hobnail endothelium (hematoxylin-eosin). Bottom left: Detail of the periphery of the lesion, in which the angulated vessels can be seen (hematoxylin-eosin). Bottom right: Immunostaining for CD34 antibody showing intense expression by the endothelium.

lowing trauma have been presented (7), and some have proposed that THH could develop from other vascular malformations, mainly after repeated trauma (8). As others, we have demonstrated the evidence of CD34 in our lesion and wonder if THH could be a pattern shared by tumors of either lymphatic or blood vessel origin.

Our case showed clinical fluctuations depending on the hormonal status of the patient. This is not the first time a cutaneous vascular lesion has been reported to have clinical variations under hormonal influence.

Clinical changes with menstruation have been seen in cutaneous conditions that are not necessarily made of endometrium (9). These changes have been attributed by some, to the general retention of liquids, that is evidenced during menstruation (9).

It is well known how pyogenic granuloma can appear in pregnancy (10), and hormonal receptors have been demonstrated in some cases with immunohistochemistry (11). It has been hypothesized that hormones enhance the expression of angiogenic factors in inflamed tissue (12). On the other hand, some other vascular conditions, of lymphatic nature, have also been alleged to be hormonally influenced (13).

In 1990, a case of THH on a buttock of a pregnant woman was reported (14), although the authors attributed the lesion to trauma.

In 1995, a cutaneous targetoid vascular lesion, which showed changes related to the menstrual cycle, was reported (15). The authors demonstrated an absence of immunohistochemical expression of estrogen and progesterone receptors in the lesion.

Even so, the authors interpreted this absence cautiously, alleging the possibility of enzymatic digestion as a cause of this negativity. Their hypothesis was that the clinical changes that were seen with the cycle were mainly due to the vasoactive effect of estrogens. More importantly, the authors were convinced that the lesion they described was not THH, but another type of targetoid hemangioma. They claimed that targetoid hemangioma would be a broader entity, which would include precocious stages previous to hemosiderin deposition. We wonder if re-evaluation of their lesion with modern criteria, would bring them to admit the diagnosis of HH for it. Sadly they did not provide any hematoxylin-eosin picture of the lesion, however they emphasized the main differential characteristics that are typical of THH, and which were not mainly present in their case: such as: a) poorly circumscribed proliferation of ectatic dermal vascular spaces lined by a single layer of flat or epithelioid cells often exhibiting intraluminal papillary projections; b) presence of hemosiderin deposition; c) fibrin thrombi; d) a scant lymphocytic infiltrate; and d) angulation of deeper vessels forming slit like vascular spaces between collagen bundles. In our case, apart from fibrin thrombi, all the other characteristics were present, so we interpreted it as a typical example of HH.

Later on in 1999, Carlson et al reported a series of three cases of THH (8). Their case number 3 appeared in a 40-year-old woman, and cyclic changes in her lesion were evidenced every other menses. The changes stopped during pregnancy, but recurred after partum. The authors provided hematoxylin-eosin pictures of the case, in which a typical THH was shown. They also performed an immunohistochemical study for estrogen and progesterone receptors, which was negative in both cases.

We currently provide a case of a vascular lesion that: 1) meets histologic criteria of hobnail hemangioma (previously known as THH); 2) presented clinical variations with the menstrual cycle; and 3) expresses neither estrogen nor progesterone receptors.

## References

1. **Guillou L, Calonje E, Speight P, Rosai J, Fletcher CD.** Hobnail hemangioma: a pseudomalignant vascular lesion with a reappraisal of targetoid hemosiderotic hemangioma. *Amer J Surg Pathol* 1999; 23 (1): 97—105.
2. **Santa Cruz DJ, Aronberg J.** Targetoid hemosiderotic hemangioma. *J Amer Acad Dermatol* 1988; 19 (3): 550—558.
3. **Franke FE, Steger K, Marks A, Kutzner H, Mentzel T.** Hobnail hemangiomas (targetoid hemosiderotic hemangiomas) are true lymphangiomas. *J Cutan Pathol* 2004; 31 (5): 362—367.
4. **Mentzel T, Partanen TA, Kutzner H.** Hobnail hemangioma („targetoid hemosiderotic hemangioma“): clinicopathologic and immunohistochemical analysis of 62 cases. *J Cutan Pathol* 1999; 26 (6): 279—286.
5. **Sauter B, Foedinger D, Sterniczky B, Wolff K, Rappersberg K.** Immunoelectron microscopic characterization of human dermal lymphatic microvascular endothelial cells: differential expression of CD31, CD34, and type IV collagen with lymphatic endothelial cells vs blood capillary endothelial cells in normal human skin, lymphangiomas, and hemangioma in situ. *J Histochem Cytochem* 1998; 46 (2): 165—176.
6. **Arai E, Kuramochi A, Tsuchida T, Tsuneyoshi M, Kage M, Fukunaga M, Ito T, Tada T, Izumi M, Shimizu K, Hirose T, Shimizu M.** Usefulness of D2-40 immunohistochemistry for differentiation between kaposiform hemangioendothelioma and tufted angioma. *J Cutan Pathol* 2006; 33 (7): 492—497.
7. **Christenson LJ, Stone MS.** Trauma-induced simulator of targetoid hemosiderotic hemangioma. *Amer J Dermatopathol* 2001; 23 (3): 221—223.
8. **Carlson JA, Daulat S, Goodheart HP.** Targetoid hemosiderotic hemangioma — a dynamic vascular tumor: report of 3 cases with episodic and cyclic changes and comparison with solitary angiokeratomas. *J Amer Acad Dermatol* 1999; 41 (2 Pt 1): 215—224.
9. **Gabrielsen TO, Elgio K, Sommerschild H.** Eccrine angiomatous hamartoma of the finger leading to amputation. *Clin Exp Dermatol* 1991; 16 (1): 44—45.
10. **Demir Y, Demir S, Akpete F.** Cutaneous lobular capillary hemangioma induced by pregnancy. *J Cutan Pathol* 2004; 31 (1): 77—80.
11. **Whitaker SB, Bouquot JE, Alimario AE, Whitaker TJ Jr.** Identification and semiquantification of estrogen and progesterone receptors in pyogenic granulomas of pregnancy. *Oral Surg Med Oral Pathol* 1994; 78 (6): 755—760.
12. **Yuan K, Wing LY, Lin MT.** Pathogenetic roles of angiogenic factors in pyogenic granulomas in pregnancy are modulated by female sex hormones. *J Periodontol* 2002; 73 (7): 701—708.
13. **Tazelaar HD, Kerr D, Yousem SA, Saldana MJ, Langston C, Colby TV.** Diffuse pulmonary lymphangiomatosis. *Hum Pathol* 1993; 24 (12): 1313—1322.
14. **Rapini RP, Golitz LE.** Targetoid hemosiderotic hemangioma. *J Cutan Pathol* 1990; 17 (4): 233—235.
15. **Morganroth GS, Tigelaar RE, Longley BJ, Luck LE, Leffell DJ.** Targetoid hemangioma associated with pregnancy and the menstrual cycle. *J Amer Acad Dermatol* 1995; 32 (2 Pt 1): 282—284.

Received January 16, 2008.

Accepted February 4, 2008.