

CLINICAL STUDY

Diagnosis and treatment of liver injury – the experience of the University Trauma Center

Treska V, Skalicky T, Houdek K, Smid D

Trauma Center, University Hospital in Pilsen, Czech Republic. treska@fnplzen.cz

Abstract: *Background:* The incidence of liver injury is increasing steadily because of serious injuries resulting mainly from traffic accidents. The aim of the study was to evaluate the results of the University Trauma Center, with consideration of the present diagnostic and therapeutic possibilities for liver injuries.

Methods: Between January 1st 2000 and April 1st 2006 a total of 132 patients with various degrees of liver injury were admitted to the Trauma Center, University Hospital in Pilsen. 76 injured patients (57.6 %) were treated conservatively, and only 56 (42.4 %) received surgical treatment, with a total of 87 operations performed.

Results: 10 patients with polytrauma (7.6 %) died of hemorrhagic shock (group Moore IV–VI). Six injured patients (4.5 %) had a complicated course during their hospitalization. The average period of hospitalization was 17 days (1–69 days).

Conclusion: The mortality and morbidity of patients with liver injury are comparable in the group presented here with the results of other large trauma centers. If compared with previous years, there has been a considerable decrease in mortality from this serious injury. At present the basic diagnostic means in liver injury are as follows: “bed-side” ultrasonography, spiral computed tomography, and in more complicated injuries magnetic resonance, angiography, or endoscopic retrograde cholangiography. In terms of therapeutic tactics conservative methods prevail in haemodynamically stable patients, irrespective of the degree of liver injury. The surgical policy applies “damage control surgery”, where during the initial surgery life-saving and non-time-demanding procedures are the target (e.g. liver tamponade), correcting hypothermia, haemocoagulation and metabolic acidosis. Only after stabilization of the injured patient other definitive procedures are possible (Tab. 2, Ref. 16). Full Text (Free, PDF) www.bmj.sk.

Key words: liver injury, diagnostics, treatment.

The liver is the organ most commonly injured in traumas of abdominal cavity. The incidence of injuries is increasing every year as a result of high number of traffic accidents in the Czech Republic. However, sport and criminal accidents also constitute a substantial percentage of these injuries. Liver injury is normally part of a polytrauma or of combined injuries. While 30 years ago the mortality of this injury was almost 70 %, at present it is relatively low and fluctuates on average at about 10 %, depending upon the type of injury (1). This significant reduction in mortality is mainly due to a multidisciplinary care for the injured, owing to a well-organized pre-hospital care, the traumatological center system, important progress in diagnosis, and essential changes in therapeutic strategy when dealing with patients suffering from liver injury.

Trauma Center, University Hospital in Pilsen, Czech Republic.

Address for correspondence: V. Treska, MD, PhD, Dept of Surgery, Trauma Center, University Hospital in Pilsen, Alej Svobody 80, CZ-304 60 Plzen, Czech Republic.
Phone:

Acknowledgement: The research was supported by IGA MZ NR 8301-3/2005 and VZ MSM 0021620819.

Patients and methods

Between January 1st 2000 and December 31st 2006, a total of 145 patients (104 men and 41 women) with varied serious liver injuries were admitted at the Surgical Clinic of the Faculty Hospital and the Charles University Medical Faculty in Pilsen,

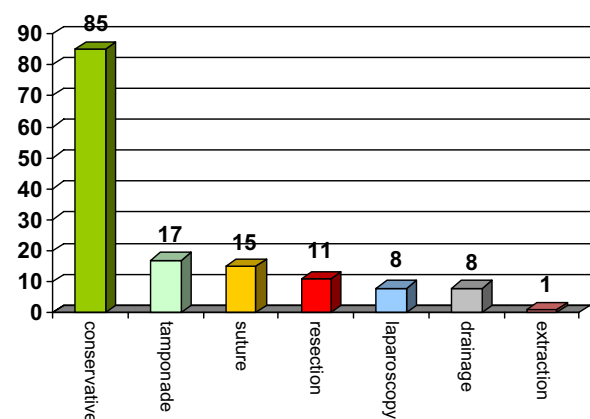


Fig. 1. Treatment of liver injuries (n=145).

Tab. 1. Characteristic of the group (January 1st 2000–December 31st 2006).

Number of injured patients		145	
Average age		33.4 years (2–78 years)	
Men	104	Women	41
Injury in adults		126	
Injury in children		19	
Injury	traffic	n = 96	
	criminal	n = 20	
	sport	n = 17	
	industrial	n = 12	
Injury	blunt	n = 128	
	penetrating	n = 17	
Polytrauma	58		
Combined injuries	42		
Monotrauma	45		
Mortality	10 (6.9%)		
Morbidity	6 (4.1%)		

which is a part of the Traumatological Center. The average age of the patients was 33.4 years (2–78 years). Injuries of adults prevailed (n=126), and there were 19 cases of liver injury in children (<15 years). The commonest causes of the injuries were traffic injuries (n=96), criminal injuries (n=20), sport injuries (n=17) and industrial injuries (n=12). In 58 patients the liver injury represented a part of polytrauma, in 42 patients it was a part of a combined injury, and 45 patients had a monotraumatic liver injury (Tab. 1). In order to assess the severity of liver injury, we used Moore's classification of liver injuries (1). In 57 patients it was of degree I, in 28 patients of degree II, in 43 patients of degree III, in 8 patients of degree IV, in 5 patients of degree V, and in 4 patients of degree VI (Tab. 2).

Clinical examination of injured persons served as the basis for diagnosis, with subsequent ultrasonography, supplemented in a number of cases with spiral computed tomography (CT). In more complicated injuries we even used computed tomographic arteriography (CTAG) or magnetic resonance imaging (MRI).

A total of 85 patients (58.6 %) were treated with a conservative procedure and 60 patients (41.4 %) by surgical means. We used open laparotomy in 52 liver injuries (17x tamponade, 15x suture, 11x resection, 8x drainage, and one projectile extraction). Laparoscopy was used for both diagnosis and therapy (haemoperitoneum suction, drainage) in 8 patients with stable circulation but with a deteriorating clinical abdominal finding (Fig. 1). We performed a total of 91 procedures on 60 injured patients. The average number of surgical procedures per patient was 1.5.

Results

10 patients (6.9 %) with polytrauma died of hemorrhagic shock (Group Moore IV–VI). Six injured patients (4.1 %) had a

complicated course during hospitalization (stroke, ischemic colitis, acute pancreatitis, methicillin resistant staphylococcal infection, pneumonia, ileus, bleeding, biloma, subphrenic abscess, laparotomy dehiscence). The average period of hospitalization was 17 days (1–69 days).

Discussion

In the past 30 years there has been a significant shift in the diagnosis and treatment of liver injury. Approximately 15 years ago one of the basic diagnostic procedures in injuries of parenchymatose organs of the abdominal cavity was the peritoneal lavage or surgical exploration of the abdominal cavity. Recently there has been a significant move towards sophisticated diagnostic methods with high precision, such as sonography, CT, CTA and MRI that, together with clinical examination, are nowadays the basic methods in the diagnostic algorithm (2, 3). The sensitivity of sonography in the hands of an experienced sonography specialist is >95 % in liver traumas. Spiral computed sonography is important from the point of view of the anatomical description of injury and therapeutic procedure, and it has an irreplaceable position in monitoring the patients for the development of liver injury. In some indications (for example, in haemobilia) CTAG may be used, or MRI, which is also suitable in suspected injury of the biliary tree. In these injuries even endoscopic retrograde cholangiopancreatography (ERCP) has its diagnostic position, since it can be used for inserting stents into the site of biliary duct injury. Digital subtraction angiography (DSA) is used more in therapeutic possibilities, particularly where arterial intra-parenchymatous bleeding occurs. In such cases DSA is suitable for embolization of the bleeding artery. Diagnostic laparoscopy plays an important role in haemodynamically stable

Tab. 2. Moore's classification of liver injury.

Degree	Finding	Description	n
I	Haematoma, laceration	Subcapsular, non-prograding <10 % of the surface, non-bleeding, <1 cm penetration into parenchyma	57
II	Haematoma, laceration	Subcapsular, non-prograding <15 % of the surface, bleeding penetration 1–3 cm with <10 cm length	28
III	Haematoma, laceration	Subcapsular >50 % of the surface, intraparenchymatous haematoma >2 cm, >3 cm penetration	43
IV	Haematoma, laceration	Rupture, intraparenchymatous haematoma, bleeding, effected >50 % parenchyma	8
V	Capillary laceration	Injured >50% liver parenchyma Injury of hepatic veins	5
VI	Capillary laceration	Severe dilaceration of main veins	4

patients with a deteriorating abdominal finding, where the above-mentioned examinations do not lead to any diagnostic decision. Such conditions are found, for example, in simultaneous intestinal injury, which may be diagnostically silent in the early hours after the accident.

Particularly as a result of these diagnostic possibilities, and also because of a significant development in intensive care, the therapeutic tactics in liver injury have undergone essential changes (4). Generally, the conservative therapy prevails at present, and 50–95 % of injured patients can be treated by this means. We choose this treatment in haemodynamically stable patients with no signs of peritoneal irritation, with no associated injury of other organs in the abdominal cavity that would require laparotomy, with no permanent reduction in the red blood count that would need more than two blood transfusions, and where haemoperitoneum does not exceed 500ml. We choose conservative therapy where full monitoring of vital functions and 24-hour access to diagnostic means is guaranteed. Until recently the decision about the choice of surgical or conservative treatment was also dictated by the degree of liver injury, where injuries I to III according to Moore could be treated with conservative methods. Nowadays, with the present possibilities, we can treat up to 60 % of patients with higher degrees of liver injury with conservative methods, provided that their circulation is stable. However, with these types of injuries we have to consider the possibility of subsequent surgery, particularly as a result of biliary peritonitis in injury to the biliary tree.

Laparotomy is indicated in haemodynamically non-stable patients with signs of massive or progressive bleeding into the abdominal cavity (Moore IV–VI) and/or with injuries to other organs in the abdominal cavity that require laparotomy (5, 6). In patients where laparotomy is indicated from vital indication as an urgent procedure we try not to treat fully all intra-abdominal injuries including liver injury, but to provide basic treatment of the life-threatening injuries (“damage control surgery”) and subsequently, after stabilization of the injured patient, to perform definitive procedures that can be spread over long periods of time after the injury. The aim of the so called “damage control surgery” (7) is to reduce significantly the mortality of patients by preventing hypothermia and the development of coagulopathy with metabolic acidosis. As for the type of liver procedure, we prefer to choose a more conservative procedure, ranging from liver parenchymal tamponade through the treatment of bleeding capillaries to the resection of liver parenchyma (8).

The liver tamponade is performed with folded abdominal pads. Their function is to prevent further bleeding and to stabilize a patient with a “second look” procedure within 24–48 hours. The liver tamponade is an effective means of stopping the liver from bleeding, but it is accompanied by danger from a number of complications, such as necrosis of the liver parenchyma, occurrence of abscesses, intra-abdominal compartment syndrome, and compression of the inferior vena cava (9).

In liver resections we prefer to choose non-anatomical resection since with the latter the mortality in liver accidents is considerably lower when compared with anatomical resections,

mainly as a result of the time factor in the surgery, which is shorter in non-anatomical resections. In massive bleeding from liver parenchyma it is advisable to use Pringl’s manoeuvre, where a tourniquet applied to the hepatoduodenal ligament in healthy liver parenchyma may be left without interruption for up to 40 minutes. Alternatively it is recommended to perform a complete vascular exclusion with occlusion of the inferior vena cava above and below the liver (10). When treating ruptures, deep stitches broadly covering the liver parenchyma are contraindicated, as they lead to its ischemization with frequent occurrence of infectious complications. The treatment of penetrating injuries consists of toilet and debridement of the wound in liver parenchyma, and leaving an open wound with sufficient external drainage.

Recently the spectrum of surgical procedures has also included the use of a radiofrequency ablation for the treatment of bleeding, particularly from the depth of the liver parenchyma, or in non-anatomical resection of the liver, in order to create a bloodless resection line in the liver parenchyma. For the treatment of superficial bleeding from the liver parenchyma it is possible to use argon coagulation, local haemostyptics, tissue glues, adhesives or an omentum tamponade. Every surgical procedure in the liver parenchyma should be finished with adequate drainage (11, 12, 13, 14).

In patients with stable circulation, but increasing clinical abdominal finding or increasing finding of free liquid in abdominal cavity in an ultrasonographic or CT picture, laparoscopy is advantageous for both, diagnostic and therapeutic purposes (blood suction, drainage, suture of superficial wounds in the liver) (15, 16).

It can be concluded that the success of liver injury treatment depends on multi-sector collaboration, which in turn lies in high quality pre-hospital care and concentration on the patients (particularly those with higher degree injuries) at trauma centers with a 24-hour diagnostic-therapeutic service, and particularly with experience in treating these serious injuries. Only by observing this procedure is it possible to achieve mortality that is lower than 10, as is the case of a number of large trauma centers, including our own university trauma center.

References

- MacKenzie S, Kortbeek JB, Mulloy R, Hameed SM.** Recent experiences with a multidisciplinary approach to complex hepatic trauma. *Injury* 2004; 35: 869-877.
- Vyhnanek F, Denemark L, Duchac V.** Basic diagnostic and therapeutic principles of liver injury. *Acta Chir Orthop Traumatol Czech* 2003; 70: 219-225.
- Poletti PA, Mirvis SE, Shanmuganathan K, Killeen KL, Coldwell D.** CT criteria for management of blunt liver trauma: correlation with angiographic and surgical findings. *Radiology* 2000; 216: 418–427.
- Gao JM, Du DY, Zhao XJ, Liu GL, Yang J, Zhao SH, Lin X.** Liver trauma: experience in 348 cases. *World J Surg* 2003; 27: 703–708.
- Simanek V, Skalicky T, Treska V, Klecka J, Mirka H, Ohlidalova K.** Liver injuries — case reports. *Urazova chirurgie* 2004; 12: 17–22.

Dominguez FE, Aufmkolk M, Schmidt U, Nimitz K. Outcome and management of blunt liver injuries in multiple trauma patients. *Langenbecks Arch Surg* 1999; 384: 53—460.

Pryor JP, Stafford PW, Nance ML. Severe blunt hepatic trauma in children. *J Pediatr Surg* 2001; 36: 974—979.

Vatanaprasan T. Operative treatment of hepatic trauma in Vachira Phuket Hospital. *J Med Assoc Thai* 2005; 88: 318—328.

Bashir MM, Abu-Zidan FM. Damage control surgery for abdominal trauma. *Europ J Surg Suppl* 2003; 588: 8—13.

Ott R, Schon MR, Seidel S, Schuster E, Josten C, Hauss J. Surgical management, prognostic factors, and outcome in hepatic trauma. *Unfallchirurg* 2005; 108: 127—134.

Fengjun L, Mtete KA, Xuting Z, Nanhai S. Complex therapy for hepatic trauma. *East Afr Med J* 2005; 82: 28—33.

Pilgrim CH, Usatoff V. Role of laparoscopy in blunt liver trauma. *ANZ Surg* 2006; 76: 403—406.

Labas P, Vrtik L, Huorka M. Trama pečene. *Acta Chirurgicae Orthopaedicae et Traumatologie Cechosl* 1996; 63 (2): 98—101.

Labas P, Vrtik L, Huorka M, Simo J, Lukac L. Chirurgicka technika taktika pri tupej traume pecene. *Slov Lekar* 1996; 6 (3): 24—27.

Gao JD, Zhao X, Lis G, Yang J, Zhao SH, Lin X. Severe hepatic trauma: surgical strategies. *Chin J Traumatol* 2002; 5: 346—351.

Gur S, Orsel A, Atahan K, Hokmez A, Tarcan E. Surgical treatment of liver trauma. *Hepatogastroenterology* 2003; 50: 2109—2111.

Received May 10, 2007.

Accepted December 3, 2007.