

EXPERIMENTAL STUDY

Cytokines and liver regeneration after partial portal vein ligation in porcine experimental model

Liska V¹, Treska V¹, Skalicky T¹, Mirka H², Kobr J³, Sykora R⁴, Sutnar A¹, Bruha J¹, Fiala O¹, Vycital O¹, Chlumska A⁵, Holubec L Jr⁶, Matejovic M⁴

Department of Surgery, Charles University, Medical School and Teaching Hospital Plzen, Czech Republic.

Vena.Liska@seznam.cz

Abstract: *The aim of study:* The limits of liver surgery are restricted today by the functional reserves of remnant parenchyma. The aim of this article was to acquaint the general surgical and medical public with the results of experimental liver regeneration stimulated by cytokines and thus to enhance their effort to carry on with implementing the research results in clinical practice.

Methods: Authors present their experimental model of liver regeneration after ligation of portal branches for caudate and right lateral, and right medial liver lobes. The regeneration was induced by application of TNF- α and IL-6 into the non-occluded portal branches, and compared with the results of other experimental teams.

Results and conclusion: The absolute volume of hypertrophic lobes increases after application of TNF- α more rapidly, whereas in the control group, practically no changes were recorded in hypertrophic liver lobes volumes in first three days. The achieved acceleration of growth of hypertrophic liver lobes after application of TNF- α and IL-6 confirmed the key role of studied pleiotropic cytokines in the priming of liver parenchyma regeneration after portal vein ligation (Fig. 3, Ref. 26). Full Text (Free, PDF) www.bmj.sk.

Key words: interleukin-6, tumor necrosis factor- α , liver surgery, portal vein embolization, portal vein ligation, liver regeneration, experimental study, porcine model.

Liver surgery achieved an admirable progress in the past twenty years especially because of the development of new technical procedures and owing to the introduction of modern intensive perioperative care. Nevertheless, a complete remission of malignant disease by means of radical surgical therapy is not indicated in many patients with primary or secondary liver malignancies. Non-surgical treatment of suspected acute liver failure is indicated should the liver resection be too extensive thus leaving the retained liver parenchyma too small to be able to supply the liver functions and regeneration. Portal vein embolization (PVE) can augment the future liver remnant volume (FLRV) even when only one of liver lobes is afflicted with ma-

lignant diseases. This procedure was performed for the first time in 1984 by Makuuchi (1, 2, 3). PVE of portal branch supplying the liver lobe afflicted with malignancy initiates compensatory hypertrophy of contralateral non-occluded lobe. The occluded lobe undergoes atrophy. The compensatory hypertrophy is supposed to be stimulated by the increased flow of portal blood that contains hepatotrophic substances (4, 5). Liver resection after PVE is performed only in 63–96 % of patients (6, 7, 8). The main

¹Department of Surgery, Charles University, Medical School and Teaching Hospital Plzen, ²Department of Radiology, Charles University, Medical School and Teaching Hospital Plzen, ³Department of Pediatrics, Charles University, Medical School and Teaching Hospital Plzen, ⁴First Department of Medicine, Charles University, Medical School and Teaching Hospital Plzen, ⁵Institut of Pathology, Charles University, Medical School and Teaching Hospital Plzen, and ⁶Section of Medical Statistics, Charles University, Medical School and Teaching Hospital Plzen, Czech Republic

Address for correspondence: V. Liska, MD, PhD, Dept of Surgery Charles University, Medical School and Teaching Hospital Plzen Alej svobody 80, CZ-304 00 Pilsen, Czech Republic
Phone: +420.377.104271, Fax: +420.377.103965

Acknowledgment: This article was supported by the grant IGA CR NR 8860/1-3 and Research project MSM 0021620819 (Replacement of any support to some vital organs).

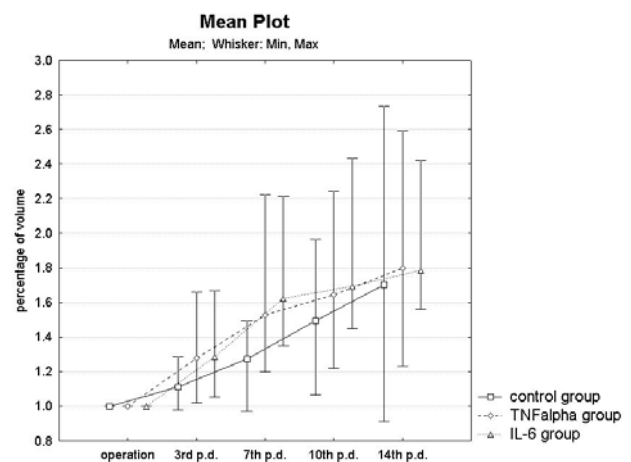
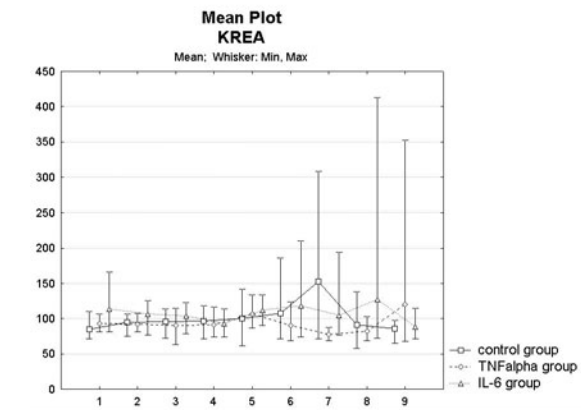
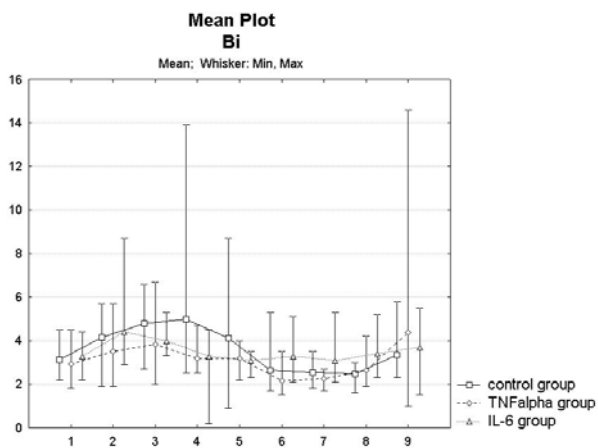
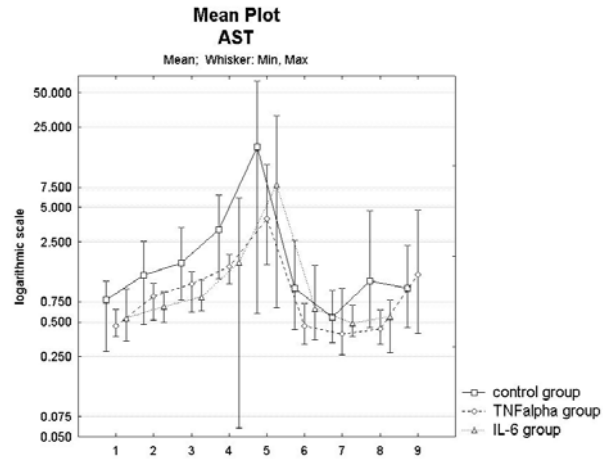
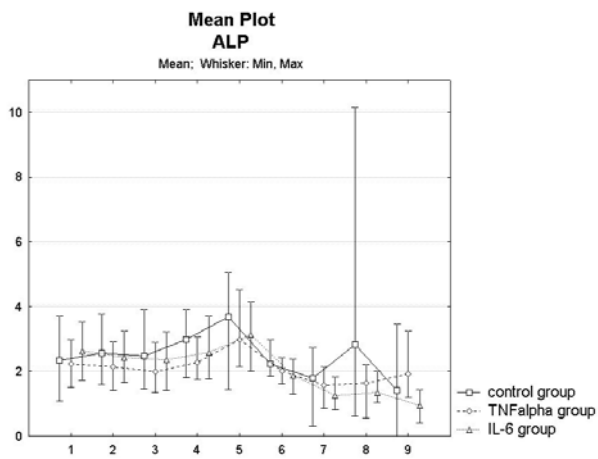
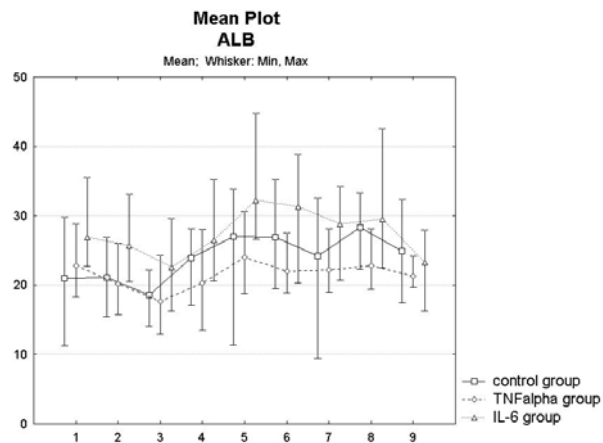
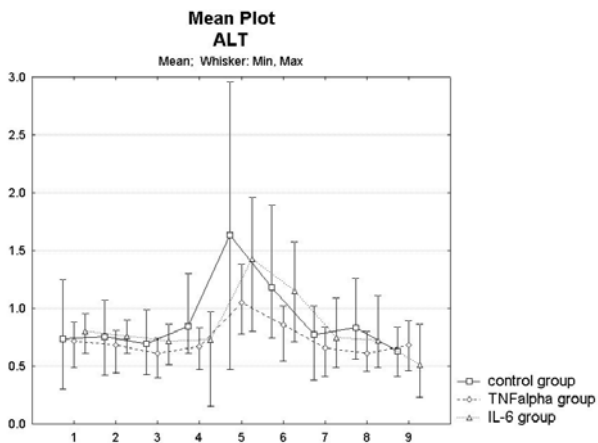


Fig. 1. The comparison of volume of hypertrophic liver lobes among the IL-6, TNF- α , and control groups (100 % volume=day 0).



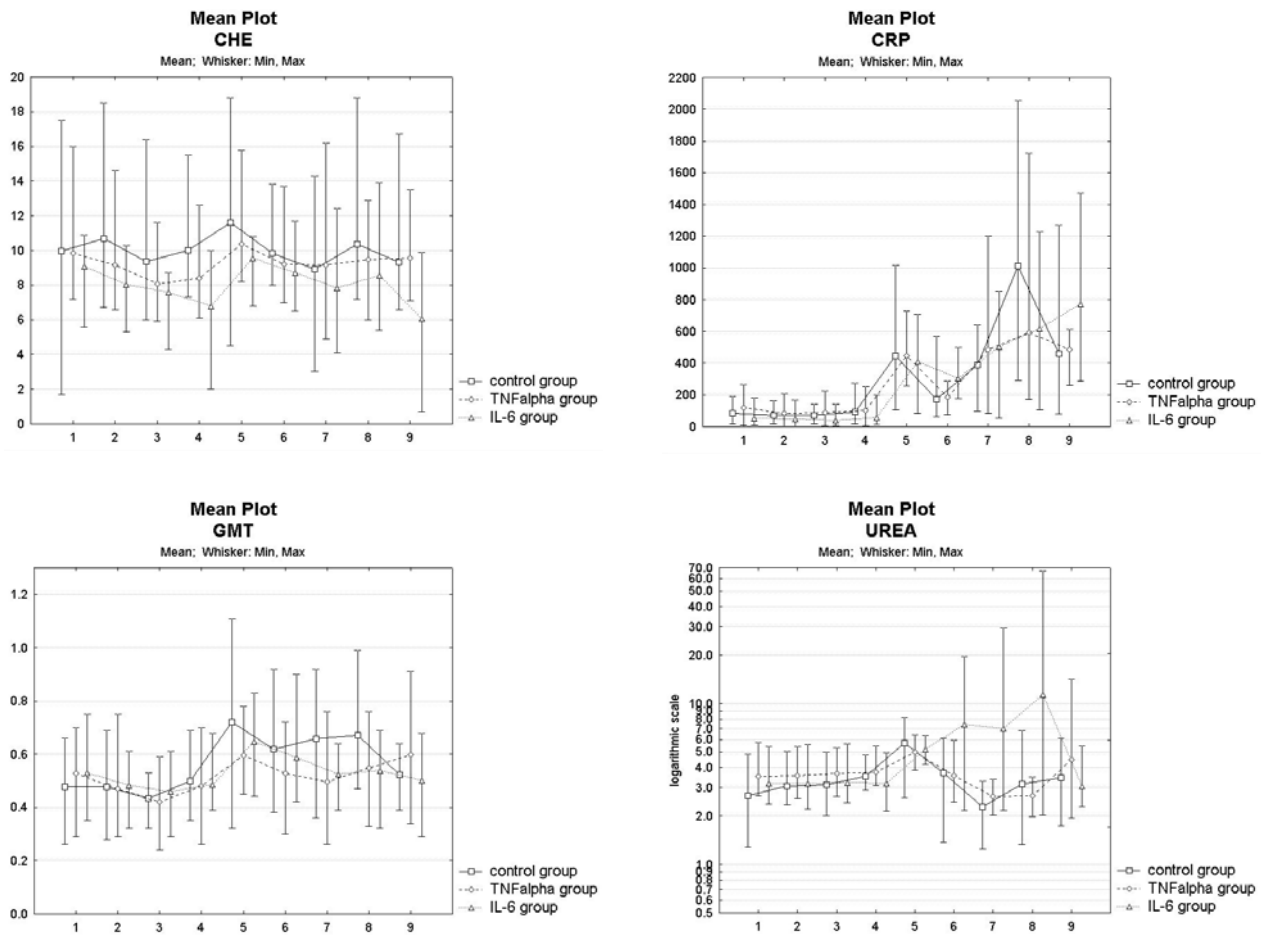


Fig. 2. The comparison of progression of particular biochemical parameters among the IL-6, TNF- α and control group: 1 – before operation, 2 – after ligation of the last portal branch, 3. -before application of cytokine, 4 – 2 hours after application of cytokine, 5 – 1th postoperative day (p.d.), 6 – 3rd p.d., 7 – 7th p.d., 8 – 10th p.d., and 9 – 14th p.d. Units of particular biochemical parameters: alanine aminotransferase (ALT) – $\mu\text{kat/l}$, albumin – g/l, alkaline phosphatase (ALP) – $\mu\text{kat/l}$, aspartylaminotransferase (AST) – $\mu\text{kat/l}$, bilirubin – $\mu\text{mol/l}$, creatinine – $\mu\text{mol/l}$, cholinesterase (CHE) – $\mu\text{kat/l}$, C-reactive protein (CRP) – mg/l, gamaglutamyltransferase (GGT) – $\mu\text{kat/l}$, and urea – mmol/l. The curves of progression of some of biochemical parameters is presented in logarithmic scale to accent the differences.

reason for this resolution is unsuccessful hypertrophy of FLRV or progression of malignancy.

Proper regeneration of liver parenchyma depends on proliferation of parenchymal and non-parenchymal liver cells. The importance of STEM cells or liver oval cells is still under discussion and this mechanism provokes many questions (9, 10, 11). After partial hepatectomy or portal vein ligation, serum level of tumour necrosis factor-alpha (TNF- α) and interleukin-6 (IL-6) increases, and they have been proven to be involved in the priming of hepatocytes and triggering them from G0 to G1 cell cycle phase (12). These cytokines induce the activation of genes that are responsible for G1 phase. Both pleiotrophic cytokines are secreted by non-parenchymal liver cells (mostly Kupffer cells) (13, 14). TNF- α is superior to IL-6, and stimulates an increase in secretion of IL-6. In hepatectomized regenerating liver, it is known that this signaling pathway follows the sequence TNF- α \rightarrow TNFR-1 \rightarrow NF- κ B

\rightarrow IL-6 \rightarrow STAT3 (15). The proliferation of primed hepatocytes is regulated positively by hepatocyte growth factor (HGF), epidermal growth factor (EGF), insulin-like growth factor (IGF), transforming growth factor-alpha (TGF- α), etc. The termination of proliferation and stimulation of differentiation of hepatocytes, final restructuring of liver tissue, and production of extracellular matrix is controlled by transforming growth factor-beta (TGF- β) (16, 17, 18). The replication of hepatocytes culminates on 7th day (14 per cent of hepatocytes), and the return to quiescent status was observed on 12th day after PVE in a swine experimental model (19, 20). The differences between PVE and PVL were not proved to be statistically significant in achieving FLRV (21).

The aim of this publication was to apprise the general surgical and medical public of the results of experimental liver regeneration stimulated by cytokines and thus to enhance their effort to carry on with implementing the research results in clinical

practice. The results can possibly be used in human liver surgery to enable the patients suffering from liver malignancy to undergo radical extensive liver resections.

Material and methods

The presented study compares the results acquired from two previous experiments, namely in stimulating liver regeneration after partial portal vein ligation by application of TNF- α (22) or IL-6 (23). We provide a short summary of methods in order to approximate the real experimental conditions, as well as to describe the experimental model. All described procedures were prepared and performed in compliance with the legislation of Czech Republic, which is comparable with the legislation of the European Union.

The portal vein branches for caudate, right lateral and right medial lobes (50–60 per cent of the supposed liver parenchyma) were prepared and ligated without any injury or ligation of hepatic artery branches. The recombinant porcine TNF- α in amount of 5 $\mu\text{g}/\text{kg}$ (rpTNF- α , ProSpec TechnoGene, Israel, 8 piglets from TNF- α group), the recombinant porcine IL-6 in amount of 0.5 $\mu\text{g}/\text{kg}$ (rpIL-6, ProSpec TechnoGene, Israel, 8 piglets from IL-6 group), or physiological solution (9 piglets from the control group) were applied into non-occluded portal vein branches (22, 23, 24). The blood samples were collected from central vein blood: 1) before the operation, 2) after the ligation of the last portal branch, 3) before cytokines application, 4) 2 hours after application of cytokines, 5) on 1st postoperative day (p.d.), 6) on 3rd p.d., 7) on 7th p.d., 8) on 10th p.d., and 9) on 14th p.d.

The biochemical parameters were assessed by means of biochemical analyser Olympus 2700 as follows: bilirubin, urea, creatinine, alkaline phosphatase (ALP), gamaglutamyltransferase (GGT), cholinesterase (CHE), aspartylaminotransferase (AST), alanine aminotransferase (ALT), and albumin.

Serum level of C-reactive protein (CRP), studied cytokines (TNF- α and IL-6), and growth factors (TGF- β 1, IGF) were measured through enzyme-linked immunosorbent assay (ELISA) by Auto-EIA II Analyzer (Lasystems Oy Helsinki, Finland). The immunoassay kits were produced by Biosource California (TGF- β 1, KAC1688/1689 and TNF- α , KSC3012/KSC3011), Immunodiagnostic Systems Britain (IGF, Octeia IGF-1) RD Systems Minnesota (IL-6, Quantikine), and Tridelata Development Ireland (CRP, Phase Range).

The ultrasonographic examinations were undertaken immediately after an operation and on 3rd, 7th, 10th, and 14th postoperative day (ultrasound machine Medison Sonoace 9900, convex probe with frequency 3.5 MHz). The diameters of atrophic and hypertrophic lobes were measured in B-modus in all three basic planes (axial, sagittal and coronary). The volume of lobes was counted by using standard ultrasonographic formula, which is also used in human medicine: $axial \times sagittal \times coronary / 2$.

The experiment was finished on 14th day when animals were sacrificed under general anaesthesia.

The histological material from atrophic and hypertrophic parenchyma was examined after being stained with hematoxylineosine, periodic acid-Schiff (PAS) staining, and PAS staining after

digestion of preparations with diastase. The proliferation activity was examined using antibody Ki67 (MIB 1 MW, 1:1000 DakoCytomation). We concentrated especially on the measurement of lobule length, binucleated hepatocyte, and length of hepatocytes.

Statistical analysis was performed by the software CRAN 2.4.0 and STATISTICA 98 Edition.

The measured parameters (biochemistry, immunoanalysis, ultrasonography, etc.) were described with basic statistical variables – mean, median, standard deviation, minimum, maximum, and quartile extent. The statistical data were processed graphically into Box and Whisker plot diagrams. The comparison of distribution of the parameters studied in particular groups was counted with the help of the distribution-free test (Wilcoxon). The Spearman Rank Correlation Coefficient was used because of non-Gaussian distribution of parameter values. The whole development of the parameters studied in time was compared between the groups by means of the parametric test ANOVA.

Results

The results of liver lobes• volume achieved by means of ultrasonography and physical examinations during necropsy were compatible on the 14th postoperative day. The absolute volume of hypertrophic lobes grew more rapidly after the application of IL-6 or TNF- α , whereas the control group had a slow start in growth of hypertrophic liver lobes in the first three days. The maximum acceleration of growth of hypertrophic liver lobes in the IL-6 and TNF- α groups took place on 7th p.d. when compared with the control group ($p < 0.05$), nevertheless, this stimulating effect was lost during the follow-up period. After 10th p.d., the regeneration decelerated in both experimental groups, and on 14th p.d., the average hypertrophic volume obtained through application of TNF- α or IL-6 was larger than in the control group, however, these results were not statistically significant owing to the dispersion of particular values. We did not prove any differences in the development of regeneration process in liver parenchyma between TNF- α and IL-6 groups (Fig. 1).

All studied serum biochemical parameters were comparable in both experimental groups, and the differences did not manifest any statistical significance between IL-6 and control groups at any point in time. On the contrary, some differences were recorded between TNF- α and control groups.

AST, ALT and GGT serum levels increased in the control group after operation more rapidly than in TNF- α group ($p < 0.05$). The serum levels of AST and ALT decreased and normalized during the first half of the follow-up, and we did not prove any differences between TNF- α group and control groups at the end of the experiment. The other studied biochemical serum parameters were compared in both experimental groups and the control group and the differences did not manifest any statistical significance, as was the case in both experimental groups (Fig. 2).

The serum level of TNF- α increased after the application (TNF- α group) but its serum level was practically normalized

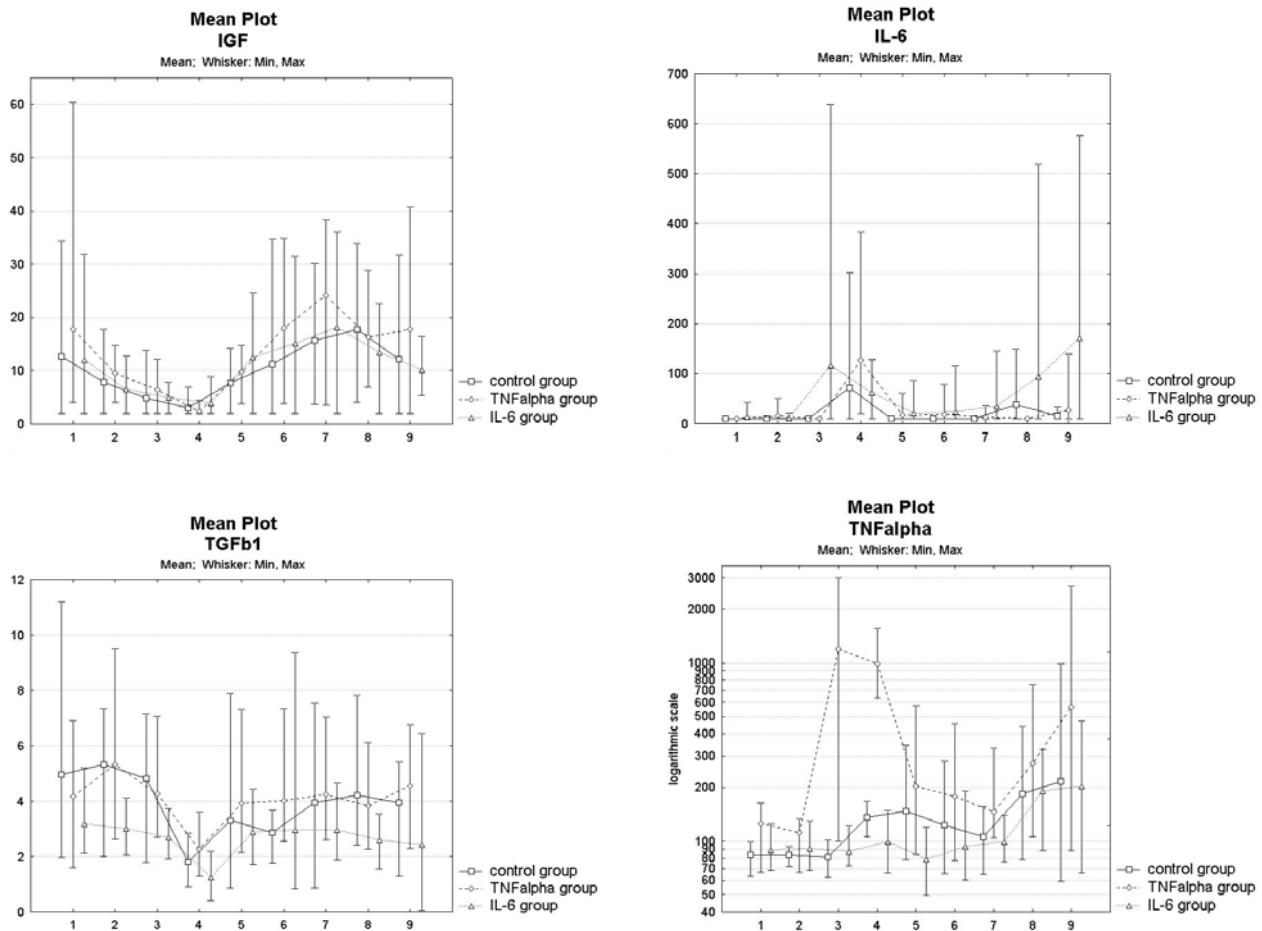


Fig. 3. The comparison of progression of particular cytokines and growth factors among the IL-6, TNF- α and control group: 1 – before operation, 2 – after ligation of the last portal branch, 3 – before application of cytokine, 4 – 2 hours after application of cytokine, 5 – 1th postoperative day (p.d.), 6 – 3rd p.d., 7 – 7th p.d., 8 – 10th p.d., and 9 – 14th p.d. Units of particular biochemical parameters: HGF – ng/l, IGF – μ g/l, IL-6 – ng/l, TGF β – μ g/l, TNF- α – ng/l.

on first p.d. ($p < 0.05$). The serum levels of all studied cytokines and growth factors expressed no statistically significant differences between IL-6 and TNF- α groups and the control group at any point in time. Besides, there were no statistically significant differences recorded between both experimental groups (Fig. 3).

The histological examination of biopsies was aggravated by time of collection of specimens, that were taken when the proliferation phase of liver regeneration had actually finished. The differences in lobule length were not statistically significant ($p = 0.08$) between TNF- α and control groups, but in TNF- α group, there were not only small or normal size lobules, but also many larger lobules, which were not present in the control group. The statistical analysis proved a significant increase in the amount of binucleated hepatocytes in hypertrophic liver lobes in IL-6 group compared to the control group. The statistical analyses of other histological parameters were not proved to be statistically significant. The proliferative activity in all groups greatly de-

creased, and when compared with normal liver samples from piglets without any surgical procedures, the mitotic figures were of the same quantity.

Discussion

Through this study, the authors are presenting a comparison of two experimental studies (21, 22) that used a newly established experimental model of portal vein embolization in big animal, which is physiologically very similar to human body. Contemporary literature describes portal vein ligation experimental model only in mice (25). The acceleration of growth of hypertrophic liver lobes after TNF- α or IL-6 application confirmed results gained in vitro models and in experiments on small laboratory animals (12, 16). Both studies illustrate a possibility of extrinsic cytokines application to increase the future liver remnant volume requested after portal vein ligation in selected concentrations (25, 26). We did not prove any statistically signifi-

cant difference between TNF- α and IL-6 groups as to liver regeneration and increase in volume of regenerating liver lobes.

The secondary effects, which could be hypothetically expected to appear after key pleiotropic cytokines application (changes in immune reactions and homeostasis) were not observed during either of the experiments.

We did not prove any statistically significant differences between serum levels of biochemical parameters studied between the control and IL-6 groups at particular points in time. On the contrary, the application of TNF- α prevented serum levels of AST, ALT, GGT, and creatinine from increasing in the postoperative period. All these biochemical parameters could result from both, operative stress and occlusion of portal branches of right liver lobes that represent significant liver function reserves. The postoperative elevation of these parameters could be hypothetically ascribed also to atrophic changes in occluded lobes. This reduction in the expected increase in serum level of the discussed biochemical parameters after the application of studied cytokine in non-occluded portal vein could present also one of its pleiotropic functions – hepatoprotection against changes after operative stress and reduction of functional parenchyma. The changes in serum levels of studied cytokines and growth factors were also not observed to be different between IL-6 or TNF- α groups and the control group at particular points in time. The differences in serum levels of studied biochemical parameters and cytokines and growth factors between IL-6 and TNF- α groups were not statistically significant.

The increased number of larger lobules in the hypertrophic parenchyma in TNF- α group in comparison with the control group, and the increased number of binucleated hepatocytes in the hypertrophic parenchyma in IL-6 group could be explained by incomplete liver regeneration. Since there were practically no mitotic figures, or their amount was the same as in normal liver parenchyma without any surgical procedures or toxic insult, we could hypothesize, that the first phase of liver regeneration was finished and the next phase of regeneration was proceeding, namely the remodeling phase and the phase, when the liver's microstructure is restored (17). The differences in histological parameters between IL-6 and TNF- α group were not statistically significant.

This presented experimental model of liver regeneration could be considered more compatible with human organism in comparison with other models of small animals. Performed portal vein ligation is also very similar to PVE (21, 22, 23). The results of these experiments could be useful for supporting liver regeneration during complicated liver procedures bringing about high risk of liver failure and future limit of liver remnant volume.

We could only hypothesize about the influence of studied cytokines in real clinical situation upon the growth of tumours or metastatic lesions. Because of their very short half-life and the fact, that they have to circulate through many microcirculations (liver, lungs) before they can enter again the occluded liver lobe via arterial supplementation, we suppose, that this influence would be of marginal meaning. Our hypothesis is supported by the fact, that the measured increase in serum levels of studied

cytokines after their application in central vein were detected only for short time. These speculations represent a trigger for further experimental and preclinical research projects. These questions have to be answered before our results can be clinically applied.

These results can serve as a basis for further medical studies of the initiation of hypertrophy after PVE in patients in whom we can assume a weak hypertrophic reaction after PVE. The application of IL-6 or TNF- α can hypothetically increase the liver remnant volume after PVE. The comparison of both studies did not give us any answer to the question as to which of both studied cytokines could be of greater benefit in human medicine. None of the cytokines proved to be more advantageous than the other. Therefore it is not possible to prefer one to the other. This issue remains to be an objective for further experimental or clinical research.

References

1. **Abdalla EK, Hicks ME, Vauthey JN.** Portal vein embolization: Rationale, technique and future prospects. *Brit J Surg* 2001; 88: 165–175.
2. **Makuuchi M, Thai BL, Takayasu K et al.** Preoperative portal embolization to increase safety of major hepatectomy for hilar bile duct carcinoma: A preliminary report. *Surgery* 1990; 107: 521–527.
3. **Makuuchi M, Takayasu K, Takayama T.** Preoperative transcatheter embolization of portal venous branch for patient receiving extended lobectomy due to the bile duct carcinoma. *J Jpn Soc Clin Surg* 1984; 45: 14–20.
4. **Farada H, Imamura H, Miyagawa S et al.** Fate of human liver after hemihepatic portal vein embolization: Cell kinetic and morphometric study. *Hepatology* 1997; 26: 1162–1170.
5. **Kusaka K, Imamura H, Tomata T et al.** Factors affecting regeneration after portal vein embolization. *Hepatogastroenterology* 2004; 51: 532–535.
6. **Azoulay D, Castaing D, Smail A et al.** Resection of non-resectable liver metastases from colorectal cancer after percutaneous portal vein embolization. *Ann Surg* 2000; 4: 480–486.
7. **Kokudo N, Tada K, Seki M et al.** Proliferative activity of intrahepatic colorectal metastases after preoperative hemihepatic portal vein embolization. *Hepatology* 2001; 34: 267–272.
8. **Stefano D, De Baere T, Denys A et al.** Preoperative percutaneous portal vein embolization: evaluation of adverse events in 188 patients. *Radiology* 2005; 234: 625–630.
9. **Lagasse E, Connors H, Al-Dhaliny M, Reitsma M, Dohse M, Osborne L, Wang X, Finegold M, Weissman IL, Grompe M.** Purified hematopoietic stem cells can differentiate into hepatocytes in vivo. *Nat Med* 2000; 6: 1229–1234.
10. **Petersen BE, Bowen WC, Patrene KD et al.** Bone marrow as a potential source of hepatic oval cells. *Science* 1999; 284: 1168–1170.
11. **Vassilopoulos G, Wang PR et al.** Transplanted bone marrow regenerates liver by cell fusion. *Nature* 2003; 422: 901–904.
12. **Cornell RP.** Acute phase responses after acute liver injury by partial hepatectomy in rats as indicators of cytokine release. *Hepatology* 1990; 11: 923–31.

13. **Fausto N, Riedle KJ.** Mechanisms of liver regeneration and their clinical implications. *J Hepatobiliary Pancreat Surg* 2005; 12: 181—189.
14. **Fausto N.** Liver regeneration. *Journal of Hepatology* 2000; 32 (Suppl 1): 19—31.
15. **Michalopoulos GK, DeFrances MC.** Liver regeneration. *Science* 1997; 276: 60—66.
16. **Fukuhara Y, Hirasawa A, Li XK et al.** Gene expression in the regenerating rat liver after partial hepatectomy. *J Hepatol* 2003; 38: 784—792.
17. **Mangnall D, Bird NC, Majeed AW.** The molecular physiology of liver regeneration following partial hepatectomy. *Liver international* 2003; 23: 124—138.
18. **Zimmermann A.** Regulation of liver regeneration. *Nephrol Dial Transplant* 2004; 19 (Suppl 4): iv6—iv10.
19. **Coelho MC, Tannuri U, Tannuti AC et al.** Expression of interleukin 6 and apoptosis-related genes in suckling and weaning rat model of hepatectomy and liver regeneration. *J Pediatr Surg* 2007; 45: 613—619.
20. **Duncan JR, Nicka ME, Cai SR et al.** Embolization of portal vein branches induces hepatocyte replication in swine: a potential step in gene therapy. *Radiology* 1999; 210: 467—477.
21. **Broering DC, Hillert C, Krupski G et al.** Portal vein embolization vs. portal vein ligation for induction of hypertrophy of the future liver remnant. *J Gastrointest Surg* 2002; 6: 905—913.
22. **Liska V, Treska V, Mirka H et al.** Tumour Necrosis Factor-Alpha Stimulates Liver Regeneration After Partial Portal Vein Ligation — Experimental Study on a Porcine Model. *Neoplasma*, in press.
23. **Liska V, Treska V, Mirka H et al.** Interleukin-6 Augments Activation of Liver Regeneration in Porcine Model of Partial Portal Vein Ligation. *Anticancer Res*, in press.
24. **Teoh N, Field J, Farrell G.** Interleukin-6 is a key mediator of the hepatoprotective and pro-proliferative effects of ischaemic preconditioning in mice. *J Hepatol* 2006; 45: 20—27.
25. **Heinrich S, Jochum W, Graf R et al.** Portal vein ligation and partial hepatectomy differentially influence growth of intrahepatic metastasis and liver regeneration in mice. *J Hepatol* 2006; 45: 35—42.
26. **Baier PK, Baumgartner U, Wolff-Vorbeck G et al.** Hepatocyte proliferation and apoptosis in rat liver after liver injury. *Hepato-Gastroenterology* 2006; 53: 747—752.

Received January 18, 2009.

Accepted May 5, 2009.